

Volume 51, Number 2, June 2018

p-ISSN: 1978-3728

e-ISSN: 2442-9740

Dental Journal

Published quarterly per year

Majalah Kedokteran Gigi



- Effects of silkworm fiber position on flexural and compressive properties of silk fiber-reinforced composites
- Effects of *Moringa oleifera* leaf extract combined with DFBBX on type-1 collagen expressed by osteoblasts in the tooth extraction sockets of *Cavia cobaya*
- Acid fast bacilli detected in the oral swab sample of a pulmonary tuberculosis patient

Accredited No. 32a/E/KPT/2017

Dental Journal

Majalah Kedokteran Gigi


Home About Login Register Search Current Archives Announcements Submission


Home > Archives > Vol 51, No 2 (2018)



VOL 51, NO 2 (2018)
(JUNE 2018)



Table of Contents


Articles



-  **Differences in mucin expression in the submandibular glands of rats during peridontitis induction** 52-56



 10.20473/j.djmk.v51.i2.p52-56


 Abstract views = 860 times |  views = 314 times



 *Nunuk Purwanti, Banun Kusumawardhani, Kwartarini Murdiastuti*
-  **Effects of silkworm fiber position on flexural and compressive properties of silk fiber-reinforced composites** 57-61



 10.20473/j.djmk.v51.i2.p57-61


 Abstract views = 444 times |  views = 245 times



 *Ariyani Faizah, Dendi Murdiyanto, Yulita Nur Widyawati, Narawidya Laksmi Dewi*
-  **Management of palatal perforation in systemic lupus erythematosus patient** 62-66



 10.20473/j.djmk.v51.i2.p62-66


 Abstract views = 370 times |  views = 255 times



 *Dwi Setianingtyas, Paulus Budi Teguh, W Widyastuti, Neken Prasetyaningtyas, Ramadhan Hardani Putra, Felicia Eda Haryanto*
-  **Mauli banana stem extract application increased expression of NF-κB in traumatic ulcer healing** 67-70



 10.20473/j.djmk.v51.i2.p67-70


 Abstract views = 426 times |  views = 261 times



 *Maharani Laillyza Apriasari, Retno Pudji Rahayu, Diah Savitri Ernawati*
-  **Behavior management-based applied behaviour analysis within dental examination of children with autism spectrum disorder** 71-75



 10.20473/j.djmk.v51.i2.p71-75


 Abstract views = 878 times |  views = 351 times



 *Taufiq Hidayatullah, Hendriati Agustiani, Arlette Suzy Setiawan*
-  **Management of chronic traumatic ulcer mimicking oral squamous cell carcinoma on the tongue** 76-80



 10.20473/j.djmk.v51.i2.p76-80


 Abstract views = 559 times |  views = 321 times



 *Revi Nelonda, Riani Setiadhi*
-  **Mandibular morphology of the Mongoloid race in Medan according to age groups** 81-85



 10.20473/j.djmk.v51.i2.p81-85


 Abstract views = 470 times |  views = 192 times



 *Maria Sitanggang, Trelia Boel*
-  **Effects of Moringa oleifera leaf extract combined with DFBBX on type-1 collagen expressed by osteoblasts in the tooth extraction sockets of Cavia cobaya** 86-90



 10.20473/j.djmk.v51.i2.p86-90


 Abstract views = 408 times |  views = 217 times

 *S. Soekobagiono, Sherman Salim, Hanoem Eka Hidayati, Karina Mundiratri*
-  **Acid fast bacilli detected in the oral swab sample of a pulmonary tuberculosis patient** 91-94

 10.20473/j.djmk.v51.i2.p91-94

 Abstract views = 525 times |  views = 211 times

 *Reiska Kumala Bakti, Ni Made Mertaniasih, Diah Savitri Ernawati, Bagus Soebadi, Priyo Hadi*
-  **Differences in photodynamic therapy exposure time and Staphylococcus aureus counts** 95-98

 10.20473/j.djmk.v51.i2.p95-98

 Abstract views = 380 times | views = 176 times

 Adeline Jovita Tambayong, Ira Widjiastuti, Cecilia G. J. Lunardi
- **Changes in the number of macrophage and lymphocyte cells in chronic periodontitis due to dental X-ray exposure** 99-103

 10.20473/j.djmk.v51.i2.p99-103

 Abstract views = 510 times | views = 203 times

 Alhidayati Asymal, Eha Renwi Astuti, Rini Devijanti

Editorial

- Front-matter 

 10.20473/j.djmk.v51.i2.p99-103

Policies

- Author Guidelines
- Focus and Scope
- Peer Review Process
- Publication Frequency
- Open Access Policy
- Publication Ethics
- Article Processing Charge
- Plagiarism Screening

People

- Editorial Team
- Peer-Reviewers
- Contact

User

Username

Password

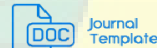Remember me

Journal Standing

Scopus

Google Scholar

Citation indices	All	Since 2014
Citations	1548	1211
h-index	15	13
i10-index	30	22



Journal Content

Search

Search Scope

- Browse
- By Issue
 - By Author
 - By Title
 - Other Journals

Notifications

- View
- Subscribe

Differences in mucin expression in the submandibular glands of rats during periodontitis induction

Nunuk Purwanti,¹ Banun Kusumawardhani,² and Kwartarini Murdiastuti³

¹Department of Biomedical Dental Science, Faculty of Dentistry, Universitas Gadjah Mada, Yogyakarta - Indonesia

²Department of Biomedical Sciences, Faculty of Dentistry, Universitas Jember, Jember - Indonesia

³Department of Periodontology, Faculty of Dentistry, Universitas Gadjah Mada, Yogyakarta - Indonesia

ABSTRACT

Background: *Porphyromonas gingivalis* (Pg) produces lipopolysaccharide (LPS) which acts as a stimulator of inflammation in periodontal tissues. Periodontitis-induced apoptosis and vacuolation of the salivary gland, therefore, causes hyposalivation. Mucin secretion is produced by the submandibular gland under stimulation by the cholinergic and adrenergic receptors. Both forms of stimulation influence the volume of mucin secretion. Mucin saliva plays an important role in the early stages of Pg colonization in the oral cavity. On the other hand, it serves to protect against bacterial invasion. **Purpose:** The aim of this research was to identify differences in mucin expression in the submandibular gland during periodontitis induction. **Methods:** 32 male Wistar rats were assigned to either a sham periodontitis or a periodontitis group. The former group received a daily injection of a vehicle solution (n = 16), while members of the periodontitis induction group (n=16) were injected each day with 500 µL of Pg 108 into the mesial area of the upper molar. Mucin in the submandibular gland was analyzed at the 7th, 14th, 21th and 28th days after injection by means of periodic acid schiff (PAS) staining. **Results:** 28 days after injection mild gingivitis was developed in the periodontitis experiment group. Junctional epithelium (JE) thickness decreased gradually following the increase of PG injection periods (p<0.05). However, mucin expression increased prominently at 7th, 14th, and 21th days after injection and decreased on day 28th after PG injection. Mucin was expressed in the duct cells of the submandibular gland. **Conclusion:** The result of this study suggests that there are different levels of mucin expression in the submandibular gland during periodontitis induction.

Keywords: mucin; submandibular gland; periodontitis; *Porphyromonas gingivalis* (Pg)

Correspondence: Nunuk Purwanti, Department of Biomedical Dental Science, Faculty of Dentistry, Universitas Gadjah Mada. Jl. Denta I, Sekip Utara Yogyakarta 55281, Indonesia. E-mail: n_purwanti@mail.ugm.ac.id

INTRODUCTION

Periodontal disease has been renewed to cause inflammation in the gingiva, followed by connective tissue damage, alveolar bone resorption and systemic disease, including: atherosclerosis, rheumatoid arthritis, preterm-low birth weight, chronic kidney disease, diabetes and respiratory problems.¹⁻⁵ One of the bacteria causing periodontitis is *Porphyromonas gingivalis* (Pg), an anaerobic Gram negative oral bacteria that induces inflammation in periodontal tissue.^{2,3} Pg fimbria activates the innate and adaptive human immune system to induce monocytes and poorly activated epithelial cells to produce interleukin IL-6, IL-8, macrophage colony stimulating

factor (M-CSF) and tumor necrosis factor (TNF).^{6,7} This Pg virulence factor in periodontal areas will spread throughout the human body as one etiology of systemic disease. Saliva plays an important role in the early-entry stages of Pg bacteria in the oral cavity. Furthermore, it helps the attachment and initiation of Pg bacterial colonies on tooth surfaces and soft oral tissues. In the latest stages of infection, Pg bacteria begins to form biofilm binding to other bacteria through saliva mediation.⁸

Saliva performs multiple functions including: antibacterial, antimicrobial, antifungal, antiviral, immunity, clearance, wound healing and tissue repair⁹ due to its significant protein, carbohydrate and mineral content. Saliva components have been used widely as a biomarkers

of systemic disease.^{10,11} Mucin, as one component of saliva, is produced in large quantities in the submandibular gland. 20 types of mucin have been identified, five of them found in saliva, namely: MUC5B, MUC7, MUC1, MUC4, and MUC16.^{11,12} Mucin forms a slimy, viscoelastic film which coats all surfaces of the oral cavity. This layer acts as an important lubricant of opposing surfaces during mastication, swallowing and speech.⁹ The secreted salivary mucins, MUC5B and MUC7 modulate oral microorganisms.¹³ Mucin enables bacteria to adhere to oral surfaces.^{11,14} Other research shows that adolescents presenting a very high incidence of dental caries disease had increased levels of MUC1 and MUC5B, but decreased MUC7 protein levels.¹³

Saliva secretion is dynamic and susceptible to the effects of aging, systemic disease, medicine intake and radiotherapy treatment of the head and neck. Rat models have been used in cases of experimental periodontitis in order to analyze changes in saliva secretion. These have produced similar results to those observed in humans.¹⁵ However, changes in the mucin production of the salivary glands during the periodontitis process have not been well-documented in the literature on the subject. Previous studies have demonstrated that proinflammatory IL-1, IL-6 TNF- α , IFN- δ and *Pg* infection increase MUC1 genes in human oral epithelial cells. However, no effect was observed after *Pg* LPS treatment.¹⁶ On the other hand, incubation of acinar cells in the sublingual gland with LPS from *Pg* was shown to produce a decrease in salivary mucin synthesis.¹⁷ The purpose of this study was to determine differences in mucin expression in the submandibular gland during periodontitis induction. Mucin was used as a parameter considering its important role as one of the protective components of saliva. The results of this study will be used to develop mucin saliva as a biomarker of diagnostic and control tools in periodontitis therapy.

MATERIALS AND METHODS

The experimental protocol of this study was approved by the Research Ethics Committee, Faculty of Dentistry, Universitas Gadjah Mada (No.00377/KKEP/FGK-UGM/

EC/2015). 32 male, 8-week old Sprague Dawley rats with an average body weight of 150-200gms were involved. Housed in standard conditions with ad libitum access to food and water, the subjects were randomly divided into two main groups, those receiving periodontitis induction and others subjected to sham induction. Periodontitis induction was performed by means of a slightly modified Kusumawardhani procedure.¹⁸ Periodontitis induction groups received a daily 500 μ L injection of *Pg* 10⁸ in the mesial area of the upper first molar, while the sham periodontitis group received a daily injection of a placebo solution. The periodontitis and sham periodontitis groups were subsequently divided into subgroups according to the duration of the injection period, i.e., 7, 14, 21 and 28 days. Each group consisted of four models. During the injection period, the severity of experimentally induced periodontitis was monitored using a periodontal probe to ascertain the extent of pocket periodontal manifestation.¹⁹

The subjects were sacrificed one day after the last induction during their injection period by means of an overdose of intramuscular anesthesia. Their maxillary and submandibular glands were removed and separated from muscle and soft tissue for the histological process. The submandibular gland and maxillary area were immersed in 10% buffer formalin for 24 hours. Mandibles were incubated in 10% formic acid solution to promote decalcification and subsequently embedded in paraffin. They were then subjected to hematoxylin eosin (HE) staining, while the submandibular glands were processed for periodic acid shift (PAS) staining.^{20,21} All tissues were examined in three areas under a light microscope. Periodontal nuclei cell were stained blue by hematoxylin, whereas eosin stains cytoplasm and extracellular matrix varying degrees of pink. The thickness of JE was measured by counting the number of epithel layers from the cemento–enamel junction (CEJ) to the most coronal and apical sections of JE.²² The PAS positive gland staining produced a magenta-purple colour in the duct cell. The mucin level was measured based on the density of the mucin cell expression in the submandibular gland. Since there is no standard cellular density calculation for mucin expression cells, the standard based on the results of the research reported here was arranged and presented in Figure 1.

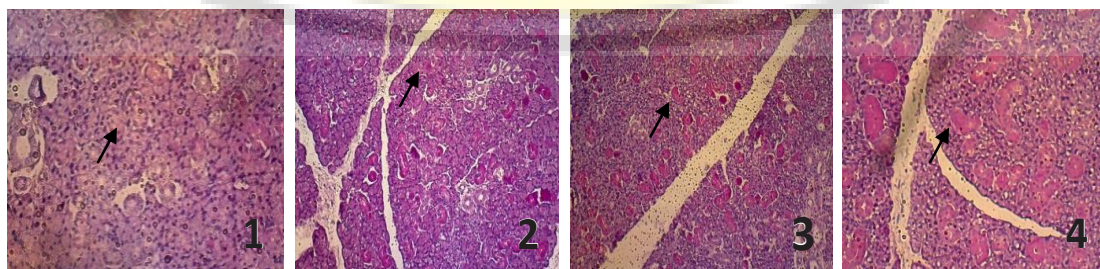


Figure 1. Mucin expression-cell density standard, 1=less than 25% of cells express mucin; 2 = 25%-50% of cells express mucin; 3 = 50%-75% cell expressed mucin; 4 = more than 75% of cells express mucin. Magenta color indicates the presence of mucin (black arrowhead).

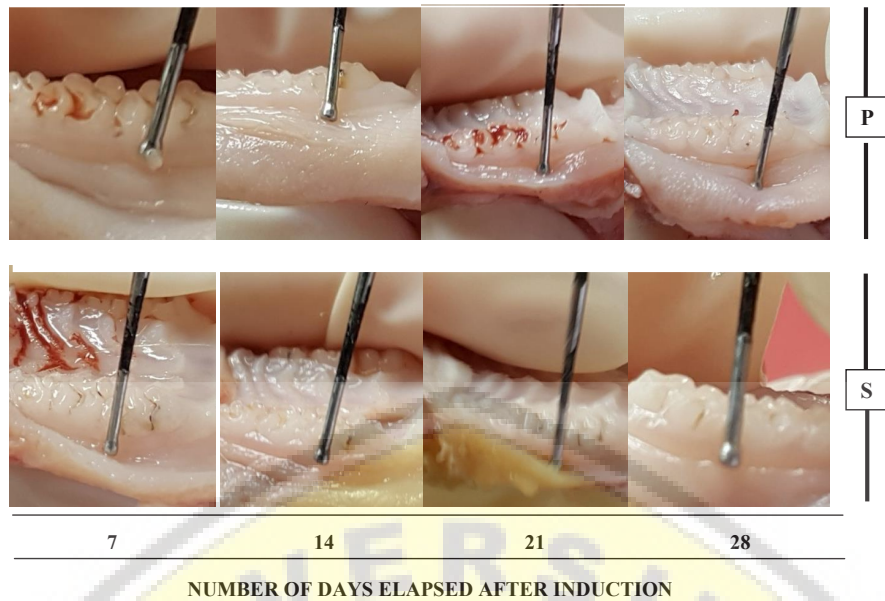


Figure 2. Periodontal pocket manifestation was examined in the molar region by means of a periodontal probe. Increasing probe depth occurred after 28 days of induction in contrast to days 21, 14, and 7. P: Periodontitis induction, S: sham induction.

While periodontitis was confirmed by examining the thickness of the mesio buccal JE of the upper molar,²³ a *Kruskal Wallis* test was used to analyze differences between the four groups followed by a Mann Whitney test. The statistical significance level was set at $p < 0.05$.

RESULTS

Gingival inflammation was detected in the periodontitis induction group due to the increased probing depth on

day 28 of treatment which had not occurred in the other groups (Figure 2). JE conversion to pocket epithelium is regarded as a hallmark in the development of gingivitis into periodontitis. Therefore, to confirm whether periodontitis induction was associated with inflammation in the periodontal tissues in this research, the thickness of the JE molar was examined by means of HE staining.²³ The results are contained in Figures 3 and 4.

As shown in Figures 3 and 4, the number of JE layers decreased in parallel with the number of days of

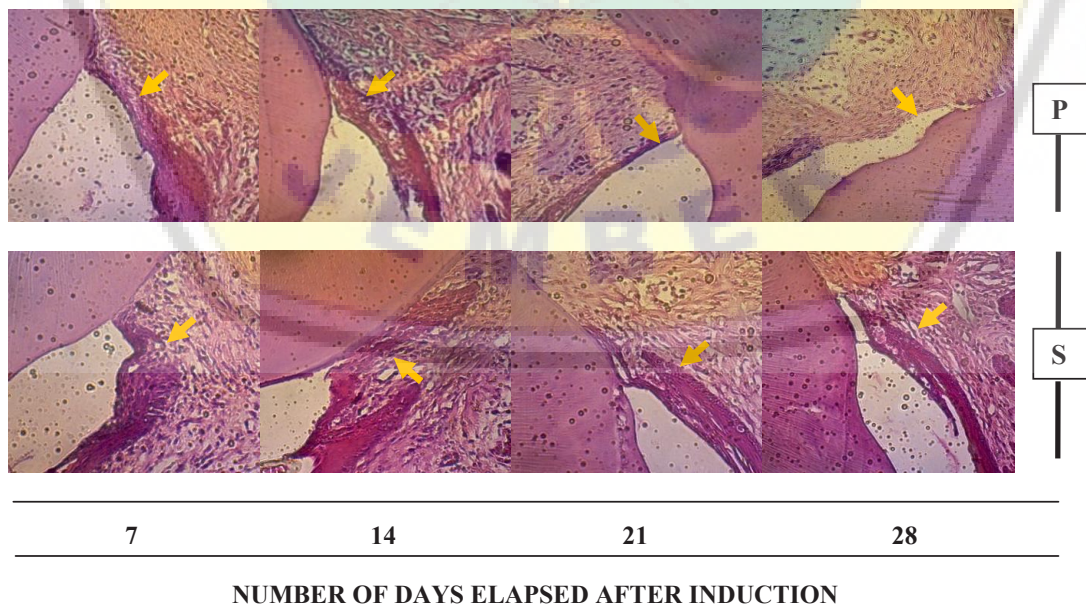


Figure 3. Changes in JE thickness after periodontitis induction (P). Data compared to sham (S) periodontitis induction on the same days (day 7, day 14, day 21 and day 28). The yellow arrowhead (↗) indicated JE. Picture was taken at 200x magnification.

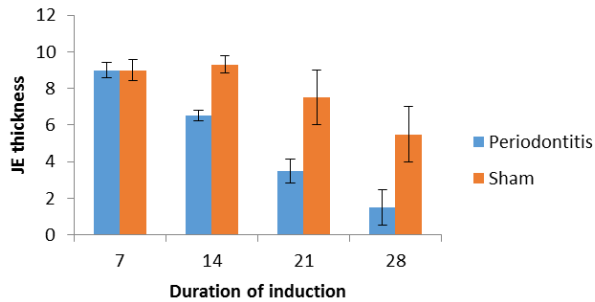


Figure 4. Thickness of JE molar teeth during periods of treatment.

periodontitis induction. Reduction in JE thickness began to occur on day 14 in the periodontitis induction groups. This JE thinning continued on days 21 and 28. The lowest thickness of JE was occurred in the periodontitis induction after 28 days. While the thickest was observed in the sham group on day 14.

Mucin saliva was detected by the presence of a magenta coloring in the cytoplasm of the duct cells. As seen in Figure 5, cell density which expressed mucin tended to increase up to days 21, but then decreased on day 28. The highest density was seen in rat periodontitis on day 21. The density of cells expressing mucin was analyzed statistically using a Kruskal Wallis test whose results indicated significant difference ($p=0.0001$). Subsequent statistical analysis was performed by means of a Mann Whitney test to investigate differences in cell expressing mucin density in the periodontitis and sham groups of the same duration. The results showed there to be significant difference between the periodontitis and sham periodontitis groups on day 7 ($p=0.008$), day 14 ($p=0.013$), day 21 ($p=0.008$) and day 28 ($p=0.004$).

DISCUSSION

According to the results of this study, injections of Pg decreased JE thickness. Depletion of the epithelial layer which facilitates the penetration of bacterial products into the deeper periodontal tissue was found on day 14. Previous studies have shown that a third LPS application induced the destruction of JE²² which was composed of an epithelium layer with no keratin in the cell surface.²⁴ This condition causes a decrease in the microscopic defensive system against injury. A previous study reported that proteinase from PG reduces epithelial cell adhesion to extracellular matrices, morphology changes and apoptosis.²⁴ High expression of TUNEL and M30CytoDeath as apoptosis markers results in the reduction of oral epithelial thickness.²⁵ This study found that JE thinning continued on days 21 and 28 and was confirmed by histology analysis that the method of injection of Pg induced periodontitis,

Salivary glands will respond to oral inflammation by increasing the molecular synthesis of acinar cells to

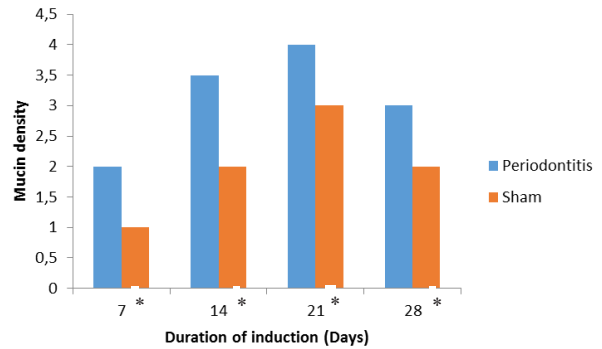


Figure 5. Mucin expression-cell density of submandibular gland on specific days of periodontitis induction. Data is presented as the median, * $p<0.05$; significantly different in both groups on the same day.

improve salivary protection function. Mucin is one source of molecular protection in saliva which is produced in large quantities in the submandibular gland. It has been established that LPS Pg influences mucin salivary secretion in the sublingual gland cells of rats.¹⁷ It can be seen from this study that PAS is strongly expressed in the duct cell, but very weakly in acinar cells. A previous study reported that mucin is expressed in the acinar duct and excretory duct cells.²⁶ The weakness of mucin expression in acinar cells is probably due to the continuing presence of mucin in the form of secretory granules which cannot be detected by means of PAS staining.²⁷

Saliva in patients suffering from chronic and aggressive periodontitis showed an increase in mucin and salivary amylase concentration.²⁸ As a part of secretory salivary protein, mucin is produced by the acinar cells under the control of the autonomic nervous system, while secretion of MUC5B is controlled by the parasympathetic nerve.²⁹ It has been reported that the submandibular gland produces mucin regulated by adrenergic and cholinergic signaling.³⁰ Changes in diseases and the environment regulate sympathetic nervous system responses. This pathway may be involved in systemic responses included modulation pain responses and inflammation.³¹ This study showed that mucin expression tends to increase with the duration of treatment involving injections. It has been firmly established that during the initial stages of bacterial infection, goblet and epithelial cells produce more mucin to prevent bacteria colonization. On the other hand, mucin facilitates bacteria adherence in the epithelia, showing that pathogenic bacteria compete with the protective function of mucin.^{12,27} An increased mucin expression between days 7 and 21 would produce a double function of mucin. An increase in mucin production in saliva has been reported in oral disease.^{13,28}

It has been established that the mucin submandibular gland is produced by the cholinergic and adrenergic system. LPS Pg induces inflammation through several mechanisms. LPS binds TLR receptor to induce secretion inflammatory cytokine, NOS and COX2. Evoked NOS

induces cholinergic system.³² The cholinergic system increases calcium concentration in the acinar cells of the submandibular glands. Furthermore, calcium evokes mucin secretion.³⁰ On the other hand, LPS Pg generates cytosolic phospholipase A₂ (cPLA₂) through up-regulation in the MAPK/ERK signaling pathway in the sublingual gland cell of rats resulting in cPLA₂ activated endothelin-1 mucin secretion.¹⁷ A decrease in mucin expression occurred on day 28 when periodontitis conditions were more severe than on day 21, possibly due to different signaling pathways being involved on each occasion. Further research is required to confirm which signaling pathways are involved in mucin secretion in the submandibular gland. It can be concluded from this study that mucin expression in the submandibular glands of rats differed during periodontitis induction. The expression of mucin increased gradually following the day of periodontitis induction with the highest level occurring on day 21 and decreasing on day 28.

ACKNOWLEDGEMENTS

This research was funded by Dana Masyarakat 2015 of the Faculty of Dentistry, Universitas Gadjah Mada.

REFERENCES

1. Yu KM, Inoue Y, Umeda M, Terasaki H, Chen ZY, Iwai T. The periodontal anaerobe *Porphyromonas gingivalis* induced platelet activation and increased aggregation in whole blood by rat model. *Thromb Res*. 2011; 127(5): 418–25.
2. Kim D, Lee G, Huh YH, Lee SY, Park KH, Kim S, Kim J, Koh J, Ryu J. NAMPT is an essential regulator of RA-mediated periodontal inflammation. *J Dent Res*. 2017; 96(6): 703–11.
3. Puertas A, Magan-Fernandez A, Blanc V, Revelles L, O'Valle F, Pozo E, León R, Mesa F. Association of periodontitis with preterm birth and low birth weight: a comprehensive review. *J Matern Neonatal Med*. 2018; 31(5): 597–602.
4. Han SS, Shin N, Lee SM, Lee H, Kim DK, Kim YS. Correlation between periodontitis and chronic kidney disease in Korean adults. *Kidney Res Clin Pract*. 2013; 32(4): 164–70.
5. Otomo-Corgel J, Pucher JJ, Rethman MP, Reynolds MA. State of the science: chronic periodontitis and systemic health. *J Evid Based Dent Pract*. 2012; 12(3 SUPPL.): 20–8.
6. Mysak J, Podzimek S, Sommerova P, Lyuya-Mi Y, Bartova J, Janatova T, Prochazkova J, Duskova J. *Porphyromonas gingivalis*: major periodontopathic pathogen overview. *J Immunol Res*. 2014; 2014: 1–8.
7. Liu J, Tang X, Li C, Pan C, Li Q, Geng F, Pan Y. *Porphyromonas gingivalis* promotes the cell cycle and inflammatory cytokine production in periodontal ligament fibroblasts. *Arch Oral Biol*. 2015; 60(8): 1153–61.
8. Enersen M, Nakano K, Amano A. *Porphyromonas gingivalis* fimbriae. *J Oral Microbiol*. 2013; 5: 1–10.
9. Dawes C, Pedersen AML, Villa A, Ekström J, Proctor GB, Vissink A, Aframian D, McGowan R, Aliko A, Narayana N, Sia YW, Joshi RK, Jensen SB, Kerr AR, Wolff A. The functions of human saliva: a review sponsored by the world workshop on oral medicine VI. *Arch Oral Biol*. 2015; 60(6): 863–74.
10. Kawas S AI, Rahim ZHA, Ferguson DB. Potential uses of human salivary protein and peptide analysis in the diagnosis of disease. *Arch Oral Biol*. 2012; 57: 1–9.
11. Frenkel ES, Ribbeck K. Salivary mucins in host defense and disease prevention. *J Oral Microbiol*. 2015; 7: 1–9.
12. Hannig C, Hannig M, Kensche A, Carpenter G. The mucosal pellicle – an underestimated factor in oral physiology. *Arch Oral Biol*. 2017; 80: 144–52.
13. Gabryel-Porowska H, Gornowicz A, Bielawska A, Wójcicka A, Maciorkowska E, Grabowska SZ, Bielawski K. Mucin levels in saliva of adolescents with dental caries. *Med Sci Monit*. 2014; 20: 72–7.
14. Corfield AP. Mucins: a biologically relevant glycan barrier in mucosal protection. *Biochim Biophys Acta*. 2015; 1850: 236–52.
15. Nakamura-Kiyama M, Ono K, Masuda W, Hitomi S, Matsuo K, Usui M, Nakashima K, Yokota M, Inenaga K. Changes of salivary functions in experimental periodontitis model rats. *Arch Oral Biol*. 2014; 59(2): 125–32.
16. Li X, Wang L, Nunes DP, Troxler RF, Offner GD. Pro-inflammatory cytokines expression in oral epithelial cells. *J Dent Res*. 2003; 82(11): 883–7.
17. Slomiany BL, Slomiany A. *Porphyromonas gingivalis* lipopolysaccharide-induced cytosolic phospholipase A₂ activation interferes with salivary mucin synthesis via platelet activating factor generation. *Inflammopharmacology*. 2006; 14(3–4): 144–9.
18. Kusumawardani B, Soesatyo MH, Dasuki D, Asmara W. Maternal endotoxin-induced fetal growth restriction in rats: Fetal responses in toll-like receptor. *Dent J (Maj Ked Gigi)*. 2012; 45(3): 144.
19. Huang S, Lu F, Zhang Z, Yang X, Chen Y. The role of psychologic stress-induced hypoxia-inducible factor-1 α in rat experimental periodontitis. *J Periodontol*. 2011; 82(6): 934–41.
20. Cao X, Liu X, Hao Z, Ma C, Mao Z. Establishment of rat submandibular gland squamous cell carcinoma induced by DMBA. *Hua xi kou qiang yi xue za zhi =*. 2000; 18(3): 156–8.
21. Nonose R, Spadari APP, Priolli DG, Máximo FR, Pereira JA, Martinez CAR. Tissue quantification of neutral and acid mucins in the mucosa of the colon with and without fecal stream in rats. *Acta Cir Bras*. 2009; 24(4): 267–75.
22. Noguchi S, Ukai T, Kuramoto A, Yoshinaga Y, Nakamura H, Takamori Y, Yamashita Y, Hara Y. The histopathological comparison on the destruction of the periodontal tissue between normal junctional epithelium and long junctional epithelium. *J Periodontol Res*. 2017; 52: 74–82.
23. Mohamed A. The effect of diabetes mellitus on the thickness of gingival junctional epithelium. Thesis. Yogyakarta: Universitas Gadjah Mada; 2011. p. 1-72.
24. Bosshardt DD, Lang NP. The junctional epithelium: from health to disease. *J Dent Res*. 2005; 84: 9–20.
25. Brant JMC, Vasconcelos AC, Rodrigues L V. Role of apoptosis in erosive and reticular oral lichen planus exhibiting variable epithelial thickness. *Braz Dent J*. 2008; 19(3): 179–85.
26. Lombaert IMA, Brunsting JF, Weirenga PK, Faber H, Stokman MA, Kok T, Visser WH, Kampinga HH, de Haan G, Coppes RP. Rescue of salivary gland function after stem cell transplantation in irradiated glands. *PLoS One*. 2008; 3(4): 1–13.
27. Dhanisha SS, Guruvayoorappan C, Drishya S, Abeesh P. Mucins: structural diversity, biosynthesis, its role in pathogenesis and as possible therapeutic targets. *Crit Rev Oncol Hematol*. 2018; 122: 98–122.
28. Acquier AB, Busch L, Pita AKDC, Sanchez GA. Comparison of salivary levels of mucin and amylase and their relation with clinical parameters obtained from patients with aggressive and chronic periodontal disease. *J Appl Oral Sci*. 2015; 23(3): 288–94.
29. Proctor GB, Carpenter GH. Regulation of salivary gland function by autonomic nerves. *Auton Neurosci Basic Clin*. 2007; 133: 3–18.
30. Busch L, Borda E. Signaling pathways involved in pilocarpine-induced mucin secretion in rat submandibular glands. *Life Sci*. 2007; 80(9): 842–51.
31. Morris KE, St. Laurent CD, Hoeve RS, Forsythe P, Suresh MR, Mathison RD, Befus AD. Autonomic nervous system regulates secretion of anti-inflammatory prohormone SMR1 from rat salivary glands. *Am J Physiol Cell Physiol*. 2008; 296(3): C514–24.
32. Correia PN, Carpenter GH, Paterson KL, Proctor GB. Inducible nitric oxide synthase increases secretion from inflamed salivary glands. *Rheumatology*. 2010; 49: 48–56.