

PAPER • OPEN ACCESS

Study report: association between pure tone average and ossicular status in chronic suppurative otitis media

To cite this article: N Shinta *et al* 2018 *J. Phys.: Conf. Ser.* **1075** 012062

View the [article online](#) for updates and enhancements.



IOP | ebooks™

Bringing you innovative digital publishing with leading voices to create your essential collection of books in STEM research.

Start exploring the collection - download the first chapter of every title for free.

Study report: association between pure tone average and ossicular status in chronic suppurative otitis media

N Shinta¹, N Purnami¹ and T H Ahadiah¹

¹Department of Otorhinolaryngology Head and Neck Surgery
Medical Faculty Airlangga University – Dr. Soetomo Hospital Surabaya

E-mail: nyilo@fk.unair.ac.id

Abstract. Prediction of ossicular status in chronic suppurative otitis media (CSOM) before tympanomastoidectomy was required for selection of surgical techniques. Some studies about prediction of ossicular status with pure tone average had revealed different results. This study aimed to prove correlation between pure tone average and ossicular status in CSOM patients whom underwent tympanomastoidectomy at Department of Otorhinolaryngology Head and Neck Surgery Dr. Soetomo Hospital Surabaya. This was an observational analytic study with retrospective cross sectional design using secondary data of medical record. Simple randomized sampling was derived from CSOM patients whom underwent tympanomastoidectomy and appropriated with inclusion and exclusion criterias. Ossicular status during the surgery was obtained from operation report based on Austin-Kartush criterias. Pure tone average is the average threshold of hearing in speech frequencies that were 500, 1000, 2000, and 4000 Hz from audigram. About 65 CSOM patients who underwent tympanomastoidectomy were included to this. The ossicular erosion in the study was 63,1% while the normal ossicles (ossicular status O) was 36,9%. The most common ossicular erosion all ossicles (ossicular status D) 36,9%; followed by incus and stapes (ossicular status B) as 9,2%; incus (ossicular status A) as 10,7%; malleus and incus (ossicular status C) as 6,2%; and fixation of stapes (ossicular status F) as 3,1%. Two-way Anova test resulted p value = 0,00 ($p < 0,05$). There was correlation between pure tone average and ossicular status in chronic suppurative otitis media patients. Increased pure tone average could estimate presence of ossicular erosion before surgery obtained in chronic suppurative otitis media patients.

1. Introduction

Hearing loss in CSOM patients is primarily conductive type but may also be mixed type. Degree of hearing loss depends on the presence of ossicular damage. Ossicular erosion and fixation result in hearing loss more than 30 dB (Browning, et al., 2008; Mittal, et al., 2015). Ossicular erosion is a frequent CSOM complication of about one third of all cases of CSOM. Ossicular erosion is assessed during surgery. Ossicular status is an assessment of the integrity of each ossicles [1].

Prediction of ossicular status before tympanomastoidectomy is required as a basic for selection of surgical techniques. Estimates of preoperative ossicular status can be through by pure tone audiometry and high resolution computed tomography (HRCT) mastoid scan. Pure tone audiometry is a routine examination prior to ear surgery to assess hearing function and quantitatively assess the pure-tone average (PTA) of CSOM patients [2].

Some studies of PTA as a preoperative parameter of ossicular status in chronic suppurative otitis media had given different results [3], [4]. Study by Feng found that PTA in CSOM patients with



ossicular erosion was higher than patients without ossicular erosion and could be used to estimate ossicular status [4]. Another study for predictive value of the audiogram on ossicular status showed that PTA was higher in the group with ossicular erosion but did not provide significant predictive value for ossicular status [3]. The objective of the study was to analyze the association between PTA and ossicular status in patients with CSOM in Dr. Soetomo Hospital Surabaya.

2. Methods

This is an analytic observational study with cross sectional retrospective design using secondary data. The data were taken from medical record of Otology Division ORL-HNS Dr. Soetomo Hospital Surabaya for two years period from January 1st, 2015 to December 31st, 2016. Subjects of this study were CSOM patients whom had performed tympanomastoidectomy and according to the criterias of inclusion and exclusion by simple random sampling. Inclusion criterias were patients with complete medical record data, preoperative audiogram, and has an operation report of ossicular status assessment. Exclusion criteria are otosclerosis, middle tissue polyp, ossicular malformation, ossicular agenesis, sensorineural type hearing loss, and previous history of tympanomastoidectomy.

The pure tone average was calculated as the mean of sum of air conduction at frequency at 500, 1000, 2000, and 4000 Hz from audiogram. Ossicular status is an assessment of the ossicular chain when tympanomastoidectomy by ORL-HNS Specialist Consultant of Otology and then classified by Austin and Kartush into seven types.

Table 1. Ossicular status based on Austin and Kartush [5].

No	Type	Ossicular Status
1	O	M+I+S+
2	A	M+S+
3	B	M+S-
4	C	M-S+
5	D	M-S-
6	E	Maleus fixation
7	F	Stapes fixation

Statistical test to analyze the relationship between pure tone average and ossicular status using two-way Anova test with significance level (α) of 0,05.

3. Result

Hearing loss moderate to severe degree was found in this study of 29,3%, followed by moderate degree as much as 24,6%, severe degree as much as 20,0%, profound degree as much as 13,8%, and mild degree as much as 12,3%.

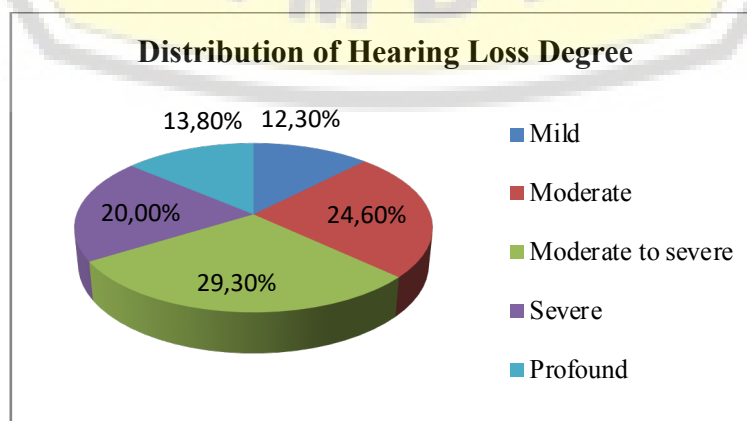


Figure 1. Distribution of degree of hearing loss.

Maleus was obtained most intact condition as much as 56,9% while destruction as much as 43,1%.

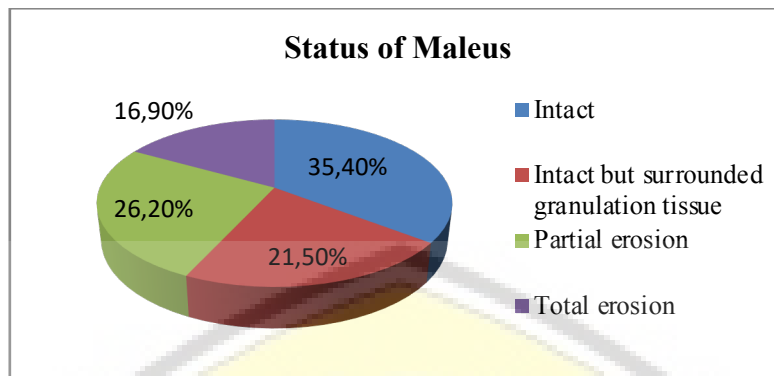


Figure 2. Distribution status of maleus.

Incus was found most destructed condition as much as 60,0% while intact was only 40,0%.

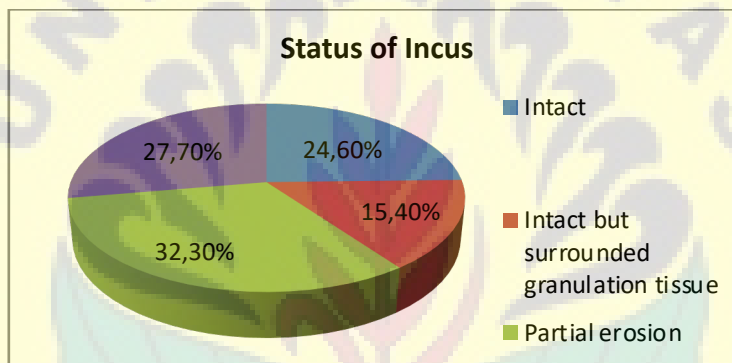


Figure 3. Distribution status of incus.

Stapes was obtained most intact condition as much as 50,8%, followed destruction as much as 46,2%, and fixation as much as 3,1%.

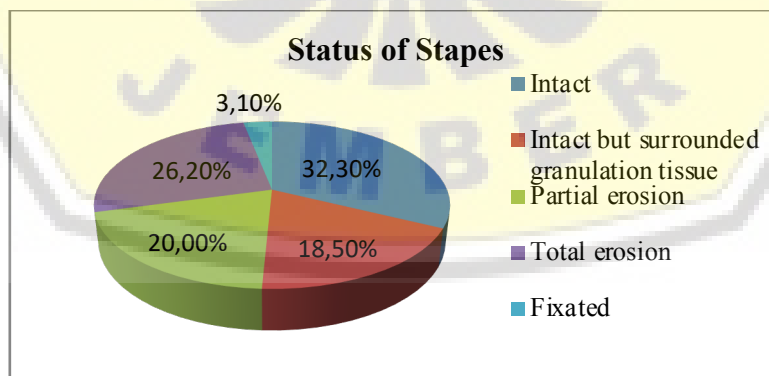


Figure 4. Distribution status of stapes.

The most common ossicular status was type O and D as much as 36,9%, type B as much as 9,2%, type A as much as 10,7%, type C as much as 6,2%, and type Fas much as 3,1%. There was no type E ossicular status in this study.

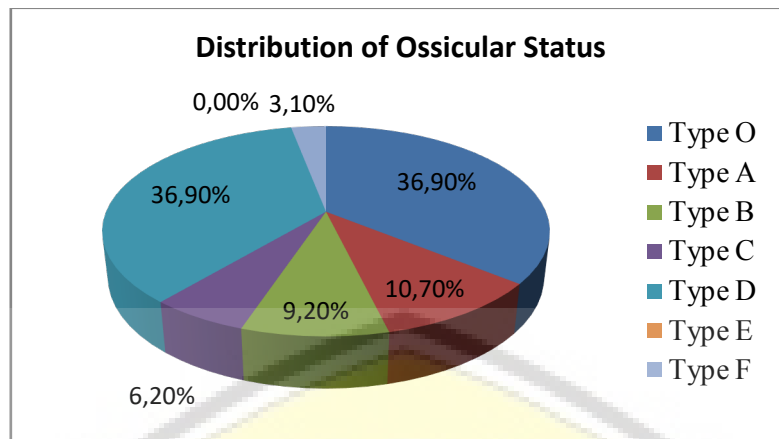


Figure 5. Distribution of ossicular status type based on Austin Kartush.

A two-way anova test between the groups revealed $p = 0.000$ ($p < 0,05$). This result showed a significant relationship between pure tone average and ossicular status.

4. Discussion

The highest degree of hearing loss in this study was moderate weight of 29.3%, followed by moderate degree as much as 24,6%, severe degree as much as 20,0%, very severe degree as much as 13,8%, and mild degree as much as 12,3 %. Chronic suppurative otitis media causes mild to moderate degree conductive hearing loss in over 50% of cases. Degree of hearing loss in CSOM is influenced by size and location of tympanic membrane perforation, granulation tissue, cholesteatoma, and ossicular erosion.

The most common intact ossicle in this study was maleus (55,4%), followed by stapes (50,8%), and incus (38,5%). The most destroyed ossicle was incus (61,5%), followed by stapes (49,2%), and maleus (44,6%). The long process incus was an ossicle that has a long and hanging structure, a location in mesotympanum, as well as rare vascularization so susceptible to destruction [6].

Ossicular status in this study found that the ossicular status O (intact) as much as 36,9% and ossicular destruction as much as 63,1%. Most ossicular destruction was found in three ossicles (ossicular status D), which was 36,9%, followed by incus and stapes (ossicular status B) as much as 9,2%, incus destruction (ossicular status A) as much as 10,7%, destruction of maleus and incus (ossicular status C) as much as 6,2%, and stapes fixation (ossicular status F) as much as 3,1%.

This study showed that there was a relationship between pure tone average and ossicular status in CSOM patients with p value between groups = 0.000 ($p < 0,05$). This was appropriate with other studies that showed the value of AC and air bone gap on ossicular erosion higher than without ossicular erosion. That study concluded that AC and air bone gap values were reliable indicators for ossicular status in the CSOM [7]. Ear-canal collapse due to pressure of the earphone on the pinna during audiometry can display erroneous air bone gap at high frequencies. High frequency air bone gap have also been implicated to be the result of instrument calibration errors.

Ossicular destruction may cause conductive hearing loss, which is also affected by perforation of the tympanic membrane, granulation tissue, and cholesteatoma. Large perforations of the tympanic membrane generally cause hearing loss of 40-50 dB, whereas total perforation is up to 60 dB. Differences in degree of hearing loss at the same perforated size can be due to differences in the volume of the middle ear and mastoid cavity of each ear. The degree of hearing loss due to colesteatoma depends on the size and ability of cholesteatoma to erode the ossicular chain. The ossicular destruction interferes the aerodynamic acoustic transmission process, thus lowering air conduction not followed by bone conduction in the audiogram. Decreased of air conduction increases the pure tone average of audiogram.

5. References

- [1] Haidar H, Sheikh R, Larem A, Abdulkarim H, Ashkanani S and Alqahtani A 2015 Ossicular chain erosion in chronic suppurative otitis media *Otolaryngol* 5 (4) pp 1-4
- [2] Sheikh A, Haidar H, Abdulkarim H, Aslam W, Larem A and Alsaadi A 2016 Preoperative predictors in chronic suppurative otitis media for ossicular chain discontinuity: across-sectional study *Audiol Neurotol* 21: pp 231–236.
- [3] Jeng F, Tsai M and Brown C 2003 Relationship of preoperative findings and ossicular discontinuity in chronic otitis media *Otol Neurotol* 24 (29) pp 32-40
- [4] Feng H, Chen Y and Ding Y 2005 Analysis of preoperative findings and ossicular condition in chronic suppurative otitis media. *Lin Chuang Er Bi Yan Hou Ke Za Zhi* 2005 19 (1) pp 7-10
- [5] Anglitoiu A, Balica N, Lupescu S, Vintila R and Cotulbea S 2011 Ossicular chain status in the otological pathology of the ENT clinic Timisoara *Medicine in Evolution* 17 (4) pp 344-352
- [6] Nayak GK, Barhma D, Chatterjee P and Sharma P 2016 Ossicular chain status in chronic suppurative otitis media *J. of Dental and Medical Sci* 15 (3) pp 20-23.
- [7] Yazdi AK, Saedi B, Fayeziadah and Seifmanes H 2011 Association between audiometric profile and intraoperative findings in patients with chronic suppurative otitis media. *Iranian J of Otorhinolaryngol* 2 (23) pp 37-43

