

DOI: <http://dx.doi.org/10.33846/hn60901>
<http://heanoti.com/index.php/hn>



RESEARCH ARTICLE

URL of this article: <http://heanoti.com/index.php/hn/article/view/hn60901>

Cocoa Bean Extract Impact on the Number of Osteoblast and Osteoclast in Orthodontic Teeth Movement

Rudy Joelijanto^{1(CA)}, Rina Sutjiati², Sulistiyani³, Sayidah Khadijah⁴, Fitri Arida Sabhatina⁵

^{1(CA)}Department of Orthodontics, Faculty of Dentistry, Universitas Jember, Jember, Indonesia;
rudyjoel92@gmail.com (Corresponding Author)

²Department of Orthodontics, Faculty of Dentistry, Universitas Jember, Jember, Indonesia;
rinasutjiati@unej.ac.id

³Departement of Pediatric Dentistry, Faculty of Dentistry, Universitas Jember, Jember, Indonesia;
sulistiyani.fkg@unej.ac.id

⁴Faculty of Dentistry, Universitas Jember, Jember, Indonesia

⁵Faculty of Dentistry, Universitas Jember, Jember, Indonesia

ABSTRACT

In orthodontic therapy, mechanical force produces remodeling. Because the process of bone resorption on tooth movement is larger than that of bone apposition when a normal force is applied, a balance is required by increasing the number of osteoblasts and lowering the number of osteoclasts. The purpose of this study was to look at the ability of cocoa bean extract to assist balance the apposition and resorption of alveolar bone during orthodontic tooth movement. A total of 36 male *Wistar* rats were separated into three groups of Group K-(untreated rats), K+ (giving an orthodontic mechanical force), and P (giving an orthodontic mechanical force and a dosage of 250 mg/kg BW cocoa bean extract). Following euthanasia at 7 and 14 days of therapy and osteoblasts and osteoclasts were counted. The results showed that there was an increase in osteoblasts number and a decrease in osteoclasts number in the treatment group, as indicated by the results of calculating the average number of cells in each group, which were supported by statistical tests using SPSS, which revealed significant differences between groups. In orthodontic tooth movement, cocoa bean extract has the ability to enhance the number of osteoblasts while decreasing the number of osteoclasts.

Keywords: osteoblasts; osteoclasts; orthodontic tooth movement; cocoa bean extract

INTRODUCTION

Orthodontic therapy is well known to take a lengthy period. The period of fixed orthodontic treatment might be as long as 24.9 months. Even with extraction, it might take up to 35 months^(1,2). The duration of orthodontic treatment is connected to the process of bone remodeling, which is a succession of processes of bone resorption by osteoclasts in stressed areas and bone apposition by osteoblasts in tension areas⁽³⁾. Good bone remodeling can help to prevent excessive bone resorption.

The presence of mechanical forces during orthodontic treatment produces an inflammatory process and the development of reactive oxygen species, resulting in an imbalance between osteoclast and osteoblast activity, which is characterized by increased bone resorption and osteoblast death⁽⁴⁾. Other illnesses, including gingivitis and periodontitis, as well as poor habits like smoking, might induce an imbalance during the alveolar bone remodeling process. Furthermore, the overall health of people with vitamin D deficiency might result in increased bone resorption and reduced bone production. It is believed that one million individuals worldwide, including in Indonesia, are vitamin D deficient. People of all ages, from toddlers to the elderly, can be affected by vitamin D insufficiency. Orthodontic therapy takes a long time because teeth do not keep their place adequately and might cause changes in tooth position as a result of excessive resorption and poor apposition^(5,6).

As a result, we require a substance that may reduce resorption activity while also improving bone apposition during orthodontic therapy, one of the ingredients is antioxidants⁽⁷⁾. Antioxidant compounds are needed that can prevent cell damage during orthodontic treatment. The human body is able to neutralize ROS if the amount is not excessive, namely with endogenous antioxidant defense mechanisms. When endogenous antioxidants are insufficient, the body needs outside antioxidants. Therefore, antioxidant compounds are needed that can prevent cell damage during orthodontic treatment⁽⁴⁾. Antioxidants can be obtained through synthetic and natural, but the use of synthetic antioxidants has been limited by the government because it has carcinogenic side

effects. Then it takes natural antioxidant compounds, one of which is obtained from cocoa beans (*Theobroma Cacao L*). Interestingly, cocoa beans have antioxidant content with the largest flavonoid compounds being catechins or flavan-3-ols $\pm 37\%$, anthocyanins by $\pm 4\%$, and proanthocyanin $\pm 58\%$. Flavanol monomers (epicatechin and catechin) and oligomers of proanthocyanidins account for about 60% of the total polyphenols in cocoa beans (raw) ^(8,13).

The purpose of this study was to see if cocoa bean extract (*Theobroma Cacao L*) might decrease the number of osteoclasts while raising the number of osteoblasts in the alveolar bone of *Wistar* rat teeth during orthodontic tooth movement. The value of this research is that it can provide scientific insight into the ability of cocoa bean extract to reduce the number of osteoclasts and raise the number of osteoblasts, as well as to help enhance the results of bone remodeling so that teeth can keep their normal position.

METHODS

This was a laboratory experimental study with a posttest-only control group design. A total of 36 male *Wistar* rats, aged 3-4 months and weighing 200-225 grams, were separated into three groups: negative control (K-7, K-14), positive control (K+7, K+14), and treatment (P7, P14). The negative control group consisted of rats who received no therapy for 7 days (n=6) and 14 days (n=6). The group that had NiTi closed coil spring installation for 7 days (n=6) and 14 days (n=6) served as the positive control group. The rats in the treatment group were given NiTi closed coil spring installation and cocoa bean extract for 7 days (n=6) and 14 days (n=6). The Health Research Ethics Commission, Faculty of Dentistry, Universitas Jember has granted ethical clearance under the number: No.1312/UN25.8/KEPK/DL/2021.

Cocoa bean extract made from Lindak cocoa beans harvested by cocoa producers PTPN X Kertosari Antirogo Gardens. 6 kg of cocoa beans were extracted using the maceration process with 96% ethanol as the solvent in a 1:4 ratio. The maceration procedure lasted three days. The maceration products are then filtered and transported to an evaporation flask to be concentrated using a rotary evaporator machine at 40-50°C for 2 hours. 62 grams of cocoa bean extract were collected. Each rat received 50 mg of cocoa bean extract diluted in 2 cc of distilled water.

The NiTi closed coil spring was positioned between the right maxillary first molar and the maxillary incisor. To move the teeth mesially, the strength of the NiTi closed coil spring of 10 gF was determined using a tension gauge. After 7 and 14 days of therapy, mice were beheaded. Furthermore, the maxillary sample in the right area was fixed for 24 hours with 10% BNF before histological preparations.

The method of generating histological preparations begins with decalcification with 10% formic acid, followed by dehydration with graded alcohol, cleaned with xylol, impregnation, and embedding, which is the implantation of tissue into paraffin. The tissue was then sliced with a rotary microtome with a 5 μm thickness. Slices of the rat teeth were taken from the coronal to the apical direction, revealed the creation of teeth and undamaged alveolar bone in the tension and pressure areas. The tissue was then stained with hematoxylin and eosin (HE).

A light microscope with a 400-times objective lens magnification was used to see and count osteoblasts and osteoclasts. Both were counted in three visual fields: the top third, middle third, and bottom third of the 1st molar's alveolar bone. To eliminate subjectivity, observations were made by three observers. The outcomes of the three computations are then averaged. A test with the SPSS version 26 program was utilized in this study to see the differences between the control and treatment groups.

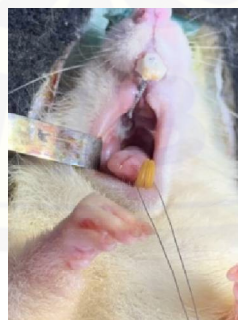


Figure 1. The results of the ni-ti closed coil spring installation on the 1st molar teeth of *Wistar* rats

RESULTS

Osteoblast

Periodontal ligament tension was shown to have alveolar bone osteoblasts (Figs 2a & 2b). The treatment group had more osteoblasts on average than the control group (Figure 3a and Table 1). The LSD test findings revealed a significant difference between the treatment groups with positive controls and the treatment groups with negative controls ($p \leq 0,05$).

Table 1. The mean and standard deviation (SD) of the number of osteoblasts in the tension area of the negative control, positive control, and treatment groups

Time	Negative control (mean±SD)	Positive control (mean±SD)	Treatment (mean±SD)
7 days	13.24±0.83	16.91±0.31	21.91±0.73
14 days	14.16±0.63	18.75±0.41	23.83±2.64

Osteoclast

Periodontal ligament tension was shown to have alveolar bone osteoclasts (Figs 2c & 2d). The treatment group had fewer osteoclasts on average than the positive control group (Figure 3b and table 2). The Mann-Whitney test revealed a significant difference in the treatment group with positive control and the negative control group with negative control ($p \leq 0.05$).

Table 2. The mean and standard deviation (SD) of the number of osteoclasts in the pressure area of the negative control, positive control, and treatment groups

Time	Negative control (mean±SD)	Positive control (mean±SD)	Treatment (mean±SD)
7 days	0.47±0.42	7.7±3.23	1.22±0.59
14 days	0.25±0.5	3.97±2.24	0.55±0.41

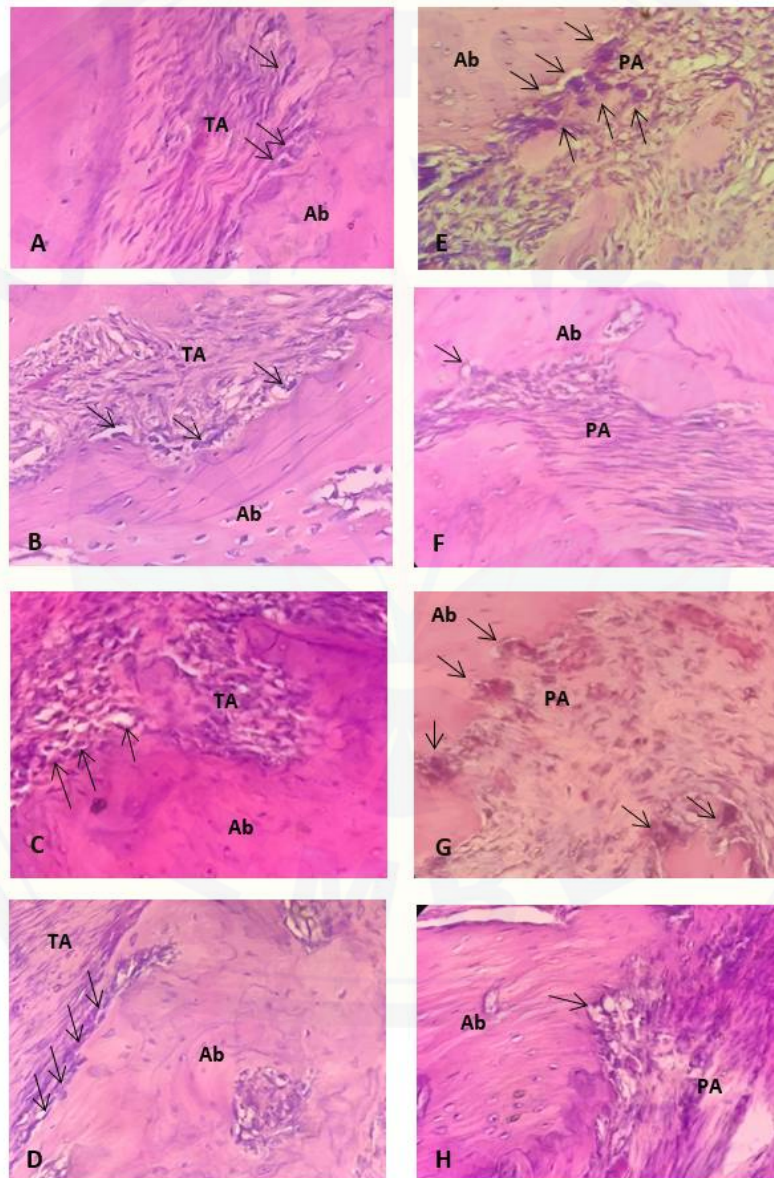


Figure 2. Histological appearance of osteoblasts and osteoclast areas with HE staining at 400 times magnification. a) Osteoblasts positive control group 7 days; b) Osteoblasts treatment group 7 days; c) Osteoblasts positive control group 14 days; d) Osteoblasts treatment group 14 days; e) 7 days positive control group osteoclasts; f) Osteoclast treatment group 7 days; g) Osteoclasts in the positive control group for 14 days; h) Osteoclast treatment group 14 days. (Ab: alveolar bone; TA: tension area; PA: pressure area).

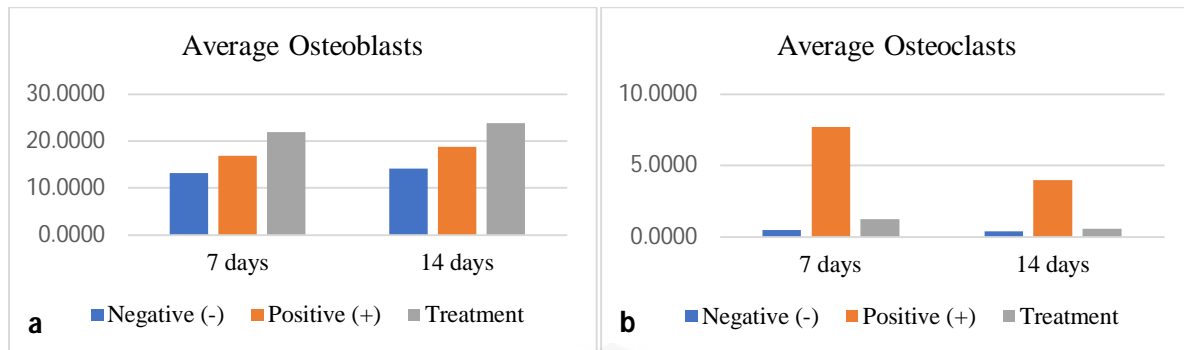


Figure 3. Histogram of the average number of osteoclasts and osteoblasts in the negative, positive control, and treatment groups

DISCUSSION

Cell osteoblasts and osteoclasts are critical components in the process of alveolar bone remodelling. Bone remodelling is an ongoing and dynamic process that is dependent on a balance of osteoclast resorption and osteoblast apposition.

According to the findings of this study, the treatment group had an average of more osteoblasts on days 7 and 14 than the control group on those days. These findings demonstrated that the cocoa extract was efficient in raising the number of osteoblasts on the 7th and 14th days. This major alteration happens during the early phase, when the teeth move fast roughly 24 to 48 hours after the first orthodontic force is applied. The presence of antioxidant chemicals in cocoa beans produced an increase in osteoblasts in the treatment group. According to several research, kaolin beans do not contain significant levels of polyphenolic chemicals, polyphenolic substances have been proven to enhance the amount of osteoblasts in the body ⁽⁹⁾.

Polyphenols can bind ROS, inhibiting the production of osteogenic marker transcription factors in osteoblasts. Polyphenols influence the expression of osterix and Runx2. Furthermore, Runx2 will induce mesenchymal stem cell differentiation into preosteoblasts and subsequently stimulate osteoblasts to induce preosteoblast development into osteoblasts ⁽¹⁰⁾. Cocoa antioxidants are required in the bone remodelling process to boost osteoblast differentiation so that bone mineralization happens fast and the efficacy of osteoclasts is lowered so that bone resorption is not excessive ⁽⁴⁾.

The study's findings also revealed that the average number of osteoclasts in the treatment group was lower than in the positive control group. The Mann-Whitney test findings demonstrated a significant difference between the 7-day positive control group and the 7-day treatment group ($p=0.021$) and the 14-day positive control group and the 14-day treatment group ($p=0.028$). This considerable difference suggests that cocoa bean extract may lower the amount of osteoclasts during orthodontic therapy.

The reduction in the number of osteoclasts seen in the treatment group was attributable to flavonoids, which have been shown to lower alveolar bone resorption by a mechanism that might decrease RANKL expression and increase OPG expression, so slowing the process of osteoclast creation. Because OPG is a decoy receptor for RANKL, it inhibits the interaction of RANKL and RANK in the cell membrane of osteoclast precursors, hence suppressing osteoclastogenesis. Inhibiting osteoclastogenesis can reduce the number of osteoclasts, lowering bone resorption ⁽¹¹⁾. According to Lagha et al., (2021), cocoa bean extract was considerably capable of inhibiting NF- κ B activation. NF- κ B is a transcription factor that enters the nucleus through RANK-RANKL interaction. The transcription factor NF- κ B has been linked to the early phases of osteoclast formation. Osteoclast differentiation does not occur in mice with low levels of NF- κ B ⁽¹²⁾.

Overall, the number of osteoblasts in the treatment group increased significantly when compared to the control group, whereas the number of osteoclasts decreased significantly when compared to the positive control group. This demonstrates that lindak cocoa bean extract has the capacity to enhance the number of osteoblasts while decreasing the number of osteoclasts in the alveolar bone during orthodontic tooth movement.

CONCLUSION

In orthodontic tooth movement, the administration of cocoa bean extract (*Theobroma Cacao L.*) lindak variety might potentially enhance the number of osteoblasts and reduce the number of osteoclasts in the alveolar bone of *Wistar* rats.

REFERENCES

1. Abbing A, Koretsi V, Eliades T, Papageorgiou SN. Duration of orthodontic treatment with fixed appliances in adolescents and adults: a systematic review with meta-analysis. *Prog Orthod.* 2020;21(1).
2. Alhasyimi AA, Rosyida NF. Cocoa administration may accelerate orthodontic tooth movement by inducing

- osteoclastogenesis in rats. *Iran J Basic Med Sci.* 2019;22(2):206–10.
3. Kitaura H, Kimura K, Ishida M, Sugisawa H, Kohara H. Effect of Cytokines on Osteoclast Formation and Bone Resorption during Mechanical Force Loading of the Periodontal Membrane Effect of Cytokines on Osteoclast Formation and Bone Resorption during Mechanical Force Loading of. *Sci World J.* 2014;2014:1–7.
 4. Domazetovic V, Marcucci G, Iantomasi T, Brandi ML, Vincenzini MT. Oxidative stress in bone remodeling: Role of antioxidants. *Clin Cases Miner Bone Metab.* 2017;14(2):209–16.
 5. Pusparini P. Vitamin D Deficiency and Diseases. *Indones J Clin Pathol Med Lab.* 2018;21(1):90.
 6. Fischer V, Haffner-Luntzer M, Prystaz K, Scheidt A Vom, Busse B, Schinke T, et al. Calcium and vitamin-D deficiency marginally impairs fracture healing but aggravates posttraumatic bone loss in osteoporotic mice. *Sci Rep.* 2017;7(1):1–13.
 7. Alamsyah Y, Elianora D. Effect of Mangiferin (*Mangifera Indica* Linn) on the amount of osteoclast in the post-orthodontic treatment of bone Remodelling. In: *Preparing Dentist To Approach Industrial Revolution 40.* UNMAS Press; 2019. hal. 168–74.
 8. Ruso S, Pirman P. the Processing and Analysis of the Polyphenols Content of Cocoa Bean (*Theobroma Cocoa L*) and the Development As Functional Foods. In: *Prosiding Seminar Hasil Penelitian (SNP2M)* [Internet]. 2018. hal. 153–8. Tersedia pada: <http://jurnal.poliupg.ac.id/index.php/snp/article/download/837/730%0Ahttps://lens.org/049-661-307-342-846>
 9. Trzeciakiewicz A, Habauzit V, Horcajada MN. When nutrition interacts with osteoblast function: Molecular mechanisms of polyphenols. *Nutr Res Rev.* 2009;22(1):68–81.
 10. Darmadi D. The Effect of Propolis on Increasing the Number of Osteoblasts And Chondrocytes, And Decreasing the Number of Osteoclasts in Wistar Rats (*Rattus norvegicus*) with Femoral Bone Fracture. *IOSR J Dent Med Sci e-ISSN* [Internet]. 2016;15(12):90–5. Tersedia pada: www.iosrjournals.org
 11. Kajiya M, Giro G, Taubman MA, Han X, Mayer MPA, Kawai T. Role of periodontal pathogenic bacteria in RANKL-mediated bone destruction in periodontal disease. *J Oral Microbiol.* 2010;2(2010):1–16.
 12. Lagha A Ben, Maquera Huacho P, Grenier D. A cocoa (*Theobroma cacao L.*) extract impairs the growth, virulence properties, and inflammatory potential of *Fusobacterium nucleatum* and improves oral epithelial barrier function. *PLoS One* [Internet]. 2021;16(5):1–17. Tersedia pada: <http://dx.doi.org/10.1371/journal.pone.0252029>
 13. Wollgast J, Anklam E. Wollgast, J., & Anklam, E. (2000). Review on polyphenols in *Theobroma cacao*: changes in composition during the manufacture of chocolate and methodology for identification and quantification. *Food Research International* [Internet]. 2000;33(6):423–47. Available from: www.elsevier.com/locate/foodres