



Contents lists available at ScienceDirect

## Journal of Pediatric Surgery Case Reports

journal homepage: [www.elsevier.com/locate/epsc](http://www.elsevier.com/locate/epsc)

# Intussusception related to Ogilvie's syndrome caused by herpes zoster infection

Supangat<sup>a,\*</sup>, Yuli Lusiana Sari<sup>b</sup>, Fuad Adi Prasetyo<sup>b</sup>, Nastiti Widoretno<sup>b</sup>,  
Madha Qoyyuledy Tursina<sup>b</sup><sup>a</sup> Department of Pediatric Surgery, Dr. Soebandi Regional Hospital-Faculty of Medicine, Jember University, East Java, Indonesia<sup>b</sup> Faculty of Medicine, Jember University, East Java, Indonesia

## ARTICLE INFO

## Keywords:

Intussusception  
Ogilvie's syndrome  
Varicella

## ABSTRACT

**Background:** A case of intestinal pseudo-obstruction (Ogilvie's syndrome) caused by herpes zoster infection, likewise appendicitis in infants and newborns is very rare. An understanding of the rare association is important to provide proper management and prevent associated morbidity and mortality.

**Case presentation:** A 5-year-old female child was brought to Dr. Soebandi General Hospital by her parents with constipation, vomiting, and enlarged stomach. In the physical examination there were distended abdomen, increased bowel sound, and tenderness throughout the abdomen, initially diagnosed as peritonitis due to perforated appendicitis. Plain abdominal x-ray shows intestinal gas enhancement and bowel dilatation and in the left lateral decubitus (LLD) position photo revealed multiple step ladder appearances. Then this patient was performed an exploratory laparotomy. There we found peritonitis with intussusception. This bowel obstruction was associated with red vesicles that indicate the herpes zoster virus infection.

**Conclusions:** This patient was suffering intussusception related to Ogilvie's syndrome caused by herpes zoster infection. Intussusception can induce Intestinal pseudo-obstruction or total obstruction. Acute colonic pseudo-obstruction (Ogilvie's syndrome) is a disorder characterized by acute dilatation of the colon in the absence of an anatomic lesion that obstructs the flow of intestinal contents.

## 1. Background

Intussusception may induce intestinal pseudo-obstruction that was characterized by dilatation of the bowel in the absence of anatomical obstruction. Colonic pseudo-obstruction is a form of colonic dysmotility which is a final common pathway of various physiological, electrolyte and biochemical disturbances. There are primary and secondary pseudo-obstructions. Primary pseudo-obstruction is the familial visceral myopathy or hollow visceral myopathy syndrome, a diffuse motility disorder involving autonomic innervations of the intestinal wall. Secondary pseudo-obstruction is associated with other conditions such as the use of some medications, infection, severe metabolic illness, diabetes, uremia, hyperparathyroidism, etc. Intussusception related to Acute colonic pseudo-obstruction (ACPO, also called Ogilvie's syndrome) is a rare disorder characterized by invagination causing colonic dilatation in the absence of a mechanical cause [1,2]. Perforation and intestinal ischemia are the most severe complications. They are

\* Corresponding author. Department of Surgery, Dr. Soebandi General Hospital, Faculty of Medicine Universitas Jember, Jl. Kalimantan No.37, Krajan Timur, Sumbersari, Kec. Sumbersari, Jember, East Java, 68121, Indonesia.

E-mail address: [drsupangat@unej.ac.id](mailto:drsupangat@unej.ac.id).

<https://doi.org/10.1016/j.epsc.2022.102482>

Received 14 September 2022; Received in revised form 6 October 2022; Accepted 11 October 2022

Available online 12 October 2022

2213-5766/© 2022 The Author(s). Published by Elsevier Inc. This is an open access article under the CC BY-NC-ND license (<http://creativecommons.org/licenses/by-nc-nd/4.0/>).

the major reasons that surgical intervention is often required. Here we present a rare case of intussusception related to Ogilvie's syndrome secondary to herpes zoster infection.

## 2. Case presentation

A 5-year-old female child was brought to dr. Soebandi General Hospital by her parents with constipation, vomiting, and enlarged stomach. Her parents have observed her being unable to pass stool in the past 3 days. The patient was ill in appearance. Through physical examination we found that the patient had an elevated body temperature at 37,4 °C, distended abdomen, increased bowel sound, and tenderness throughout the abdomen, initially diagnosed as peritonitis due to perforated appendicitis. Based on laboratory examination results, there was leukocytosis (white blood cell count: 12.510/cmm). Abdominal plain radiographs revealed stepladder pattern (Fig. 1) and air-fluid level in LLD radiograph (Fig. 2).

The patient was diagnosed with partial bowel obstruction for initial assessment. A rectal tube was inserted, and a black stool was found. On the second day of admission red vesicles appeared throughout the patient's body, based on the clinical sign, the patient was diagnosed as varicella and treated with Acyclovir cream. On the 9th day of admission, the exploratory laparotomy was performed.

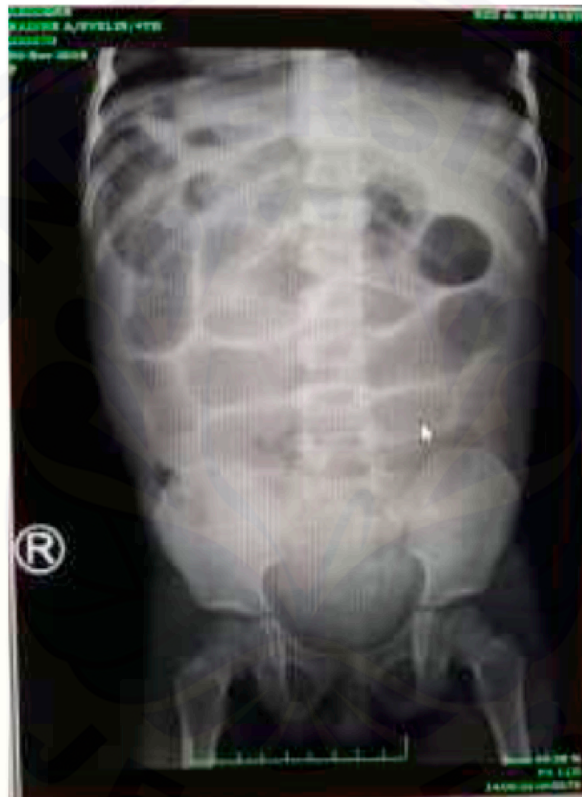

Fig. 1. Abdominal radiograph shows intestinal gas enhancement and bowel dilatation.

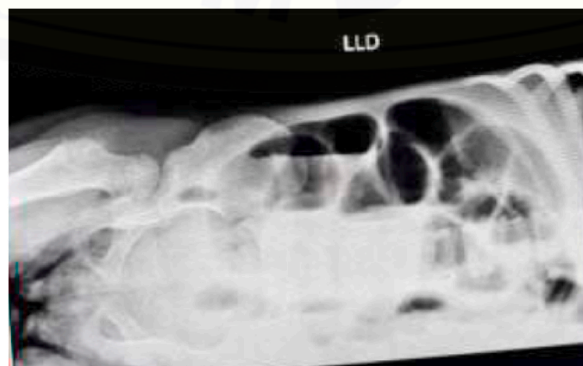


Fig. 2. LLD photo shows there are multiple step ladder appearances.

During the surgery, there was bowel obstruction due to intussusception in the ileo-caecal junction with an enlargement of lymph node as the suspected leading point of intussusception. There was also found perforated bowel that was suspected of causing peritonitis. Based on that finding, the patient was diagnosed having intussusception related to Ogilvie's syndrome caused by herpes zoster infection. Ileostomy then was made. There was no problem after the surgery. She was discharged on the 16th day.

### 3. Discussion

Acute colonic pseudo-obstruction (Ogilvie's syndrome) is a disorder characterized by acute dilatation of the colon in the absence of an anatomic lesion that obstructs the flow of intestinal contents. The pathophysiology is not completely understood. It is believed to result from either a suppression of sacral parasympathetic nerves or an increase in sympathetic tone leading to inhibition of colonic motility. ACPO is uncommon, with an identified incidence of approximately 100 cases per 100,000 inpatient admissions [1–4]. A recent US study reported a declining mortality rate associated with ACPO from 9.4% in 1998 to 6.4% in 2011, although over-diagnosis may have contributed; historically mortality rates were as high as 30% [5]. The prevailing hypothesis remains that ACPO is the result of reduced parasympathetic innervation to the distal colon, leading to an atonic segment and functional obstruction. ACPO has also been associated with several viral infections, most commonly herpes zoster reactivation in low thoracic or lumbar distributions, but also disseminated varicella zoster, acute cytomegalovirus, and severe dengue. Several mechanisms have been proposed to explain these associations, all involving autonomic dysfunction [4,6]. Reactivation of the latent virus in dorsal root ganglion and cranial nerve ganglion, seen in 30% of individuals presents with papulovesicular lesions over single dermatome or cranial nerve distribution and the virus may cause several gastrointestinal disorders like acute or chronic colonic pseudo-obstruction and idiopathic gastroparesis [2,6].

The clinical features are nausea, vomiting, abdominal pain, constipation, and fever. Bowel sounds may be hyperactive, hypoactive, or absent. Common symptoms of Ogilvie syndrome include abdominal swelling (distention) and bloating, abdominal pain, nausea, and vomiting. Some individuals have a history of chronic, sometimes severe constipation. Abdominal distention usually develops over several days but can potentially develop rapidly within a 24-h period.

Colonic distention can be massive. Additional symptoms that can occur including fever, marked abdominal tenderness and an abnormal increase in the number of white blood cells (leukocytosis) often due to infection. Fever, marked abdominal tenderness, and leukocytosis are more common in individuals with perforation or ischemia, but can occur in the absence of these conditions. A review of 29 cases published in 21 reports between 1950 and 2008 revealed that cutaneous manifestations may appear one day to one month before the pseudo-obstruction, appear simultaneously or 1 day to several weeks after the pseudo-obstruction [7]. The history of vesicular lesions in recent past and detailed examination to look for herpes zoster should be part of evaluation of cases of Ogilvie's syndrome. Routine microbiological investigation like PCR, immunofluorescence testing, cell cultures to detect VZV in stool, blood or colonic wall is not recommended because of variable sensitivity and specificity of these and high cost [2]. The diagnosis of varicella zoster should be sufficient to establish association and initiate pharmacological treatment of Acyclovir.

### 4. Conclusion

This patient was suffering intussusception related to Ogilvie's syndrome caused by herpes zoster infection. Intussusception can induce Intestinal pseudo-obstruction or total obstruction. Symptoms occur due to continued peristaltic contractions of the intussuscepted segment against the obstruction. With continued invagination resulting in edema, eventually the vascular flow to the bowel becomes compromised, resulting in ischemia to the affected segment that, left untreated, can result in necrosis and perforation. Acute colonic pseudo-obstruction (Ogilvie's syndrome) is a disorder characterized by acute dilatation of the colon in the absence of an anatomic lesion that obstructs the flow of intestinal contents.

### Author contributions

Supangat and EN Sakinah perform the surgery, provide expert opinion and manuscript guarantee. MY Nugraha, AI Tohari, TS Qodar, N Widoretno, MQ Tursina drafted the manuscript. BW Mulyono and MRF Hidayat give interpretation during patient's examination. YL Sari and FA Prasetyo taking the consent from patient's parent and perform anamnesis.

### Financial disclosure

None to report.

### Informed consent

Informed consent was obtained for this case report.

### Declaration of competing interest

The authors declare that they have no known competing financial interests or personal relationships that could have appeared to influence the work reported in this paper.

## Acknowledgement

We thank the patient's parent for giving permission to the authors to write the case of their child.

## References

- [1] Carrascosa M.F, Salcines-Caviedes J.R, Román J.G, Cano-Hoz M, Fernández-Ayala M, Casuso-Sáenz E, Abascal-Carrera I, CampoRuiz A, Martín M.C, Díaz-Pérez A, González-Gutiérrez P, Aguado J.M. Varicella-zoster virus (VZV) infection as a possible cause of Ogilvie's syndrome in an immunocompromised host. *J Clin Microbiol* 2014;52:2718–21.
- [2] Tanida E, Izumi M, Abe T, Tsuchiya I, Okuma K, Uchida E, Hidaka A, Hayashi E, Noguchi M, Masui Y, Yoshizawa K, Shirahama K, Kanezaki A. [Disseminated varicella-zoster virus infection complicated with severe abdominal pain and colonic pseudo-obstruction]. *Nihon Shokakibyo Gakkai Zasshi* 2013;110:839–45.
- [3] Zell R, Taudien S, Pfaff F, Wutzler P, Platzer M, Sauerbrei A. Sequencing of 21 varicella-zoster virus genomes reveals two novel genotypes and evidence of recombination. *J Virol* 2012.
- [4] Wrenn S.M, Parsons C.S, Yang M, Malhotra A.K. Acute large bowel pseudoobstruction due to atrophic visceral myopathy: a case report. *Int J Surg Case Rep* 2017;33:79.
- [5] Ross S.W, Oommen B, Wormer B.A, Walters A.L, Augenstein V.A, Heniford B.T, Sing R.F, Christmas A.B. Acute colonic pseudoobstruction: defining the epidemiology, treatment, and adverse outcomes of Ogilvie's syndrome. *Am Surg* 2016;82:102–11.
- [6] Valle R.G, Godoy F.L. Neostigmine for acute colonic pseudoobstruction: a metaanalysis. *Ann Med Surg (Lond)* 2014;3:60–4.
- [7] Adeyanju M.A, Bello A.O. Acute megacolon (acute colonic pseudo-obstruction)- a case report. *J GastroenterolHepatol Res* 2013;2:485–8.

