

ISSN 2580-4936

Health Notions

Published by: Humanistic Network for Science and Technology



<http://heanoti.com/index.php/hn>

Volume 6 Number 8

August 2022



[HOME](#) [ABOUT](#) [LOGIN](#) [REGISTER](#) [SEARCH](#) [CURRENT](#) [ARCHIVES](#) [ANNOUNCEMENTS](#) [ARTICLE TEMPLATE](#) [INDEXING](#) [STATISTICS](#)

[Home](#) > [About the Journal](#) > [Editorial Team](#)

EDITORIAL TEAM

CHIEF EDITOR (VALID FROM JANUARY 1, 2020)

Prof. Dr. Heru Santoso Wahito NUGROHO, Poltekkes Kemenkes Surabaya (Health Polytechnic of Surabaya), Indonesia

EDITORS (VALID FROM JANUARY 1, 2020)

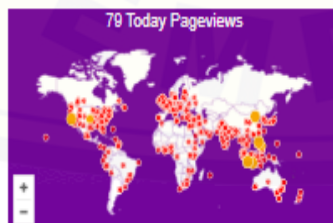Joel Rey U. ACDB, Department of Nursing, Visayas State University, Philippines
Dr. Sahrir SILLEHU, Department of Public Health, STIKes (College of Health Science) "Maluku Husada", Indonesia
Tanko Titus AUTA, Department of Nursing, Niger State Ministry of Health, Minna, Nigeria
Wiwin MARTININGSIH, Poltekkes Kemenkes Malang (Health Polytechnic of Malang), Indonesia
Somsak THOJAMPA, School of Nursing, Naresuan University, Thailand
Dr. Hadi PRAYITNO, Department of Public Health, Universitas Jember, Indonesia
Dr. Mfuh Anita Y. LUKONG, Department of Nursing Science, Faculty of Allied Health Sciences, College of Health Sciences, Ahmadu Bello University, Nigeria
Victoria KALUSOPA, School of Nursing, University of Zambia, Zambia
Sanglar POLNOK, Faculty of Nursing, Naresuan University, Thailand
Zhanibek YESSIMBEKOV, Food Engineering Department, Shakarim State University, Kazakhstan

ADMINISTRATOR (VALIF FROM JANUARY 1, 2020)

Suparji SUPARJI, Poltekkes Kemenkes Surabaya, Indonesia

"HEALTH NOTIONS" ISSN: 2580-4936 (online version only), published by Humanistic Network for Science and Technology

Cemara street 25, 001/002, Dare, Ds./Kec. Sukorejo, Ponorogo, East Java, Indonesia, 63453



USER

Username
Password
 Remember me

INFORMATION

- [For Readers](#)
- [For Authors](#)
- [For Librarians](#)

JOURNAL CONTENT

Search
Search Scope

- Browse
- [By Issue](#)
 - [By Author](#)
 - [By Title](#)
 - [Other Journals](#)



HEALTH NOTIONS
Health Notions
ISSN 2580-4936
Published by
Humanistic Network for Science and Technology

HOME ABOUT LOGIN REGISTER SEARCH CURRENT ARCHIVES ANNOUNCEMENTS ARTICLE TEMPLATE INDEXING STATISTICS

Home > Archives > Vol 6, No 8 (2022)

VOL 6, NO 8 (2022)

AUGUST

DOI: <https://doi.org/10.33846/hn608>

TABLE OF CONTENTS

ORIGINAL RESEARCH

Uncivilized Sexual Behavior Becomes Homosexual in Pendhalungan Adolescents in Jember Regency Using Miles Huberman's Analysis <i>Erdi Istiaji, Suryanto Suryanto, Andik Matulesy</i>	PDF 357-361
The Addition of SNAGS is Faster to Reduce Pain and Disability Comparing with Conventional Therapy Only among HNP Lumbar Grade I and II <i>Asrul Sani, Susy Purnawati, Sugijanto Sugijanto, DPG Purwa Samatra, IPG Adiatmika, IG Ayu Widiarti</i>	PDF 362-367
The Infulence of Various Food Intake on Body Fat Distribution among Young Healthy Population <i>Dwi Prijatmoko, Sulistiyani Sulistiyani, Dyah Setyorini, Hestieyanini Hadnyanawati, Elyda Akhya Afida Misrohmasari, Anisa Nur Syabila</i>	PDF 368-372
Effectiveness of Cassava Leaves Extract (<i>Manihot esculenta</i> Crantz) on the Number of Osteoblast and Osteoclast of Periodontitis Rat Model <i>Amandia Dewi Permana Shita, Zahara Meilawaty, Agustin Wulan Suci Dharmayanti, Amelia Nur Ilahi, Octaviana Putri Puspita Sari</i>	PDF 373-381
Relationship of Dental Caries with Quality of Life in Early Childhood <i>Ismalayani Ismalayani</i>	PDF 382-385

LITERATURE REVIEW

The Knowledge and Attitude of Nurses as an Efforts to Prevent Covid-19 <i>Solihuddin Harahap, Sri Hernawati Sirait, Lestari Lestari, Nita Andriani Lubis</i>	PDF 386-392
--	----------------

"HEALTH NOTIONS" ISSN: 2580-4936 (online version only), published by Humanistic Network for Science and Technology

Cemara street 25, 001/002, Dare, Ds./Kec. Sukorejo, Ponorogo, East Java, Indonesia, 63453

81 Today Pageviews



Visit
STATISTICS

USER

Username
Password
 Remember me

INFORMATION

- > For Readers
- > For Authors
- > For Librarians

JOURNAL CONTENT

Search
Search Scope

Browse

- > By Issue
- > By Author
- > By Title
- > Other Journals

DOI: <http://dx.doi.org/10.33846/hn60804>
<http://heanoti.com/index.php/hn>



RESEARCH ARTICLE

URL of this article: <http://heanoti.com/index.php/hn/article/view/hn60804>

Effectiveness of Cassava Leaves Extract (*Manihot esculenta* Crantz) on the Number of Osteoblast and Osteoclast of Periodontitis Rat Model

Amandia Dewi Permana Shita^{1(CA)}, Zahara Meilawaty², Agustin Wulan Suci Dharmayanti³, Amelia Nur Ilahi⁴, Octaviana Putri Puspita Sari⁵

^{1(CA)}Department of Biomedic, Faculty of Dentistry, Universitas Jember, Indonesia; shita.drg.fkg@unej.ac.id (Corresponding Author)

²Department of Biomedic, Faculty of Dentistry, Universitas Jember, Indonesia; zahara.fkg@unej.ac.id

³Department of Biomedic, Faculty of Dentistry, Universitas Jember, Indonesia; agustinwulan.fkg@unej.ac.id

⁴Faculty of Dentistry, Universitas Jember, Indonesia; amelianurilahi01@gmail.com

⁵Faculty of Dentistry, Universitas Jember, Indonesia; octavianaputripuspitasari@gmail.com

ABSTRACT

Periodontitis is a disease of periodontal tissue, one of which is caused by *Porphyromonas gingivalis* (*P. gingivalis*). *P. gingivalis* causes alveolar bone destruction by triggering macrophages and PMNs to release proinflammatory cytokines. Osteoblasts and osteoclasts play a role in alveolar bone remodeling. Decreased osteoblasts and increased osteoclasts resulted in the inhibited remodeling process. Periodontitis can be slowed down with cassava leaves. The purpose of this study was to examine the effectiveness of cassava leaves on the number of osteoblasts and osteoclasts in a rat model of periodontitis. This research is an experimental laboratory with a post-test-only control group design. The samples were male Wistar rats which were divided into (1) control (K) and (2) treatment induced by *P. gingivalis*. the treatment group was divided into aquadest (P1), metronidazole (P2), and cassava leaves (P3). Euthanasia was performed for the preparation of histopathological preparations with Hematoxylin Eosin (HE) staining. Observations with a microscope magnification 400x. The results of the calculation of the number of osteoblasts and osteoclasts between groups of cassava leaves and metronidazole were almost the same, so it was said that cassava leaves were effective in increasing the number of osteoblasts and reducing the number of osteoclasts in a rat model of periodontitis.

Keywords: osteoblasts; osteoclast; periodontitis; metronidazole; cassava leaves

INTRODUCTION

Background

Periodontal disease is the most common oral disease experienced by humans in the world⁽¹⁾. Periodontal disease affects about 20-50% of the population worldwide⁽²⁾. According to Riskesdas data in 2018, the percentage of periodontitis cases in Indonesia is 74.1%⁽³⁾. Periodontitis is an inflammatory disease of the supporting tissues of the teeth caused by the accumulation of subgingival plaque and certain periodontal pathogenic bacteria⁽⁴⁾. One of the pathogenic bacteria that causes periodontitis is *Porphyromonas gingivalis* (*P. gingivalis*)⁽⁵⁾. *P. gingivalis* is a Gram-negative anaerobic bacterium that has many virulence factors, namely fimbriae, lipopolysaccharide (LPS), capsules, lipoteichoic acid, proteases, ceramides, hemagglutinins, outer membrane vesicles, capsular antigens, and hemolysins⁽⁶⁻⁹⁾. *P. gingivalis* virulence factors that have the most role in inducing periodontitis are fimbriae, gingipain, and LPS⁽¹⁰⁻¹²⁾. This virulence factor is used to evade the immune response and invade periodontal tissue by stimulating the release of proinflammatory cytokines such as interleukin-1 (IL-1), IL-6, tumor necrosis factor- α (TNF- α), and the eicosanoids, namely prostaglandins (PGE2). Prostaglandins and proinflammatory cytokines destroy the periodontal tissue by stimulating the formation and increasing activity of osteoclasts and decreasing the number and activity of osteoblasts⁽¹²⁻¹⁴⁾. The proinflammatory cytokines that are formed can stimulate osteoblasts to increase the production of Receptor Activator of Nuclear Factor κ B-Ligand (RANKL) and decrease the production of Osteoprotegerin (OPG). OPG functions to bind to RANKL so that when OPG production

decreases, RANKL easily binds to (Receptor Activator of Nuclear Factor K β) RANK on osteoclast precursors. This can lead to a decrease in the number of osteoblasts and the formation and activation of osteoclasts resulting in bone damage^(15,16).

Osteoblasts are cells that function to form, secrete components of the bone matrix and play an important role in the process of alveolar bone remodeling. Osteoblasts contain the enzyme alkaline phosphatase which indicates that osteoblasts form a layer of cells above the bone surface that functions to protect against bone resorption by synthesizing and mediating osteoid mineralization. Osteoid is a bone matrix that has not been calcified, is newly formed, and does not contain minerals, but not long after deposition occurs, osteoid will immediately experience mineralization and become a new bone^(16,17). Osteoclasts are very large, multinucleated motile cells located in the superficial lacunae (lacunae howship) of the alveolar bone surface and play a role in matrix resorption during growth and bone remodeling⁽¹⁵⁾. Bone remodeling occurs in 5 stages, namely activation, resorption by osteoclasts, reversal, formation by osteoblasts, and terminations that occur for \pm 120-200 days in cortical and trabecular bone⁽¹⁸⁾.

Continuous inflammation of course must be prevented using the right drug to minimize the occurrence of alveolar bone damage. The presence of bone formation in periodontal disease affects the outcome of treatment. One of the drugs used for the treatment of periodontitis is metronidazole. Metronidazole is a drug that can effectively inhibit nucleic acid DNA synthesis in bacteria⁽¹⁹⁾. However, long-term use of metronidazole can cause mild to moderate side effects such as dry mouth, headache, nausea, metallic taste in the mouth, abdominal pain, diarrhea, stomatitis, and neutropenia⁽²⁰⁻²²⁾. In addition, the use of antibiotics with doses that are not by therapeutic guidelines can lead to resistance so their effectiveness in treating infections decreases⁽²³⁻²⁶⁾. So it requires alternative materials that have fewer side effects, one of which is derived from natural ingredients. Natural ingredients are known to minimize the side effects caused by the use of chemical drugs⁽²⁷⁾. One of these natural ingredients can be obtained through the cassava plant.

Cassava is a plant that can grow throughout the year in the tropics and has high adaptability to conditions in various soils. The parts of the cassava plant such as tubers, leaves, and stems are known to have many benefits in various food and non-food industries, especially the cassava leaves which are widely used as herbal medicines⁽²⁹⁾. The content contained in cassava leaves are water, phosphorus, calcium, carbohydrates, vitamin C, fat, protein, vitamin B1, iron, flavonoids, saponins, tannins, and triterpenoids⁽³⁰⁾. Cassava leaves have been reported to have anti-inflammatory, antioxidant, antiallergic, antidiabetic, antibacterial, antiviral, and anticancer activities⁽³¹⁾. The content of flavonoids in cassava leaves can suppress inflammation by blocking the cyclooxygenase (COX) and lipoxygenase cycles. In addition, flavonoids contain quercetin which can stimulate osteoblast differentiation. Saponins are also known to have an anti-inflammatory effect that is almost the same as flavonoids, namely by inhibiting the activation of the prostaglandin pathway, but have no effect on its synthesis and are known to reduce the duration of the inflammatory phase^(32,33). Apart from flavonoids and saponins, cassava leaf content such as tannins, triterpenoids, and vitamin C also have anti-inflammatory and antibacterial effects^(32,34).

Based on previous research, the dose of cassava leaf extract (*Manihot esculenta* Crantz) works effectively as an anti-inflammatory in reducing the peripheral leukocyte profile of a mouse model of ovarian dysfunction and periodontitis and is effective in inhibiting the growth of *P. gingivalis* bacteria is 179.2 mg/kg BB⁽³⁵⁾. Until now, there has been no research on the effectiveness of cassava leaf extract (*Manihot esculenta* Crantz) on the number of osteoblasts and osteoclasts in the alveolar bone of periodontitis rats. Therefore, the authors wanted to conduct a study on the effectiveness of cassava leaf extract (*Manihot esculenta* Crantz) on the number of osteoblasts and the number of osteoclasts in the alveolar bone of periodontitis rats induced by *P. gingivalis*.

Purpose

The purpose of this study was to examine the effectiveness of cassava leaf extract (*Manihot esculenta* Crantz) on the number of osteoblasts and osteoclasts in the alveolar bone of *P. gingivalis*-induced periodontitis rats.

METHODS

This research had been approved by the Ethics Committee, Faculty of Dentistry, Gadjah Mada University with letter number 0017/KKEP/FKG-UGM/EC/2022 and letter number 0024/KKEP/FKG-UGM/EC/2022. This type of research was an experimental laboratory with a post-test-only control group design. The research population was male Wistar (*Rattus norvegicus*) rats, 2-3 months old with a body weight of \pm 200 grams, healthy rats characterized by active movement responses and no defects.

Identification of cassava plants at the Jember State Polytechnic Plant Laboratory. Cassava leaf extract was made by the maceration method. The cassava leaves (*Manihot esculenta* Crantz) used came from the Kreongan area, Jember Regency. The cassava leaves that are picked are the 5th leaf to avoid high cyanide levels in leaves

that are too young⁽³²⁾. The cassava leaves are washed, then cut into small pieces and dried by placing the cassava leaves in a place at room temperature that is not exposed to direct sunlight during this time. ± 2 days. and dried using an oven at 40°C for 24 hours. After that, the dried cassava leaves were weighed then the cassava leaves were mashed and sieved using an 80 mesh sieve to become fine powders, the powder was macerated with 96% ethanol with a simplicia: solvent ratio of 1: 6 for 3 days and stirred every hour. 24 hours. Next, the solution was concentrated with a rotary evaporator at a temperature of 50°C and 90rpm so that it became cassava leaf extract (*Manihot esculenta Crantz*) at a dose of 179.2 mg/kg BB^(36,37). Experimental animals that have complied with the research criteria will be divided into 2 groups, namely the control group and the treatment group. Control group (K1). Namely, mice that were not treated at all. The treatment group (P) was a group of rats induced by *P. gingivalis* bacteria, consisting of 15 rats, then divided into 3 subgroups, namely the treatment group was given aquadest (P1), the treatment group was given metronidazole (P2), the treatment group was given cassava leaf extract (P2). P3). The treatment group was induced by *P. gingivalis* bacteria in the buccal and lingual gingival sulcus of the lower left first molar with a dose of 0.05 ml each and given once every 3 days for 14 days using a tuberculin syringe with a needle size of 30 gauge. After induction of *P. gingivalis*, clinical and radiographic examinations were performed to see signs of periodontitis after induction. On clinical examination found signs of swelling and redness of the gingiva (Figure 1). The radiographic examination revealed a radiolucent appearance on the crest of the alveolar bone which indicated that alveolar bone resorption had occurred in the *P. gingivalis*-induced rat group (Figure 2). After the rats had periodontitis, the treatment group was given 2 ml of aquadest (P1), the treatment group was given metronidazole at a dose of 2.25 mg/kg BB (P2), the treatment group was given cassava leaf extract at a dose of 179.2 mg/kg BB (P3). Give 2 ml every 2 times a day (every 8.00 and 20.00) for 1 week orally using a gastric probe based on the normal volume of the rat's stomach, which is 3-5 ml. Each group will be euthanized on the 29th or 8th day after treatment and the lower jaws of the rats are taken. After that, the lower jaws of the rats were fixed with a formalin buffer solution. Decalcification using 10% formic acid solution for 14 days with daily vibration, then cutting the tissue buccolingual and making histological preparations with Hematoxylin Eosin (HE) staining. Observation and counting of the number of osteoblasts and osteoclasts were carried out using a light microscope with 40x magnification in three buccal and lingual visual fields (Figure 3). Then the data analysis was carried out with the one-way ANOVA test.

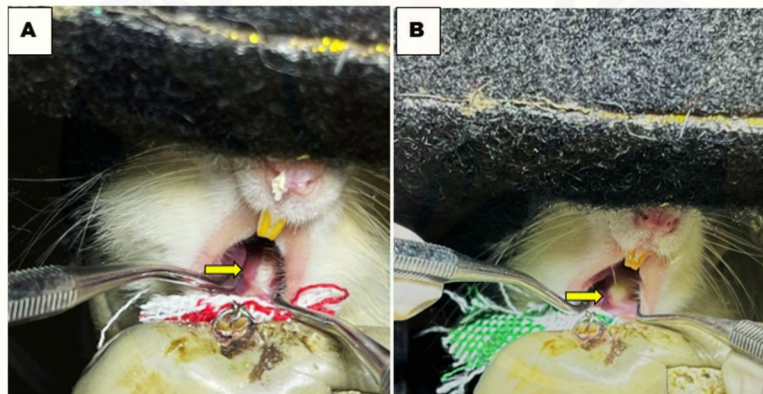


Figure 1. Clinical features of rats with periodontitis. A) The yellow arrow indicates the clinical picture of gingival swelling in rats. B) The yellow arrow indicates the clinical picture in the form of redness in rats

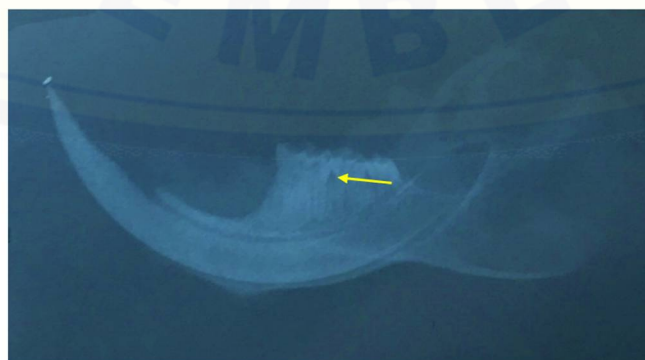

Figure 2. The radiographic appearance of periodontal tissue in *P. gingivalis*-induced rat group. The yellow arrow indicates a radiolucent appearance at the crest of the alveolar bone.

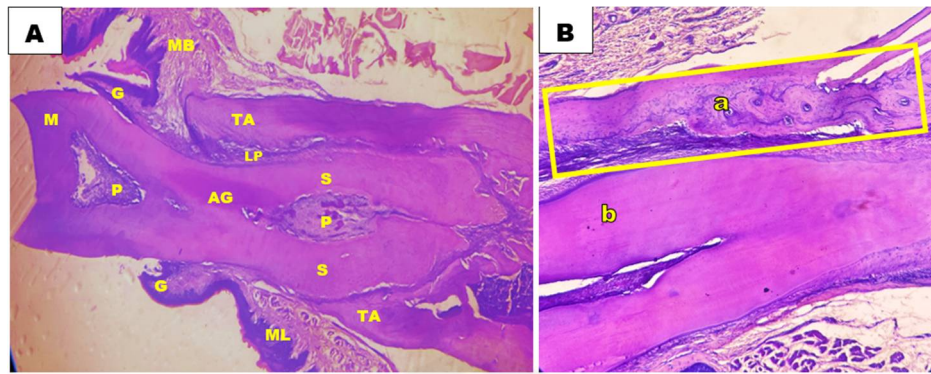


Figure 3. Histology of teeth and periodontal tissues with HE staining. A) Histology of teeth and periodontal tissues at 40x magnification. M) Tooth crown, G) Gingiva, P) Pulp, AG) Tooth root, ML) Lingual mucosa, MB) Buccal mucosa, TA) Alveolar bone, LP) Periodontal ligament, S) Cementum. B) Histology of teeth and periodontal tissues with 100x magnification. TA) Alveolar bone image (part observed), G) Teeth

RESULTS

Osteoblasts are cells involved in the process of bone remodeling. The results showed that the osteoblasts in the control group (Figure 4) appeared to be a row of flat or cube-shaped cells with one cell nucleus colored blue or dark purple and having a basophilic cytoplasm attached to the alveolar bone^(37,38). The results also showed that the osteoblasts in the treatment group (Figure 4) appeared in a row of osteoblasts attached to the alveolar bone in the resorption area, which indicates the formation stage of the bone remodeling process⁽¹⁸⁾. The results of the calculation of the number of osteoblasts showed that the highest number was seen in the treatment group that was given metronidazole, while the lowest number was seen in the treatment group that was given aquadest (Figure 4). Osteoclasts are very large motile cells with multiple nuclei located in shallow lacunae (howship lacunae) of the alveolar bone surface and play a role in matrix resorption during growth and bone remodeling^(5,15). The results of the calculation of the number of osteoclasts showed that the highest number was seen in the control group, while the lowest number was seen in the treatment group that was given cassava leaf extract (Figure 5).

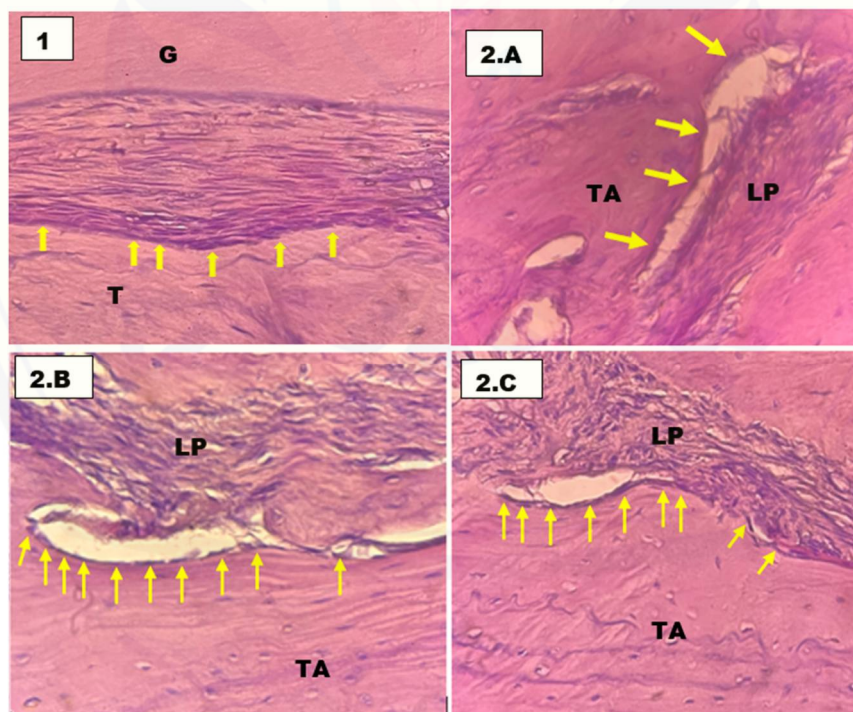


Figure 4. Histological appearance of osteoblasts with HE staining at 400x magnification. 1) histological picture in the control group (K1). 2) Histological description of osteoblasts in the alveolar bone resorption section of the rat group 2. A) treatment group that was given aquadest (P1); 2. B) the treatment group was given metronidazole (P2); 2. C) the treatment group was given cassava leaf extract (P3). TA) alveolar bone, LP) periodontal ligament; G) teeth. Yellow arrows indicate osteoblasts

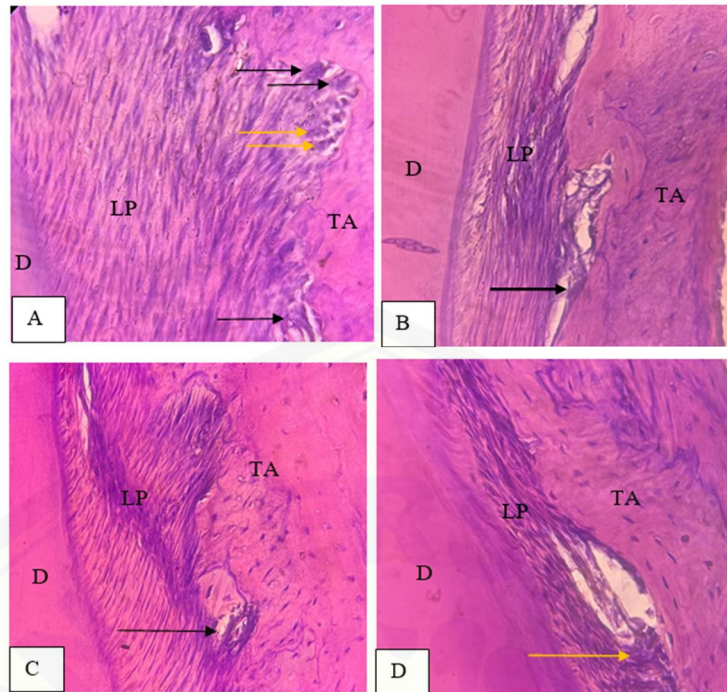


Figure 5. Histology of osteoclasts with HE staining at 400X magnification. A) Control. B) Treatment 1 was induced by *P. gingivalis* and given aquades. C) Treatment 2 with *P. gingivalis* induced and cassava leaf extract therapy. D) Treatment 3 was induced by *P. gingivalis* and given Metronidazole. TA (Alveolar Bone), LP (Periodontal Ligament), D (Dentin). Black arrows indicate osteoclasts and yellow indicate osteoblasts.

The research data obtained were tested for normality using the Shapiro-Wilk and homogeneity test using the Levene test. The results show that all data are normally distributed and homogeneous with a significant value >0.05 . Subsequently, a parametric test was performed using One-way ANOVA to determine the differences between all groups. The results of the One-way ANOVA test are presented in Table 1.

Table 1. The average number of osteoblasts and osteoclasts

Grup	N	Osteoblast		Osteoclast	
		X±SD	p	X±SD	p
Control group (K1)	5	17.0 ± 2.6	0.000	3.04 ± 2.0	0.446
Aquadest group (P1)	5	12.4 ± 1.5		3.00 ± 2.1	
Metronidazole group (P2)	5	21.5 ± 2.2		2.00 ± 2.0	
Cassava leaf group (P3)	5	19.9 ± 0.9		1.60 ± 1.5	

Table 2. LSD test results in the number of rat alveolar bone osteoblasts

Group	control (K1)	<i>P. gingivalis</i> + aquadest (P1)	<i>P. gingivalis</i> + metronidazole (P2)	<i>P. gingivalis</i> + extract (P3)
Control group (K1)	-	0.001*	0.002*	0.027*
<i>P. gingivalis</i> + aquadest (P1)		-	0.00*	0.00*
<i>P. gingivalis</i> + metronidazole (P2)			-	0.198
<i>P. gingivalis</i> + cassava leaf (P3)				-

Table 1 shows that the significance value (Sig) <0.05 , which is 0.000, explains that there is a difference in the number of osteoblasts and there is no difference in the number of osteoclasts with a significance value of 0.446. The next test, namely Least Significant Difference (LSD) to determine the significant difference in the number of osteoblasts between groups, is presented in Table 2 below. Table 2 shows the difference in the number of osteoblasts in all groups except for the treatment group given metronidazole and the treatment group given cassava leaf extract did not have a significant difference ($p=0.198$).

DISCUSSION

The results of the number of calculations that have been carried out show that the number of osteoblasts in the treatment group given metronidazole and the group given cassava leaf extract showed that the number of osteoblasts was higher when compared to the treatment group given aquadest and the control group. This is evidenced by the results of the LSD test which show a significant difference.

The results of the LSD test showed that the treatment group that was given aquadest was significantly different from the control group (normal). This indicates that the treatment group that was given aquadest was not able to increase the number of osteoblasts. The decrease in the number of osteoblasts was seen by comparing the average of the treatment group that was given aquadest of 12.4 with the control group of 17.0. This shows that the decrease in the number of osteoblasts is quite large. This is because PGE₂, IL-1, and TNF- which are formed during inflammation play a role in increased apoptosis of osteoblasts and their precursors so that they can reduce osteoblast production. PGE₂ will induce osteoblasts to produce RANKL and decrease OPG production which causes RANKL to bind to RANK, causing osteoclast formation and a decrease in the number of osteoblasts^(15,39). Giving aquadest is neutral and does not give any effect as antibacterial or anti-inflammatory so when given treatment in the form of induction of *P. gingivalis* bacteria to experience periodontitis, the treatment group was given aquadest experienced a decrease in the number of osteoblasts because there was no therapeutic effect in treating periodontitis in aquadest⁽⁴⁰⁾.

The treatment group that was given metronidazole was significantly different from the control group and the treatment group that was given aquadest. This indicates that the treatment group given Metronidazole can increase the number of osteoblasts compared to the treatment group given Aquadest. This increase in the number of osteoblasts can be seen by comparing the average number of osteoblasts in the treatment group that was given aquadest as much as 12.4, the control group as much as 17.0, and the treatment group given metronidazole as much as 21.5. This indicates a significant increase in the number of osteoblasts. This is because metronidazole has bactericidal properties that are effective in killing anaerobic bacteria that usually dominate in periodontitis by diffusion into the organism, inhibiting protein synthesis, and interacting with bacterial DNA which causes loss of helical DNA structure and damage to DNA strands in bacteria, resulting in inhibition of DNA synthesis. which causes the death of bacteria. This bacterial death helps prevent excess bacterial colonization so that a more severe infection does not occur and that the inflammatory phase occurs in a shorter time⁽⁴¹⁻⁴³⁾.

The results of the calculation of the average number of osteoblasts in the treatment group given cassava leaf extract showed significantly different results from the control group and the aquadest treatment group. This increase in the number of osteoblasts can be seen by comparing the average number of osteoblasts in the treatment group that was given aquadest as much as 12.4, the control group as much as 17.0, and the treatment group given cassava leaf extract as much as 19.9. This shows that in the treatment group given cassava leaf extract there was also a significant increase in the number of osteoblasts, so it can be said that the treatment group given cassava leaf extract was able to increase the number of osteoblasts. This is supported by the results of the LSD test in the treatment group given cassava leaf extract which did not differ significantly from the treatment group given metronidazole. So it can be said that cassava leaf extract has an effect that is almost equivalent to metronidazole. Metronidazole is an antibacterial drug that is the drug of choice for periodontal disease by inhibiting the DNA synthesis of nucleic acids of bacteria that cause periodontitis^(22,44,45). Meanwhile, the group of rats given cassava leaf extract contained active compounds, namely flavonoids, triterpenoids, saponins, and tannins⁽³²⁾.

The content of cassava leaves that act as antibacterial, namely flavonoids, saponins, tannins, and triterpenoids which are thought to be able to reduce the number of periodontal bacteria in the gingival sulcus so that the inflammation that occurs can last a shorter time. Meanwhile, flavonoids, saponins, and triterpenoids can also act as anti-inflammatory by inhibiting the action of arachidonic acid through the cyclooxygenase (COX) enzyme so that it can inhibit the release of pro-inflammatory mediators such as IL-1, IL-6, TNF- α , and PGE₂. PGE₂ can induce osteoblast cells to produce RANKL and inhibit OPG production. OPG binds to RANKL to block the binding of RANKL to RANK. The inhibitory activity of PGE₂ causes a decrease in RANKL expression, a decrease in the number of osteoclasts, an increase in OPG, and an increase in the growth and differentiation of osteoblasts increasing the formation of alveolar bone. This mechanism increases the number of osteoblast cells^(15,46).

The results showed that the untreated group of rats had the highest number of osteoclasts. This is probably due to the mouse model experiencing stress which can cause an increase in the number of osteoclasts. Stress may trigger alveolar bone resorption which is characterized by an increase in the number of osteoclasts. Under stress conditions, there will be stimulation of the sympathetic nervous system as the body's response to stressors. The sympathetic nervous system is thought to be able to activate the strengthening of hormones in the form of large amounts of catecholamine release. The increase in catecholamines is thought to trigger macrophages and other cells to produce proinflammatory cytokines⁽⁴⁷⁾. These proinflammatory cytokines will increase the expression of Receptor Activator for Nuclear Factor-K β Ligand (RANKL) and decrease Osteoprotegerin (OPG) as an antagonist of RANKL. Macrophage-Colony Stimulating Factor (M-CSF), IL-1, and RANKL will cause osteoclast precursors

to differentiate and undergo fusion and then become multinuclear osteoclasts which can activate osteoclastogenesis so that the number of osteoclasts increases^(5,15).

The results also showed that the cassava leaf extract group (*Manihot esculenta Crantz*) had the lowest number of osteoclasts compared to other groups. The decrease in the number of osteoclasts is thought to be due to the active content contained in cassava leaves which can inhibit osteoclastogenesis. The reduced osteoclasts are influenced by the decrease in the number of bacteria and the inhibition of the accompanying inflammatory response. The active ingredients in cassava leaves (*Manihot esculenta Crantz*) such as flavonoids, saponins, triterpenoids, and tannins are known to have antibacterial and anti-inflammatory abilities that can cause a decrease in the inflammatory response to reduce the formation of osteoclasts, and their activity so that alveolar bone resorption can be reduced^(32,46,48). In the group with metronidazole induction, the mean osteoclasts were almost the same as the cassava leaf extract group. Metronidazole is an antibiotic that is the drug of choice for periodontitis. Metronidazole works by stopping the etiology of periodontitis by inhibiting the proliferation of *P. gingivalis*. In addition, the ability of Metronidazole to inhibit pro-inflammatory cytokines such as IL-1, IL-6, and IL-8 can reduce osteoclastogenesis activity. can be used as an alternative therapy for periodontal disease.

CONCLUSION

The conclusion obtained from this research is that cassava leaves extract (*Manihot Esculenta Crantz*) can increase the number of osteoblasts and decrease the number of osteoclasts in periodontitis rat model.

REFERENCES

1. Nugro Tonetti MS, Jepsen S, Jin L, Otomo-Corgel J. Impact of the global burden of periodontal diseases on health, nutrition, and wellbeing of mankind: A call for global action. *Journal of clinical periodontology*. 2017;44(5):456-462.
2. Nazir MA. Prevalence of periodontal disease, its association with systemic diseases and prevention. *International Journal of Health Sciences*. 2017;1(2):72-80.
3. Kemenkes RI. Laporan Nasional RISKESDAS 2018. Jakarta: Kemenkes RI; 2018.
4. Mesa F, Magan-Fernandez A, Castellino G, Chianetta R, Nibali L, Rizzo M. Periodontitis and Mechanisms Of Cardiometabolic Risk: Novel Insights and Future Perspectives. *Biochimica et Biophysica Acta (BBA) - Molecular Basis of Disease*. 2019;1865(2):476-484.
5. Kurniawati A, Wahyukundari MA, Astuti SD. Potensi Ekstrak Daun Ungu dalam Menurunkan Jumlah Sel Osteoklas Tikus yang Diinduksi Porphyromonas gingivalis. *Cakradonya Dental Journal*. 2020;12(2):75-82.
6. Attallah NG, Negm WA, Elekhawy E, Altwaijry N, Elmongy EI, El-Masry TA, Shoukheba YM. Antibacterial activity of Boswellia sacra Flueck. Oleoresin extract against Porphyromonas gingivalis periodontal pathogen. *Antibiotics*. 2021;10(7):859.
7. Domini FBA, Dewanti IDAR, Wulandari E. Analisis Jumlah Sel Monosit yang Mengekspresikan Tnf-A setelah dipapar Porphyromonas Gingivalis dan Tulang Ikan Kuniran (*Upeneus sulphureus*) dengan Teknik Imunositokimia. *Jurnal Kesehatan Gigi*. 2019;6(2):87-92.
8. Hajishengallis G, Diaz PI. Porphyromonas gingivalis: Immune subversion activities and role in periodontal dysbiosis. *Current oral health reports*. 2020;7(1):12-21.
9. Vishwakarma A, Verma D. Microorganisms: crucial players of smokeless tobacco for several health attributes. *Applied Microbiology and Biotechnology*. 2021;105(16):6123-6132.
10. Nunes JM, Fillis T, Page MJ, Venter C, Lancry O, Kell DB, Pretorius E. Gingipain R1 and lipopolysaccharide from Porphyromonas gingivalis have major effects on blood clot morphology and mechanics. *Frontiers in Immunology*. 2020;11:1551.
11. Pudla M, Srisaowakarn C, Utaisincharoen P. NLRP12 negatively modulates inducible nitric oxide synthase (iNOS) expression and tumor necrosis factor- α production in Porphyromonas gingivalis LPS-treated mouse macrophage cell line (RAW264. 7). *Inflammation Research*. 2019;68(10):841-844.
12. Putri CF, Bachtiar EW. *Porphyromonas Gingivalis* dan Patogenesis Disfungsi Kognitif: Analisis Peran Sitokin Neuroinflamasi. *Cakradonya Dent J*. 2020;12(1):15-23.
13. Ayu KV. Efek Induksi LPS Terhadap Jumlah Osteoblas Pada Resorpsi Tulang Alveolar Tikus Putih Jantan (*Rattus norvegicus*) Galur Sprague Dawley. *Interdental Jurnal Kedokteran Gigi*. 2018;14(1):13-17.
14. Jia L, Han N, Du J, Guo L, Luo Z, Liu Y. Pathogenesis of important virulence factors of Porphyromonas gingivalis via toll-like receptors. *Frontiers in Cellular and Infection Microbiology*. 2019;9:262.
15. Fatimatuzzahro N, Ermawati T, Prasetya RC, Destianingrum PQ. Efek pemberian gel ekstrak biji kopi robusta (*Coffea canephora*) terhadap jumlah osteoblas dan osteoklas pada tulang alveolar tikus periodontitis. *Padjadjaran Journal of Dental Researchers and Students*. 2020;4(2):128-133.

16. Astuti LA, Masriadi M, Arifin FA, Aslan S, Hikmah N. Perbedaan Densitas Tulang Alveolar Sebelum dan Sesudah Kuretase Menggunakan Software ImageJ Pada Periodontitis Kronis. *Sinnun Maxillofacial Journal*. 2021;3(01):1-12.
17. Majdina S, Mulawarmanti D, Rizka Y. Efektifitas Kombinasi Terapi Oksigen Hiperbarik dan Gel Teripang Emas (*Stichopus hermanii*) terhadap Peningkatan Jumlah Osteoblas pada Tikus Diabetes Melitus yang Diinduksi Bakteri *Porphyromonas gingivalis*. *Jurnal kedokteran gigi*. 2016;10(1):31-41.
18. Kenkre JS, Bassett JHD. The bone remodelling cycle. *Annals of clinical biochemistry*. 2018;55(3):308-327.
19. Carranza FA, Newman FG, Takei HH. Carranza's Clinical Periodontology. Edisi 13. Philadelphia: WB Saunders; 2018.
20. Ceruelos A, Hernández LC, Romero-Quezada JC, Ruvalcaba Ledezma, And L. López Contreras. Therapeutic Uses Of Metronidazole And Its Side Effects: An Update. *European Review For Medical And Pharmacological Sciences*. 2019;23:397-401.
21. Heta S, Robo I. The Side Effects of The Most Commonly Used Group Of Antibiotics In Periodontal Treatments. *Medical sciences Journal*. 2018;6(6):1-6.
22. Tedjasulaksana R. Metronidasol Sebagai Salah Satu Obat Pilihan Untuk Periodontitis Marginalis. *Jurnal Kesehatan Gigi*. 2016;4(1):19-23.
23. Azaripour A, Dittrich S, Van Noorden CJ, Willershausen B. Efficacy of photodynamic therapy as adjunct treatment of chronic periodontitis: a systematic review and meta-analysis. *Lasers in Medical Science*. 2018;33(2):407-423.
24. Gultom R, Khairani. Evaluasi Kepatuhan Pasien Anak Penderita Diare Terhadap Penggunaan Antibiotik Di Rumah Sakit Umum (RSU) Karya Bakti Ujung Bandar Rantauprapat. *Jurnal Ilmiah Farmasi Imelda*. 2021;4(2):37-42.
25. Hasyul SFP, Nuari DA, Anggraini S, Aditya A, Lisni I. Analisis Drug-Related Problems Penggunaan Antibiotik Fluorokuinolon di Salah Satu Puskesmas Kabupaten Garut. *Jurnal Ilmiah Farmako Bahari*. 2020;11(2):137-144.
26. Jamiati HA, Sari M. Evaluasi Peresepan Antibiotik Pada Pasien Rawat Jalan di Puskesmas Dabun Gelang Kabupaten Gayo Lues. *Jurnal Dunia Farmasi*. 2019;3(3):115-122.
27. Ahmad I. Pemanfaatan Limbah Cangkang Kerang Darah (*Anadara granosa*) Sebagai Bahan Abrasif Dalam Pasta Gigi. *Jurnal Galung Tropika*. 2017;6(1):49-59.
28. Womsiwor OOO, Nurmaini, Zikri A, Hendra, Amrizal, Yudistira, Yuliana FB. Design and Development of Horizontal Types of Cupping and Cash Washing Machines. *Journal Of Applied Agricultural Science and Technology*. 2018;2(2):11-19.
29. Akbar AK, Febriani AK. Uji kompresibilitas granul pati singkong dengan metode granulasi basah. *Jurnal Ilmiah JOPHUS: Journal Of Pharmacy UMUS*. 2019;1(01):7-11.
30. Muthmainna B, Nilasari A. Uji Aktivitas Antimikroba Herba Daun Singkong (*Manihot utilissima Pohl*) Terhadap Pertumbuhan Bakteri *Staphylococcus aureus*. *Jurnal Ilmiah Kesehatan Diagnosis*. 2018;12(6):614-616.
31. Solikhah R, Purwantoyo E, Rudyatmi E. Aktivitas Antioksidan dan Kadar Klorofil Kultivar Singkong di Daerah Wonosobo. *Life Science Journal*. 2019;8(1):86-95.
32. Meilawaty Z, Shita ADP, Kuncaraningtyas PL, Dharmayanti AWS, Hamzah Z. Potensi ekstrak daun singkong (*Manihot esculenta Crantz*) terhadap ekspresi MMP-8 fibroblas gingiva pada model tikus dengan disfungsi ovarium dan periodontitis. *Jurnal Kedokteran Gigi Universitas Padjadjaran*. 2020;32(2):105-112.
33. Sa'diyah JS, Septiana DA, Farih NN, Ningsih JR. Pengaruh Gel Ekstrak Daun Binahong (*Anredera Cordifolia*) 5% Terhadap Peningkatan Osteoblas Pada Proses Penyembuhan Luka Pasca Pencabutan Gigi Tikus Strain Wistar. *Jurnal Kedokteran Gigi Universitas Padjadjaran*. 2020;32(1):9-15.
34. Wenas DM, Aliya LS, Janah NU. Aktivitas Antiinflamasi Ekstrak Etanol Daun Kopi Arabika (*Coffea arabica L.*) Pada Edema Tikus. *Buletin Penelitian Tanaman Rempah Dan Obat*. 2020;31(2):75-84.
35. Sari LM, Meilawaty Z, Astuti P, Shita ADP, Dharmayanti AWS, Hamzah Z. Potensi Ekstrak Daun Singkong (*Manihot Esculenta Crantz.*) Terhadap Profil Leukosit Darah Tepi Model Tikus Disfungsi Ovarium dan Periodontitis. *Jurnal Kedokteran Gigi Universitas Padjadjaran*. 2021;33(1):44-52.
36. Shita ADP, Meilawaty Z, Rothschildi DP, Dharmayanti AWS, Hamzah Z. The potential of cassava leaves extract in gingival fibroblasts of periodontitis of rats with ovarian dysfunction. *Padjadjaran Journal of Dentistry*. 2021;33(3):226-233.
37. Koraag JR, Michael, Siagian. Efektivitas Perasan Daun Pepaya Terhadap Jumlah Osteoblas Pasca Pencabutan Gigi Pada Tikus Wistar Jantan. *Pharmacon Jurnal Ilmiah Farmasi Unsrat*. 2015;4(4):2302-2493.
38. Sardi NWA, Sukrama IDM, Satriyasa BK. Peningkatan Sel Osteoblast Mandibula Tikus Wistar Jantan Setelah Pemberian Fermentasi Teh Kombucha. *Interdental: Jurnal Kedokteran Gigi*. 2018;14(2):51-55.
39. Chen X, Wang Z, Duan N, Zhu G, Schwarz EM, Xie C. Osteoblast-osteoclast interactions. *Connective Tissue Research*. 2018;59(2):99-107.

40. Gerung WHP, Fatimawali F, Antasionasti I. Uji Aktivitas Antibakteri Ekstrak Daun Belimbing Botol (*Averrhoa Bilimbi* L.) Terhadap Pertumbuhan Bakteri *Propionibacterium acne* Penyebab Jerawat. *Pharmacon*. 2021;10(4):1087-1093.
41. Atiqah AN, Poetri AR, Niam MH. The Difference of Effectivity Between Mangosteen Peel Extract and Metronidazole on Fibroblast Proliferation. *Odonto: Dental Journal*. 2021;8(1):80-85.
42. Faizah A, Anindhita M. Curettage Treatment In Cases of Gingivitis Et Causa Plaque and Dental Calculus: Case Report. *Proceeding of the 14th University Research Colloquium 2021: Bidang Kesehatan*. Cilacap: Lembaga Penelitian dan Pengabdian Pada Masyarakat (LPPM) STIE Muhammadiyah Cilacap. 2021:1-6.
43. Rismadiani A, Poetri AR, Feranisa A. Efektivitas Ekstrak Kulit Buah Manggis Terhadap Peningkatan Jumlah Sel Fibroblas Pada Proses Penyembuhan Periodontitis Tikus Wistar (*Rattus norvegicus*). *Prosiding Konstelasi Ilmiah Mahasiswa Unissula (Kimu) 7 Universitas Islam Sultan Agung*. 2022:86-93.
44. Paliling A, Posangi J, Anindita PS. Uji Daya Hambat Ekstrak Bunga Cengkeh (*Syzygium Aromaticum*) Terhadap Bakteri *Porphyromonas gingivalis*. *Jurnal e-GiGi*. 2016;4(2):229-234.
45. Tani PG, Wowor PM, Khoman JA. Uji Daya Hambat Daging Buah Sirsak (*Annona muricata* L.) Terhadap Pertumbuhan Bakteri *Porphyromonas gingivalis*. *Pharmacon Jurnal Ilmiah Farmasi*. 2017;6(3):99-104.
46. Wahyu P, Kurniawati A, Pujiastuti P. Potentially of Purple Leaves to Increase Osteoblast Alveolar Bone Rat Induced *Porphyromonas gingivalis*. *Journal of Vocational Health Studies*. 2021;4(3):114-118.
47. Rizqi CK, Harmono H, Nugroho R. Pengaruh Lama Distres Kronis Terhadap Perubahan Jumlah Sel Osteoklas Pada Tulang Alveolar Tikus Sprague dawley. *Pustaka Kesehatan*. 2016;4(1):61-67.
48. Agidigbi TS, Kim C. Reactive Oxygen Species in Osteoclast Differentiation and Possible Pharmaceutical Targets of ROS-Mediated Osteoclast Diseases. *International Journal of Molecular Sciences*. 2019;20(14):3576.