

## Case Report: Tuberculosis with Pericardial Effusion in Children

Muhammad Ali Shodikin

Department of Microbiology, Medical Faculty, University of Jember, Jember, Indonesia

### ARTICLE INFO

#### Article history:

Received : June 16, 2021

Received in revised form :

July 14,, 2021

Accepted : August 01, 2021

#### Keywords:

Tuberculosis, Pericardial effusion,  
Pericardiocentesis

\*) Corresponding  
author:alipspd@unej.ac.id

### ABSTRACT

Tuberculosis pericardial effusion is a rare case in the developed countries. This may cause serious and deadly impact if not diagnosed and treated properly. Appropriate diagnosis and treatment of tuberculosis pericardial effusion can prevent mortality. A 14-years-old boy was admitted with tightness of breath, chest pain, and abdominal enlargement. Chest X-ray revealed heart enlargement and echocardiography showed a massive pericardial effusion. The diameter of induration of tuberculin skin test was 14 mm. This patient was diagnosed as tuberculosis pericardial effusion and showed complete recovery after paricardiocentesis and anti-tuberculosis drugs administration for 12 months. Chest X-ray in tuberculosis with pericardial effusion shows an enlarged heart. so that adequate treatment with pericardiocentesis and anti-tuberculosis drugs can completely cure this disease.

Medical and Health Science Journal

## Introduction

Tuberculosis pericardial effusion is a complication of pericarditis due to *Mycobacterium tuberculosis* infection which is one of extra-pulmonary tuberculosis. Tuberculosis is the cause of more than 50% of pericardial effusion in children in India where tuberculosis was an endemics.<sup>1</sup> Appropriate diagnosis and treatment of tuberculosis pericardial effusion can prevent mortality.<sup>2</sup> The diagnosis is obtained based on history taking, physical examination, laboratory and imaging examinations.<sup>2,3</sup> The treatments of massive tuberculosis pericardial effusion are administration of anti-tuberculosis and anti-inflammatory, and fluid evacuation by pericardiocentesis or pericardiectomy.<sup>3,4</sup> Patients with tuberculous pericarditis merit to conduct invasive pericardial procedures.<sup>5</sup> This paper reports on a case of massive tuberculosis pericardial effusion that was diagnosed appropriately and treated adequately.

## Case

The informed consent was obtained from the family of the patient. A boy, 14 years old, was taken by his parents to the emergency room with complaints of tightness of breath, chest pain, and enlarged abdomen, that had been getting worse since 2 weeks. Physical examination results showed the body weight is 40 kg, 165 cm height, 14.6 body mass index (BMI), conjunctival anemic, weak and distant heart sounds, jugular vein distension, ascites and distended abdomen. This patient had blood pressure of 100/60 mmHg, heart rate of 110 beat per minute, respiratory rate of 38 times per minute, and 37.7 °C axillary

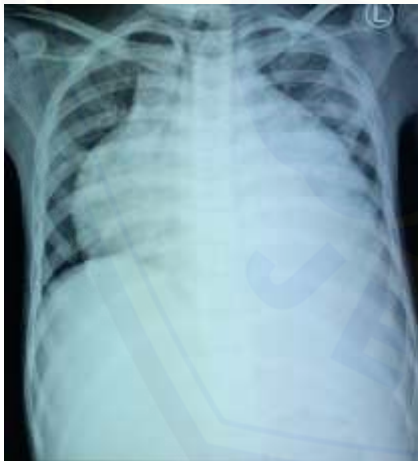temperature. Chest X-ray showed heart enlargement with cardiothorax ratio of 84% (Figure 1). Electrocardiograph showed sinus tachycardia and low-voltage QRS complex. Blood examination results were Haemoglobin 9.5 gr/dL, leucocyte 9,100/mm<sup>3</sup>, platelets 384,000/mm<sup>3</sup>, albumin 3.7 g/dL, serum creatinine 0.7 mg/dL, serum electrolyte Sodium 133 mmol/L and potassium 3.7 mmol/L. Echocardiography showed a massive pericardial effusion, with ejection fraction of 87%. Tuberculin skin test was performed and the result 3 days later showed 14 mm induration. Based on clinical finding, laboratory finding, imaging and positive tuberculin skin test, this patient was diagnosed as tuberculosis pericardial effusion, cardiac tamponade and anemia.

Anti-tuberculosis drugs of Isoniazid 300 mg, Rifampicin 600 mg, Pirazinamid 1500 mg and Ethambutol 750 mg each was given once daily. He was also given Methylprednisolone 16 mg three times daily, Pyridoxine 10 mg once daily and Furosemide 20 mg twice daily. Pericardiocentesis subxyphoid approach was performed and drain catheter was installed by cardiothoracic surgeon, removing 1200 ml of pericardial effusion fluid. Histopathological examination of effusion fluid showed haemorrhagic fluid, histiocyte macrophage cell, no visible tuberculous process and without cell malignancy. Effusion fluid culture were performed, even not in Lowenstein-Jensen medium. The result showed that there was no bacterial growth. After pericardiocentesis, chest radiograph showed cardiothorax ratio of 54% (Figure 2). Six days after pericardiocentesis, the child was getting better. There were no

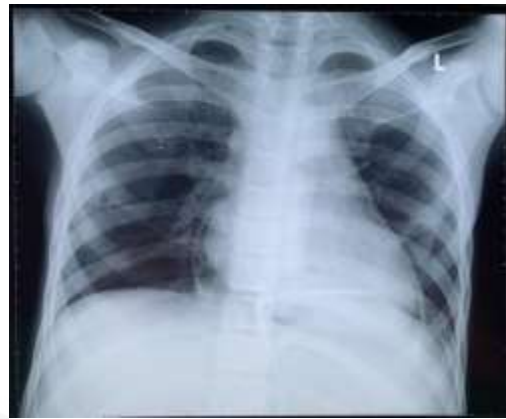
shortness of breath, ascites, and jugular vein distension anymore. Therefore, this patient was discharged. Methylprednisolone was continued for 2 weeks and was then tapered off. Anti-tuberculosis drugs intensive phase (Isoniazid, Rifampicin, Pyrazinamide and Ethambutol) was administered for 2 months, then followed by continuation phase (Isoniazid and Rifampicin) for 10 months.

The patient's condition was observed every month in pediatric ambulatory clinic. His body weight increased from 40 kg (BMI 14.6) in the first admission to 46 kg (BMI 16.5) in the 6<sup>th</sup> month of anti-tuberculosis treatment. At the end of treatment (12<sup>th</sup> month of treatment) his body weight was 50 kg and body height was 170 cm (BMI 17.3). Chest radiograph after 6 months of anti-tuberculosis treatment showed that the lungs and heart were normal, and no pericardial effusion was seen (Figure 3).

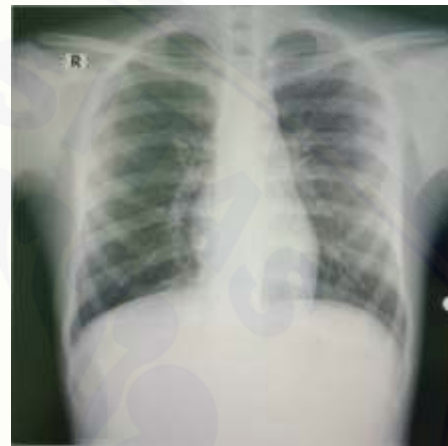Patient's chest radiograph:



**Figure 1.** In the first admission, enlarged heart was seen, cardio thorax ratio was 84%.



**Figure 2.** After pericardiocentesis, the size of the heart was reduced, cardio thorax ratio was 54%.



**Figure 3.** After 6 months of anti-tuberculosis treatment, the heart appeared normal, cardio thorax ratio was 40%.

## Discussion

Tuberculosis is not the only cause of pericarditis, however, it is the most common cause of pericarditis in developing countries.<sup>10</sup> A definitive diagnosis of tuberculous pericarditis is made if acid-fast bacilli is found in pericardial fluid or tissue. Probable diagnosis is made if at least one of the following three conditions is found: (1) pericardial effusion with confirmed TB in other organs, (2) exudative lymphocytic effusion with increased ADA level, and (3) treatment response to anti-tuberculosis drugs.<sup>5</sup> The diagnoses were also supported by the increased ADA >30 U/L in pericardial fluid, which has sensitivity of 94% and

specificity of 68% in establishing *Mycobacterium tuberculosis* as the cause of effusion.<sup>6</sup>

Tuberculosis with pericardial effusion is caused by *Mycobacterium tuberculosis* infection in the pericardium hematogenously, lymphogenously or direct spread that can occur even without starting with pulmonary tuberculosis.<sup>2,4</sup> Pericardial effusion increases the pressure of the pericardial space that disrupts ventricular filling during diastole, increases pressure of the systemic and pulmonal vein, and also inhibits blood backflow to the heart. Decreasing of ventricular filling when diastole, causing a decrease in stroke volume and cardiac output. Perfusion to vital and peripheral organs is reduced which can lead to shock and death.<sup>6</sup> Increased systemic venous pressure results in jugular vein distension, liver enlargement, ascites, and peripheral edema, whereas an increase in pulmonary venous causes pulmonary edema.<sup>7</sup> Cardiac tamponade is suspected when there is severe shortness of breath, systemic hypotension, tachycardia, weak heart sounds in auscultation and pulsus paradoxus (reduction in systolic blood pressure of more than 10 mmHg when inspiration).<sup>8</sup> Previous studies have demonstrated that reversing the lymphatic flow of bacteria from peritracheal, peribronchial, or mediastinal lymph nodes or through hematogenous spread of primary tuberculosis infection will lead to cardiac involvement.<sup>13</sup> The tuberculin skin test can suggest diagnosis of tuberculosis if after 48-72 hours there is induration of > 10 mm.<sup>9</sup> In this case, induration diameter of tuberculin skin test was 14 mm. Bacteriological examination is important in diagnosing tuberculosis, i.e detecting *Mycobacterium tuberculosis* in sputum, gastric

lavage or pericardial fluid with Ziehl Nelsen staining, cultivated in Lowenstein-Jensen medium as selective medium for cultivation and isolation of *Mycobacterium tuberculosis* or polymerase chain reaction.<sup>2</sup> In this case, *Mycobacterium tuberculosis* was not detected in pericardial fluid.

Polymerase chain reaction and cultivation in Lowenstein-Jensen medium was not conducted due to limited resources in our hospital. Histopathological examination of the pericardium is conducted if granulomatous and pericardial calcification is a definitive way of diagnosing pericardial tuberculosis.<sup>11</sup> Electrocardiographic features of massive pericardial effusion or cardiac tamponade are in the form of tachycardia and low voltage of QRS complexes.<sup>12</sup> Examination of the chest X-ray in a massive pericardial effusion patient shows globular enlarged heart (water bottle heart). Echocardiography examination can detect pericardial effusion, cardiac tamponade, pericardial thickening or constrictive pericarditis.<sup>7</sup>

Management of tuberculosis pericardial effusion includes anti-tuberculosis and anti-inflammatory drugs administration and pericardiocentesis or pericardiectomy.<sup>9</sup> According to Indonesian Pediatric Society, the administration of anti-tuberculosis for tuberculous pericarditis consists of an intensive phase of Isoniazide, Rifampicin, Pyrazinamide, Ethambutol every day for 2 months and followed by a continuation phase of Isoniazide and Rifampicin every day for 10 months.<sup>9</sup> Corticosteroids can suppress the inflammatory response and accelerate the absorption of pericardial fluid, thereby preventing pericardial constriction.<sup>7,8</sup> Pericardiocentesis is an invasive procedures to remove fluid from the pericardial space. This procedure is carried out

when there is a massive pericardial effusion and cardiac tamponade.<sup>8</sup> Pericardiectomy is performed if recurrent pericardial effusion occurs with constrictive pericarditis and drainage obstruction.<sup>8</sup>

In this case, anti-tuberculosis drugs are administered to the patient and observations are made regularly every months after discharge. Disappearance of tuberculosis pericardial effusion causes normal cardiac function so that there is no more tightness of breath, chest pain, and abdominal enlargement. Patient's body weight goes up every month and BMI also increases.

---

### Acknowledgments

Thanks to all authors and researchers who have helped in completing this study

---

### Conflict of interest

The author declare no conflict of interest

---

### References

1. Syed FF, Mayosi BM. A modern approach to tuberculous pericarditis. *Prog Cardiovasc Dis.* 2007;50(3):218-236. doi:10.1016/j.pcad.2007.03.002.
2. Cherian G. Diagnosis of tuberculous aetiology in pericardial effusions. *Postgrad Med J.* 2004;80(943):262-266. doi:10.1136/pgmj.2003.013664.
3. Maisch B, Ristić AD. Diagnostik und therapie der perikarditis und des perikardergusses [Diagnostics and therapy of pericarditis and pericardial effusion]. *Herz.* 2014;39(7):837-856. doi:10.1007/s00059-014-4167-1.
4. Mayosi BM, Burgess LJ, Doubell AF. Tuberculous pericarditis. *Circulation.* 2005;112(23):3608-3616. doi:10.1161/CIRCULATIONAHA.105.543066.
5. Sainani GS, Sainani R. Tuberculous pericardial effusion. *Indian J Clin Pract.* 2012;22:371-4
6. Cs W, Ntsekhe M, Thabane L, Volmink J, Majombozi D, Gumedze F, et al. Interventions for treating tuberculous pericarditis ( Review ). *Cochrane Database Syst Rev.* 2017;9:1-65. DOI:10.1002/14651858.CD000526.pub2
7. Sagristà-Sauleda J, Mercé AS, Soler-Soler J. Diagnosis and management of pericardial effusion. *World J Cardiol.* 2011; 3(5): 135-143.
8. Imazio M and Adler Y. Management of pericardial effusion. *European Heart Journal.* 2013; 34:1186–1197. doi:10.1093/eurheartj/ehs372.
9. Fardman A, Charron P, Imazio M, Adler Y. European guidelines on pericardial diseases: a focused review of novel aspects. *Curr Cardiol Rep.* 2016;18(5):46. doi:10.1007/s11886-016-0721-1.
10. Montazeri V and Sokouti M. Tuberculous pericarditis: of a protocol in the treatment based on staging. *J Cardiovasc Thorac Res.* 2009;1:5-10.
11. Rahayoe NN, Supriyatno B dan Setyono DB editors. *Buku Ajar Respirologi Anak.* Edisi pertama, Jakarta: Ikatan Dokter Anak Indonesia; 2010. P 214-227.
12. Mayosi BM, Wiysonge CS, Ntsekhe M, Volmink JA, Gumedze F, Maartens G, et al. Clinical characteristics and initial management of patients with tuberculous pericarditis in the HIV era: The Investigation

of the Management of Pericarditis in Africa  
(IMPI Africa) registry. *BMC Infect Dis.*  
2006;6:1-9. DOI: 10.1186/1471-2334-6-2

13. Ntsekhe, M. & Mayosi, B. M. Tuberculous  
pericarditis with and without HIV. *Heart Fail.*  
*Rev.* 18, 367–373 (2013).

