



EJMCM

**EUROPEAN JOURNAL OF
MOLECULAR & CLINICAL MEDICINE**

ISSN 2515-8260



www.ejmcm.com

editor@ejmcm.com

Editorial Board

▣ Editor-in-chief

C. C. Yin
Associate Professor, Cancer Center, USA.
Email Address: editor@ejmcm.com

▣ Associate Editor

Dr Md. M. Hossain
UNITED KINGDOM
Email Address: info@ejmcm.com

Dr A.P Singh
India
Email Address: drapsingh321@gmail.com

▣ International Editorial Board

Dr M Nouraldein
Sudan
Email Address: info@ejmcm.com

Dr Md.M Rahman
Bangladesh
Email Address: editorial.ejmcm@gmail.com

Dr A C Sinha
Philadelphia
Email Address: editorial.ejmcm2@gmail.com

Dr A U Abayadeera
Srilanka
Email Address: editorial.ejmcm3@gmail.com

Dr F H Khan
Pakistan
Email Address: editorial.ejmcm4@gmail.com

Dr D Galante

Italy

Email Address: editorial.ejmcm5@gmail.com

▣ Editorial Board

Dr F Cordoso

Portugal

Email Address: editorial.ejmcm@gmail.com

Dr W Sirawaraporn

Thailand

Email Address: editorial.ejmcm1@gmail.com

Dr Davronova Dildora Saidovna

An associate professor of Uzbekistan State
University of World Languages

Specialty: DOCTOR OF PHILOSOPHY (PhD)

Email Address: dildora7575@mail.ru

Sanoyev Zafar Isomiddinovich

Medical science
Bukhara region, Romitan district
Tashkent Medical Academy

Specialty: Doctor of philosophy

Email Address: san@gmail.com

**EJMCM,
International House,
776-778 Barking Road,
Barking,
London, E13 9PJ, United Kingdom.**

Chief Editor: info@ejmcm.com

DAFTAR ISI

22.50



**STUDI DAMPAK KURSUS
BANGUNAN KETAHANAN PADA
B.Ed. MAHASISWA**

Dr. Priti Sonar (Dr. Priti Nagare)



*European Journal of Molecular & Clinical
Medicine*, 2020, Volume 7, Issue 8, Pages
5376-5379

Abstrak ▼ Tampilkan Artikel  

**UVEITIS PADA SYSTEMIC LUPUS
ERYTHEMATOSUS (SLE)**

Nugraha Wahyu Cahyana

*European Journal of Molecular & Clinical
Medicine*, 2020, Volume 7, Issue 8, Pages
5380-5386

Abstrak ▼ Tampilkan Artikel  

**PREDIKSI PENYAKIT GINJAL KRONIS
MENGUNAKAN CGAN**

Monika Vishnuvarthini A, Dr. C. Thirumarai
Selvi, Sowmiya. M, Shyam Kumar

*European Journal of Molecular & Clinical
Medicine*, 2020, Volume 7, Issue 8, Pages
5387-5392

Abstrak ▼ Tampilkan Artikel  

UVEITIS IN SYSTEMIC LUPUS ERYTHEMATOSUS (SLE)

Nugraha Wahyu Cahyana

Department of Ophthalmology, Faculty Medicine, Jember University, Jember

Abstract - SLE or Systemic Lupus Erythematosus is known as an autoimmune disease, usually affect multiple systems include the eyes organ. We report a 26-year-old female, complained about painless blurred vision in the right eye since 6 months ago. The examination result shown no history of low-grade fever, fatigue, photosensitivity, arthralgia, and hair loss, erythema over the cheeks, neck, hands, chest, and back. The visual acuity examination of the right eye was 1/300, keratic precipitates and band keratopathy were not found while posterior synechiae were found. Visual acuity of left eyes was 6/40 and was found normal from anterior to the posterior's segment. Ultrasonography (USG) test showed severe OD. Severe Vitreous Opacity (suspect chronic inflammatory), but retina in its place. A serological test revealed positive PCNA with 25 intensity, negative RF, and negative ANA IFA results. The patient was consulted to the internal medicine department and was diagnosed with systemic SLE with ocular involvement. For eight weeks Oral corticosteroid was given. Six weeks after treatment, the opacity of the vitreous had decreased and the visual acuity of the right eye has improved. A case of uveitis in SLE disease can be treated with corticosteroid therapy. Management needs to be holistic, both systemic and ocular. SLE systemic management generally improves ophthalmological outcome.

Keywords: Corticosteroid, Systemic Lupus Erythematosus, Uveitis, PCNA.

INTRODUCTION

SLE or Sytemic Lupus Erythemastosus is known as chronic autoimmune disease recognized by the presence of auto-antibodies in cell nuclei which mediate the destruction of immune complex tissue.¹ Multiple organ affected caused by connective tissue destructive then express cutaneous and musculoskeletal manifestations.^{1,2} Inflammatory immune response affects every organ and manifests such as in the ocular organ as a marker of systemic disease. This occurs in one-third of patients from mild to severe vision-threatening.^{3,4}

The case of SLE shows great variants from around the world. Differences are seen between age, gender, geographical and racial distributions. About 0.3 to 8.7 per 100,000 cases reported in 2011, with the prevalence set up from 1.1 to 534.9 per 100,000. USA, Caribbean, Brazil, and Sweden were the areas marked with the highest incidence.⁵ However, there is no overall data that discusses the incidence rate throughout Indonesia. Data from Rheumatology Clinic in Cipto Mangunkusumo General Hospital showed that 1,4% of patients were affected from SLE among total patient visits in 2002.⁶ About 7-26% of cases reported retinal involvement in SLE is and mostly seen in patients with systemic disease.^{3,7} SLE predominantly affects women and mostly affects women of reproductive age.⁵ A study by Feldman., *et al.* report the case was 6 times greater in women of late teens and early '40s while its ratio 1:9-14 in male to female.^{6,8,9}

SLE principle diagnostic based on 4 of 11 signs, either historical or present, including the presence of antinuclear antibodies, discoid rash, malar rash, oral ulcers, photosensitivity, serositis, non-erosive arthritis, immunological, hematological, and neurological disorder. Ocular is not the main target of immune-mediated damage in SLE but affects in several ways to ocular morbidity.^{6,9} Anterior segment manifestation such as iridocyclitis, abnormalities of the eyelid, keratoconjunctivitis sicca, episcleritis, keratitis.^{4,8,9} Posterior segment manifestation includes optic neuropathy, retinal artery and/or arterial vein occlusion, retinopathy, retinal vasculitis, and choroidopathy. Some mechanisms induce ocular symptoms in SLE. Immune complex deposition, the formation of autoantibodies, vasculitis, and thrombosis may cause inflammatory responses and activates the complement system.⁴ SLE patients shown at least two

major symptoms of retinopathy: the first symptoms is “classic” type retinopathy and the second symptoms is retinal vessel occlusion which involve arteries/veins. The classic findings are retinal hemorrhage, cotton-wool spots, and vascular abnormalities (arteries narrow with capillary dilation, and vein dilation or tortuosity)^{7,9,10} However, A severe vaso-occlusive retinopathy is also associated with multiple branches retinal artery occlusions, ocular neovascularization, traction retinal detachment, vitreous hemorrhage, neovascular glaucoma, widespread retinal capillary nonperfusion, and significant resultant loss.⁹

Therapy was given to induce, establish remission and prevent relapse of SLE.⁹ Management needs to be holistic, both systemic and ocular. Systemic management of SLE has treatment ranges from Nonsteroidal Anti-inflammatory Drugs (NSAIDs), corticosteroids, Hydroxychloroquine, Immunosuppression, to biological therapy.^{9,11,12} Management of the systemic disease in SLE affects the improvement of the ophthalmological outcome.^{7,12} Additional management of local and systemic therapy is indicated depend on ocular complications. Retinal neovascularization usually requires laser pan-retinal photocoagulation in cases of vaso-occlusive disease.^{7,9,12} Vitreoretinal surgery is performed for patients with traction retinal detachment or vitreous bleeding. The retinopathy prognosis of SLE affected based on the type of retinopathy and vaso-occlusion.¹² Herewith a rare case of SLE retinopathy is presented, with ocular clinical features that resemble other posterior uveitis. This case demonstrates the typical ocular manifestation of SLE and integrates collaboration with other disciplines. A comprehensive evaluation is required to help to make a definitive diagnosis. Thus, early systemic management could prevent irreversible visual loss and risk of death.

CASE REPORT

A 26-year-old female complained of sudden blurred vision in the right eye since 6 months ago. There was no redness, swelling, or discharge, and both were painless. The patient did not receive any treatment before. There was no history of low-grade fever, fatigue, photosensitivity, arthralgia, hair loss, erythema over the cheeks, neck, hands, chest, and back. The patient was a master's degree of public health student, has not been married. No history of chronic productive cough, sweating at night, decreased bodyweight, mouth and genital ulcer, animal contact, trauma, skin depigmentation, tinnitus, and the use of drugs. History of using glasses, allergy, hypertension, and diabetes mellitus were denied.

During the ophthalmological examination, it was revealed that the right eyes' visual acuity was 1/300, with IOP 25 mmHg and a good anterior segment. There were multiple synechiae posterior, but no band keratopathy (Figure 1). The lens was a mild opacity and cloudy of vitreous. The optic disc and retina cannot be observed. Meanwhile, the visual acuity of the left eyes was 6/40, with normal IOP and a good anterior segment. Iris and pupil were round, located at the central. The lens was also clear. In the fundus, we found a normal optic disc and normal retina. The patient was diagnosed with OD Posterior uveitis. Furthermore, the patient was examined with USG. The USG results showed OD: Vitreous Opacity with mild echospike and mobility. Retina On Place shown in (Figure 2). The patient was then examined with laboratory examination, the immunoserological results showed negative Rheumatoid factor (RF), positive PCNA (Table 1) with the attached profile (Table 2).

Figure 1 Examination of the right eye show a multiple synechia posterior, but no band keratopathy

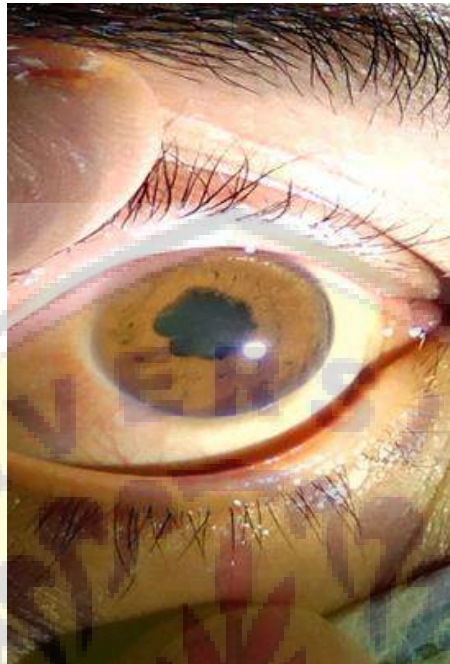


Figure 2 The USG results showed OD: Vitreous Opacity with mild of echospike and mobility. Retina On Place.



Table 1: The immunoserological results showed negative Rheumatoid factor (RF), positive PCNA

Anti-	Associated diseases	Result
nRNP/Sm	Mixed Connective Tissue Disease (MCTD) tharp syndrome, SLE, Poli dermatomyositis	Negative
Sm	Systemic Lupus erythematosus	Negative
SS-A (Ro)	Sjogren's syndrome , SLE, Neonatal lupus syndrome, myositis	Negative
Ro-52	Sjogren's syndrome, Systemic Lupus erythematosus	Negative
SS-B (La)	Sjogren's syndrome , Systemic Lupus erythematosus, Neonatal lupus syndrome,	Negative

Scl-70	Progressive systemic sclerosis, diffuse form	Negative
PM-Scl 100	systemic sclerosis, Polymyositis	Negative
Jo-1	Polymyositis, dermatomyositis	Negative
Centromere B	Progressive systemic sclerosis, diffuse form, Primary biliary cirrhosis	Negative
PCNA	Systemic Lupus erythematosus	Positive
ds DNA	Systemic Lupus erythematosus	Negative
Nucleosomes	Systemic Lupus erythematosus	Negative
Histones	SLE, Drug-induced Lupus erythematosus, Rheumatoid arthritis	Negative
Rib-P-Protein	Systemic Lupus erythematosus	Negative
AMA-M2	Primary biliary liver cirrhosis	Negative
DFS70	(Atopic dermatitis , asthma Vogt-Harada syndrome and interstitial cystitis as well as in rheumatic disease), with low prevalence, and sometimes also in healthy blood donors (up to 8%)	Negative

Table 2: PCNA examination result show PCNA positive with 25 intensity

Antigen	Intensity	Class	O (+) + ++
RNP/Sm (RNP/Sm)	3	0	
Sm (Sm)	0	0	
SS- (60 kDa) (SSA)	1	0	
Ro-52 recombinant (52)	0	0	
SS-B (SSB)	1	0	
Scl-70 (Scl)	1	0	
PM-Scl 100 (PM 100)	1	0	
Jo-1 (Jo)	1	0	
Centromere B (JB)	0	0	
PCNA (PCNA)	25	+	
ds DNA (DNA)	1	0	
Nucleosomes (NUC)	0	0	
Histones (HI)	5	0	
Ribosomal Protein (RIB)	0	0	
AMA-M2 (M2)	1	0	
DFS70 (DFS70)	1	0	
Control (Ko)	80	+++	

One week afterward, the anterior segment showed no sign of improvement on the posterior segment. Laboratory test record decreased hemoglobin count to 11,5 g/dL and leukocyte count to 4.220/μL, normal thrombocyte count, increased ESR to 60 mm, and decreased CD4 count to 329 cells. There was a positive result of IgG Rubella, with titer increased to 961.9 IU/mL (n:< 5.10 IU/mL), alongside with non-reactive IgM. Serology test of IgG CMV result was also positive with non-reactive IgM. Screening of anti-HIV showed non-reactive results and antinuclear antibody (ANAs) test was positive at a titer of 1:1000. Chest X-Ray examination showed signs of bilateral paracardial infiltrates with pneumonia as a differential diagnosis. Based on clinical and laboratory results, the patient was diagnosed with unilateral posterior uveitis caused by CMV infection. Thereafter, the case was consulted further to Allergy-Immunology Division from the Department of Internal Medicine to find the underlying etiology.

The Allergy-Immunology division diagnosed systemic SLE disease with the characteristic of mucocutaneous and ocular involvement. The patient was prescribed of consumed oral methylprednisolone 3 x 16 mg, cavit D3 3 x 500 mg, folavit 1 x 400 mg, and lansoprazole 1 x 30 mg. for the further, he also consulted by to Dermatology Department and diagnosed with chronic cutaneous lupus erythematosus.

Then the patient returned for follow-up six weeks after his initial visit. The condition of the right eye was getting better, with visual acuity recorded at 5/60. Examination of the posterior segment of the right eyes shown a round optic disc, CDR 0,3-0,4, aa./vv 1/3, cotton wool spots, flame-shaped hemorrhages, and

ghost vessels. Apart from that, a posterior segment of the left eye, a round optic disc, pale and hard to be evaluated CDR, aa./vv 1/3, cotton wool spots, flame-shaped hemorrhages, and ghost vessels were found. The patient then diagnosed with uveitis unilateral e.c. SLE.

DISCUSSION

This case reported a young female patient with sudden painless blurred vision in the right eye since six months before admission. Visual acuity of the right eye was 1/300 and the left eye was 6/40. The posterior segment's right eye shown multiple synechiae and no band keratopathy, the left eye was normal. From this condition, the primary consideration of the right eye was the posterior segment shown vitreous opacity while the fundus examination shown can't be observed. An infectious cause is more commonly seen in CMV retinitis and tuberculosis ocular, while the autoimmune disease may include SLE. Thus workup uveitis was performed to confirm the diagnosis including routine blood test, urinalysis, erythrocyte sedimentation rate (ESR), TORCH, HIV screening, VDRL, TPHA, antinuclear antibody test (ANA); anti-double-stranded DN (dsDNA), Rheumatoid Factor (RF), tuberculin skin test (TST), and chest x-ray.

The result of the workup showed high titer of Rubella IgG, CMV IgG, HSV IgG, and non-reactive HIV. The results of the antinuclear antibody (ANA) tested positive at a titer of 1:1000. From the chest x-ray, there was a pericardial infiltrate bilateral and negative tuberculin skin test. Diagnosis of SLE retinopathy was considered with the clinical appearance and history of low-grade fever, fatigue, arthralgia, and facial rash. Laboratory tests also showed results of anemia, thrombocytopenia, elevated ESR, and the presence of ANAs. Thorough posterior section examination showed multiple cotton wool spots and intraretinal hemorrhages.

Epidemiologically, SLE most commonly occurs in women, however, men may also be affected with a ratio of 1:9-14 in male to female.⁶ SLE principle diagnostic based on 4 of 11 signs, either historical or present, including the presence of antinuclear antibodies, discoid rash, malar rash, oral ulcers, photosensitivity, serositis, non-erosive arthritis, immunological, hematological, and neurological disorder. Ocular is not the main target of immune-mediated damage in SLE but affects in several ways to ocular morbidity.^{4-6,8}

However, differential diagnosis of CMV retinitis could not be excluded as well for several reasons. Since the patient was still relatively young, a history of sexual intercourse, and multifocal white exudates with hemorrhage result during the retinal examination, may identify the patient's condition to CMV retinitis. The clinical sign of CMV retinitis is usually divided into 3 variants, including a classic or fulminant form with early stages presents as cotton wool spots. This disease develops along the blood vessels of the retina, causing areas where the retinal bleach meets which are often associated with intraretinal hemorrhages and hard exudates.¹³ Ocular lesions that mostly seen on Acquired Immunodeficiency Syndrome (AIDS) are cotton wool spots, shown up in 25 - 50% of patients and associated with CMV retinitis and retinal hemorrhages.¹⁴ However, it was disputed with the fact the ancillary test of IgG CMV titer and HIV screening test showed negative results.

For further evaluation, the patient was directed to Internal Medicine Department and then she was diagnosed as SLE with ocular and mucocutaneous involvement. It conforms to the revised classification criteria of the American College of Rheumatology (ACR). The diagnosis was determined based on a history of malar rashes, discoid rash, arthralgia, anemia, elevated ANA titer (1:1000), and the elevated anti-ds DNA antibody titer (134.8 IU/mL compared to the normal titer).

Various mechanisms of SLE may cause eye disease. Several mechanisms include immune complex positioning and other antibody-related mechanisms, thrombosis, and vasculitis to name a few.⁴ Retinal cell death and optic nerve demyelination are due to antibody-dependent cytotoxicity. The mechanism of primary lupus retinopathy is unknown but is thought to be secondary to the circulating immune complexes found in this disease.¹⁵ Lupus anticoagulant antibodies are owned by about 10% of lupus patients. Anticoagulant antibodies are known to increase the incidence of thrombosis. Anti-phospholipid antibodies (APA) are associated with more severe retinopathy and vascular occlusion. In SLE, the retinal capillaries

are involved and mainly produce cottony specks or microinfarcts of the retinal nerve fiber layer due to focal ischemia and necrotizing retinal vasculitis.^{15,16}

Retinopathy is an intraocular involvement and one of the most common occurrences in patients with SLE, about 2-30% of SLE patients have retinopathy, it depends on the severity and activity of the disease.⁹ Activity of systemic and cerebral SLE corresponds to retinal involvement. Originally, SLE patients develop major clinical forms of retinopathy. The first type is characterized by cotton wool spots with the presence or absence of intraretinal hemorrhages, generally occurring in patients with classic retinopathy of SLE. The second type of retinopathy involves arterial and/or venous vascular, and it is associated with occlusion of the larger retinal vessels. Proliferative lupus retinopathy is the third type of retinopathy in SLE.^{10,15}

Cotton wool spots are classic retinal findings. It's an expression of localized micro-infarction from the fiber layer of the retinal nerve with the presence or absence of intraretinal hemorrhages, microaneurysms, and hard exudates.^{9,10} Mild lupus retinopathy composed of cotton wool spots, retinal hemorrhages, perivascular hard, and may asymptomatic.⁴ Generally, the symptom of lupus retinopathy is microangiopathy with cotton wool spots and small intraretinal hemorrhages occur in 80% of cases and are mostly related to a good visual prognosis. In cases with peripheral retinal hemorrhages, retinal nonperfusion may also be observed.^{9,17}

CONCLUSION

The appropriate diagnosis and treatment could prevent further irreversible visual loss. Management should to be holistic cause has impact to improves the ophthalmological outcome.

ACKNOWLEDGMENTS

The authors are grateful to the authorities of the Department of Ophthalmology, Faculty Medicine, Jember University, Jember, East Java, Indonesia for able guidance and knowledge imparted to us.


CONFLICT OF INTEREST

The authors declare no conflict of interest.

REFERENCES

1. Au A, Franzco J. Review of severe vaso-occlusive retinopathy in systemic lupus erythematosus and the antiphospholipid syndrome: associations, visual outcomes, complications and treatment. *Clin Exp Ophthalmol*. 2004; 32: 87-100.
2. Ho YT, Chung MY, Lee FA, Tsai YC. Severe vaso-occlusive retinopathy as the primary manifestation in a patient with systemic lupus erythematosus. *J Chin Med Assoc*. 2008; 71: 377-380.
3. Sitaula RK, Dev NS, Divya S. Role of lupus retinopathy in systemic lupus erythematosus. *J Ophthalmic Inflamm Infect*. 2016; 6: 15.
4. Sivaraj RR, Durrani OM, Denniston AK, Murray PI, Caroline G. Ocular manifestations of systemic lupus erythematosus. *Rheumatology*. 2007; 46(12): 1757-62.
5. Papagiannuli E, Benjamin R, Graham RW, Caroline G, Philip IM, Alastair KD. Systemic lupus erythematosus: An update for ophthalmologists. *Surv Ophthalmol*. 2016; 61: 65-82.
6. Kasjmir YI. Diagnosis dan Pengelolaan Lupus Eritematosus Sistemik. *Perhimpunan Reumatologi Indonesia*. 2011: 3.
7. Denniston AK. Rheumatic Disease. In: Ryan SJ, Schachat AP, Wilkinson CP, editors. *Retina*. 5th edition. Elsevier Health Sciences. 2012; 3: 1423-1427.
8. Palejwala NV, Harpreet SW, Steven Y. Ocular manifestation of systemic lupus erythematosus: A review of the literature. *Rheumatology*. 2013; 33: 1637-1642.
9. Silpa-archa S, Joan JL, Foster CS. Ocular manifestations in systemic lupus erythematosus. *Br J Ophthalmol*. 2016; 100: 135- 141.

10. Bajwa A, Foster SC. Ocular manifestations of systemic lupus erythematosus. *Autoimmune Dis.* 2014; 5: 1.
11. Giorgi D, Pace F, Giorgi A, Bonomo, I, Gabrieli CB. Retinopathy in systemic lupus erythematosus : pathogenesis and approach to therapy. *Human Immunology.* 1999; 60: 688-696.
12. Arevalo JF. Manifestation of systemic lupus erythematosus. In: Arevalo JF editor. *Retinal and choroidal manifestation of selected systemic disease.* New York, NY: Springer; 2012: 333-352.
13. Zamir E. Ocular infection with cytomegalovirus (CMV). In: Yanoff M, Duker, JS, editor. *Ophthalmology.* 7. 4th edition. Philadelphia, PA: Elsevier Saunders; 2014: 704-707.
14. Denniston AK. Medical retina. In: Ryan SJ, Schachat AP, Wilkinson CP, editors. *Retina.* 5th edition. Elsevier Health Sciences; 2012: 1443-1444.
15. Bharadwaj AK. Retinal manifestations of the rheumatic disease. In: Albert DM, Miller JW, Azar DT, editor. *Principles and Practice ophthalmology.* 3rd Edition. Elsevier Health Division. 2011.
16. Thorne EJ, Jabs DA. The eye in rheumatic disease. In: Horchberg MC, Silman AJ, Smolen JS, editor. *Rheumatology.* 2. 6th edition. United States, US: Elsevier Mosby; 2015: 263.
17. Wu C, Rongping D, Fangtian D, Qian W. Purtscher-like retinopathy in systemic lupus erythematosus. *Am J Ophthalmol.* 2014; 158: 1335- 1341.



European Journal of
Molecular and Clinical...

Q4

Applied
Microbiology and
Biotechnology

best quartile

SJR 2019

0.15

powered by scimagojr.com

← Show this widget in
your own website

Just copy the code below
and paste within your HTML
code:

```
<a href="https://www.scirp.org/journal/ejmc">
```

