

**KARYA ILMIAH:  
SEMINAR INTERNASIONAL**

*Ventral Abdominal Wall Defect, 2nd Case: Followup at 4 Months*

**dr. Supangat M.Kes., Ph.D Sp.BA**

**NIP. 197304241999031002**

- Tenaga Pengajar Bagian Paraklinik  
Fakultas Kedokteran Universitas Jember

**KEMENTERIAN PENDIDIKAN DAN KEBUDAYAAN**

**UNIVERSITAS JEMBER**



---

Karya Ilmiah Dipresentasikan dalam Seminar Internasional

:International Colorectal Web Meeting January 16, 2020 W. H. Hendren  
Foundation for Pediatric Surgery & Urology in collaboration with  
American Pediatric surgical association & Society for Pediatric Urology

# International Colorectal Web Meeting: January 2020

---

## Patient Cases

### ***Video Summary of Cases Presented***

(<https://www.hendrenproject.org/case/video-summary-international-colorectal-web-meeting-january-2020>)

**Case 1. Male Patient Referred with Persistent Diarrhea** (/content/1-old-male-patient-referred-persistent-diarrhea)

Karla Santos-Jasso, M.D., M.Sc.; *National Institute of Pediatrics, Mexico City, Mexico*

**Case 2. Recurrent Pelvic Abscess and Fecal Incontinence After Failed Duhamel Procedure After Misdiagnosis of Hirschsprung Disease**

(<https://www.hendrenproject.org/content/recurrent-pelvic-abscess-and-fecal-incontinence-after-failed-duhamel-procedure-after>)

Piotr Czauderna, M.D.; and Stefan Anzelewicz, M.D.; *Department of Surgery and Urology for Children and Adolescents, Medical University of Gdansk, Gdansk, Poland*

**Case 3. Complex Anorectal Malformation**

(<https://www.hendrenproject.org/content/complex-anorectal-malformation>)

## Related Links

About the International Colorectal Web Meetings (/node/1296)

Submit a Patient Case (/node/1470)

How To Attend the Web Meetings (/node/1287)

Recent Web Meetings (/node/1543)

Future Web Meetings (/node/1384)

N. Albertos, M.D.; *Hospital General Universitario de Alicante, Alicante, Spain*

THP Colorectal Surgery Center (/node/1054)

**Case 4. Ventral Abdominal Wall Defect, Second Case: Follow-up at 4 Months** (/content/ventral-abdominal-wall-defect-second-case-follow-4-months)

Supangat, M.D.; Gilang Vigorous, General Practitioner; *Dr. Soebandi General Hospital, Faculty of Medicine, University of Jember, East Java, Indonesia*

**Watch an Interactive Video of the January 2020 International Colorectal Web Meeting Organized by Slides**

(<https://hendrenproject.adobeconnect.com/psjymd9dgxjl/>)

Web Meeting Video

**Presenters**

INTERNATIONAL COLORECTAL WEB MEETING--January 2020

**Comments & Questions** (Expanded)

Marcela Bailez: Good morning

rodolfo soto-ravelo DomRep: greetings from Dominican Republic , all the best in this 2020

andrea.bischoff@childrenscolorado.org: Good morning!

THE HENDREN PROJECT--Ray Evergam: DR. BISCHOFF, WE LOST YOUR WEBCAM...

Koynov Yuri: Greetings from Russia

THE HENDREN PROJECT--Ray Evergam: YOUR WEBCAM

Marcela Bailez: Buenos Aires Garrahan with our colorectal team

andrea.bischoff@childrenscolorado.org: Welcome everyone. Bien-venidos

andrea.bischoff@childrenscolorado.org: We will start in one minute

kawtan: Hello from algeria

czauderna.p@gmail.com: Welcome, Andrea, it is Piotr from Gdansk. Stefan will present our case.

andrea.bischoff@childrenscolorado.org: Hi Piotr!!!!


**Welcome to the International Colorectal Web Meeting**

**TODAY'S PATIENT CASE PRESENTERS:**

*Karla Santos-Jasso, M.D., M.Sc.*  
*Stefan Anzelewicz, M.D.*  
*Nuria Albertos, M.D.*  
*Supangat, M.D.*  
*Gilang Vigorous, General Practitioner*  
*Andrea Bischoff, M.D.*

The Hendren Project  
 Your Global Networked Community for Pediatric Surgery & Urology

INTERNATIONAL CENTER FOR COLORECTAL AND UROGENITAL CARE



### Rate This Presentation:

Your rating: None      No votes yet

[Terms of Use \(/node/398\)](/node/398) | [Privacy Policy \(/node/397\)](/node/397) | [End User Agreement \(/node/399\)](/node/399)

Copyright © 2020 W. H. Hendren Education Foundation for Pediatric Surgery and Urology



supangat Doctor <drsupangat@unej.ac.id>

---

**RE: Patient Case Submission to the International Colorectal Web Meeting**

2 messages

---

**Bischoff, Andrea** <Andrea.Bischoff@childrenscolorado.org>  
To: Gilang Vigorous <gilangvigorous@yahoo.co.id>, Ray Everngam <ray@hendrenproject.org>  
Cc: Dokter Supangat Kedokteran <drsupangat@unej.ac.id>

Tue, Jan 14, 2020 at 11:25 PM

Dear Ray –

Please find attached case # 4 that will be presented by the group from Indonesia.

Thanks,

Andrea

**Andrea Bischoff, MD | Assistant Director, International Center for Colorectal and Urogenital Care | Children's Hospital Colorado | Associate Professor of Surgery University of Colorado**

13123 East 16th Avenue, Box 323 | Anschutz Medical Campus | Aurora, CO 80045 | Main Phone: (720)777-9880 | Office Phone: (720) 777-9448 | Fax: (720) 777-7891 | [andrea.bischoff@childrenscolorado.org](mailto:andrea.bischoff@childrenscolorado.org)

Connect with Children's Hospital Colorado on [Facebook](#) and [Twitter](#)



 [Doctors Pena Bischoff](#)

 [@DrsPenaBischoff](#)

 <https://www.linkedin.com/in/andreabischoff>





<https://www.youtube.com/watch?v=FMqLE0sE3zc>



[@penabischoff](#)

---

**From:** Gilang Vigorous <[gilangvigorous@yahoo.co.id](mailto:gilangvigorous@yahoo.co.id)>  
**Sent:** Tuesday, January 14, 2020 8:18 AM  
**To:** Bischoff, Andrea <[Andrea.Bischoff@childrenscolorado.org](mailto:Andrea.Bischoff@childrenscolorado.org)>  
**Cc:** Dokter Supangat Kedokteran <[drsupangat@unej.ac.id](mailto:drsupangat@unej.ac.id)>  
**Subject:** Patient Case Submission to the International Colorectal Web Meeting

Attached is a patient case that I would like to present at an upcoming International Colorectal Web Meeting on The Hendren Project.

Sent from [Mail](#) for Windows 10

---

CONFIDENTIALITY NOTICE: This e-mail, including any attachments, is for the sole use of the intended recipient and may contain confidential and privileged information. If you are not an intended recipient, or the person responsible for delivering this message to an intended recipient, you are hereby notified that reading, copying, using or distributing this message is prohibited. If you are not an intended recipient, please contact the sender by reply email and destroy all copies of the original message from your computer system.

---

---

 **Case#4 Ventral Abdominal Wall Defect 2nd Case (4 months follow-up).pptx**  
479K

---

**Ray Everngam** <[ray@hendrenproject.org](mailto:ray@hendrenproject.org)>  
To: "Bischoff, Andrea" <[Andrea.Bischoff@childrenscolorado.org](mailto:Andrea.Bischoff@childrenscolorado.org)>  
Cc: Gilang Vigorous <[gilangvigorous@yahoo.co.id](mailto:gilangvigorous@yahoo.co.id)>, Dokter Supangat Kedokteran <[drsupangat@unej.ac.id](mailto:drsupangat@unej.ac.id)>

Tue, Jan 14, 2020 at 11:38 PM

Thanks!

---

Raymond L. Everngam  
Executive Director  
*The Hendren Project*  
[www.hendrenproject.org](http://www.hendrenproject.org)  
717-579-6115



Join us on Twitter!  
[@hendrenproject](https://twitter.com/hendrenproject)

[Quoted text hidden]



# Certificate of Presentation

W. H. Hendren Education Foundation for  
Pediatric Surgery & Urology

*hereby certifies that*

**Supangat, M.D., M.Sc., Ph.D., *Pediatric Surgeon***  
**Gilang Vigorous, *Practitioner***

*Dr. Soebandi General Hospital, Faculty of Medicine, University of Jember, East Java, Indonesia*

*presented the following patient case:*

***Ventral Abdominal Wall Defect, 2<sup>nd</sup> Case: Follow-up at 4 Months***

*during the*

**International Colorectal Web Meeting**

*January 16, 2020*





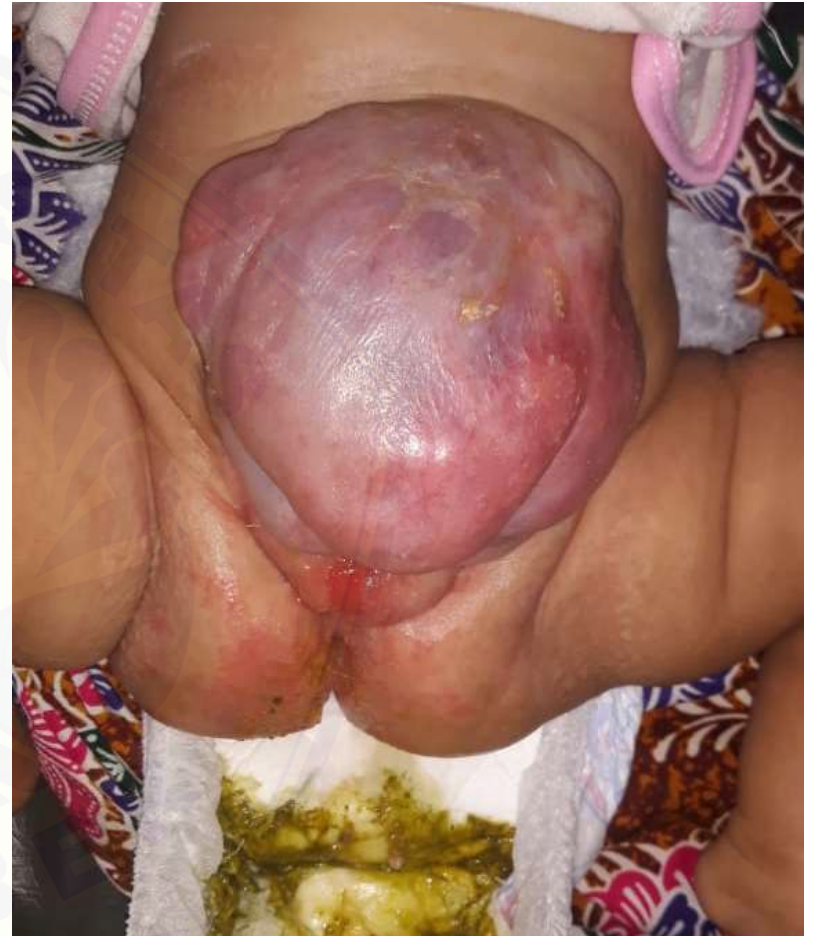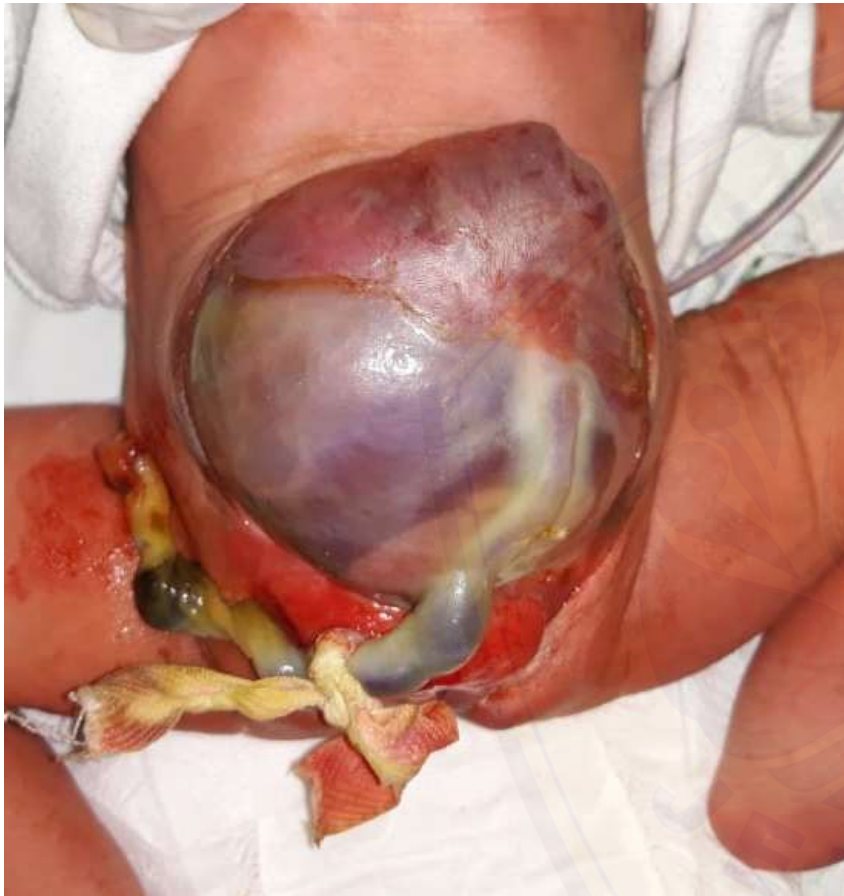# Ventral Abdominal Wall Defect 2nd Case: 4 months follow-up

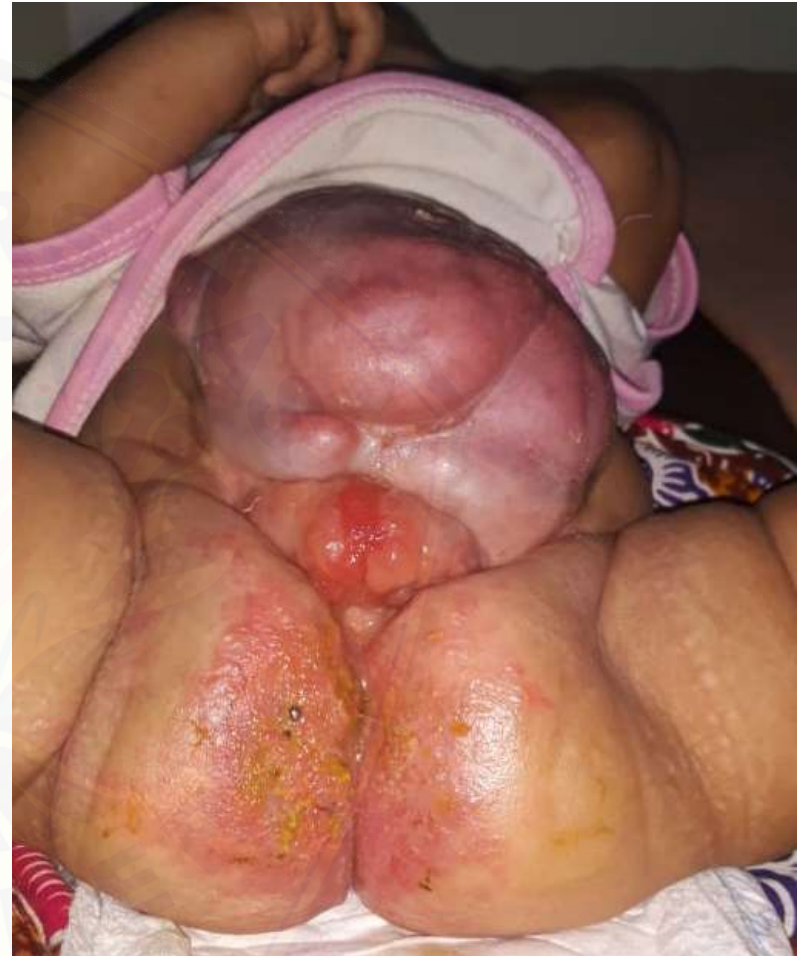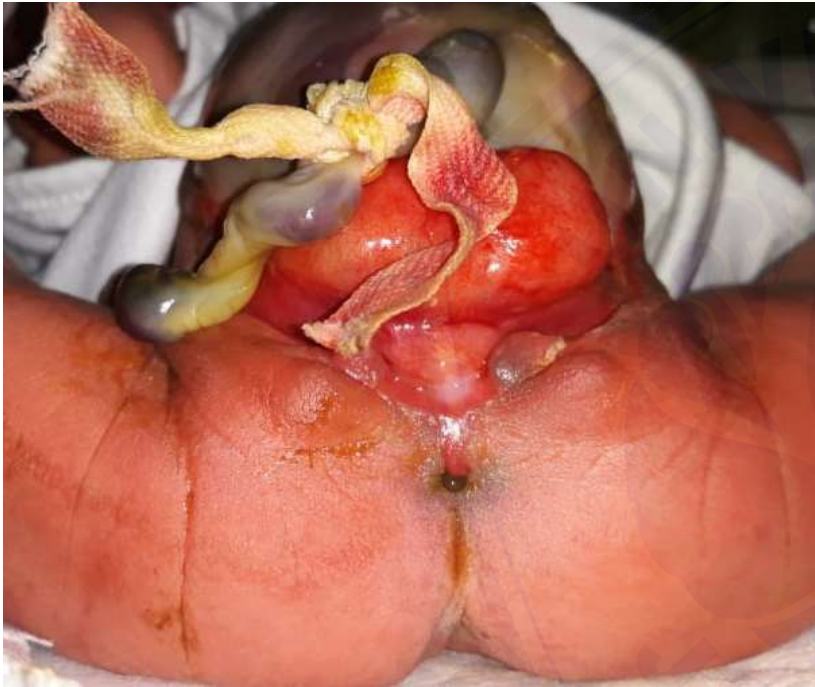Supangat, Pediatric Surgeon  
Gilang Vigorous, General Practitioner

dr. Soebandi General Hospital  
Faculty of Medicine University of Jember  
East Java, Indonesia

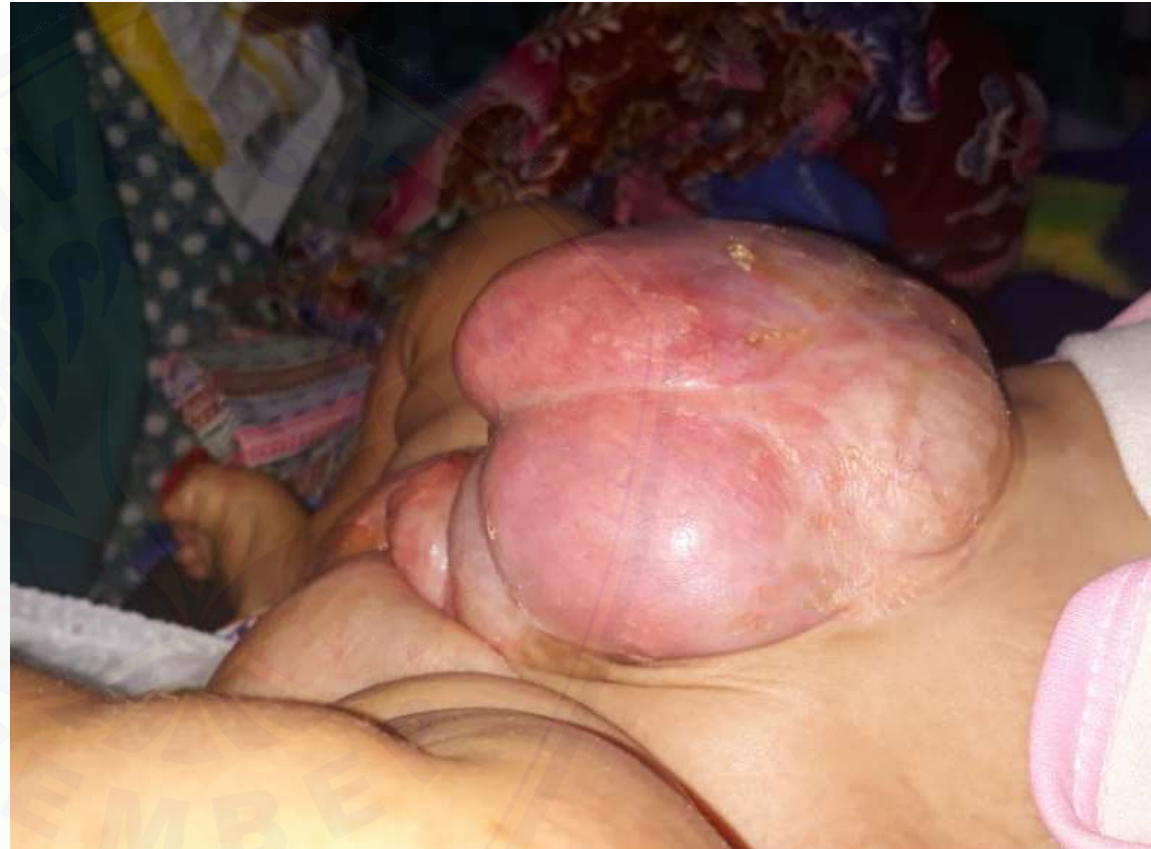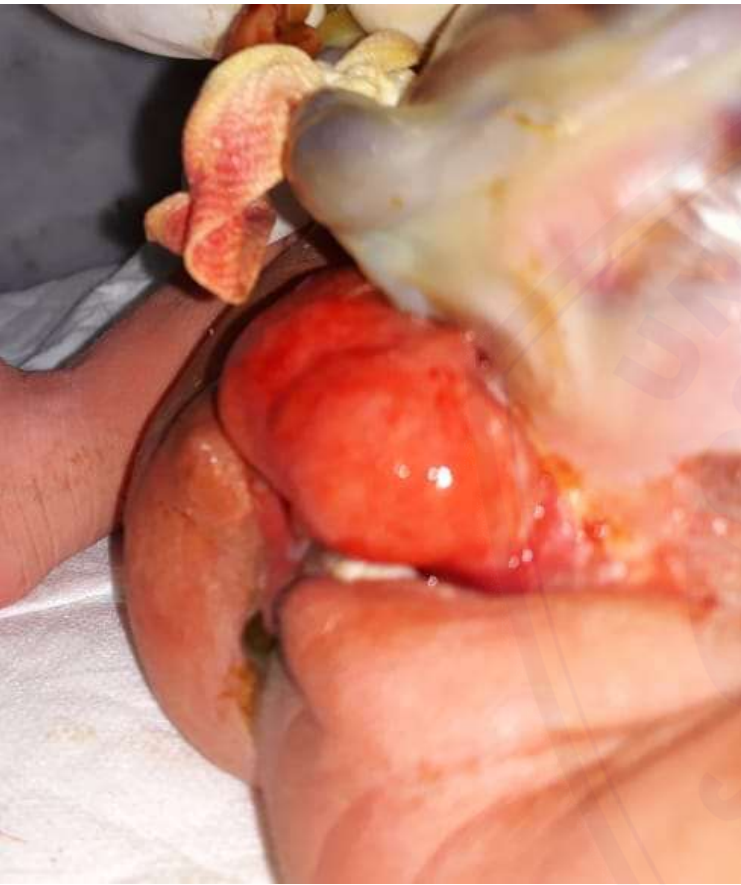# Management provided (conservative)

- Topical silver sulfadiazine (omphaloccele)
- Vaseline (suspected bladder exstrophy)
- Karyotyping (being processed)
  
- Gain weight (6 kg)
- Good passing stool
- Good voiding





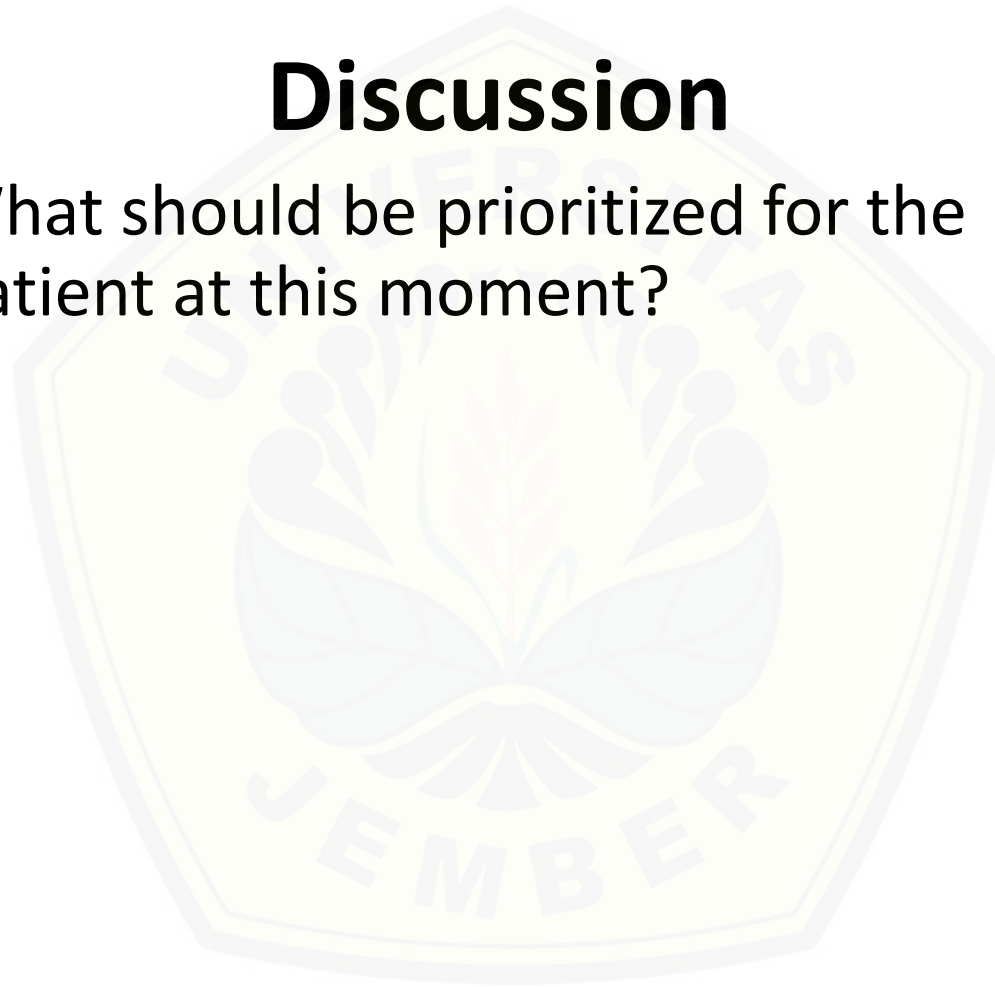






## Discussion

- What should be prioritized for the patient at this moment?





**Thank You**