

**KARYA ILMIAH:
SEMINAR INTERNASIONAL**

*5-Year-Old Female Patient Presenting with
Abdominal Pain*

dr. Supangat M.Kes., Ph.D Sp.BA

NIP. 197304241999031002

- Tenaga Pengajar Bagian Paraklinik
Fakultas Kedokteran Universitas Jember

KEMENTERIAN PENDIDIKAN DAN KEBUDAYAAN

UNIVERSITAS JEMBER



Karya Ilmiah Dipresentasikan dalam Seminar Internasional

:International Colorectal Web Meeting , April 23, 2020 W. H. Hendren

Foundation for Pediatric Surgery & Urology in collaboration with

American Pediatric surgical association & Society for Pediatric Urology

International Colorectal Web Meeting: April 2020

Patient Cases

Video Summary of Cases Presented

(<https://www.hendrenproject.org/case/video-summary-international-colorectal-web-meeting-april-2020>)

Case 1. 5-Year-Old Female Patient Presenting with Abdominal Pain

(</content/5-year-old-female-patient-presenting-abdominal-pain>)

Supangat, M.D.; Azka Darajat, M.D.; *Dr. Soebandi General Hospital, Faculty of Medicine, University of Jember, East Java, Indonesia*

Case 2. Male Patient with Bladder Exstrophy and Anorectal

Malformation: Gender Assignment (</content/male-patient-bladder-exstrophy-and-anorectal-malformation-gender-assignment>)

Karla Santos-Jasso, M.D., M.Sc., Ph.D.; and Rossy Angelica Quimbert Montes, M.D.; *National Institute of Pediatrics, Mexico City, Mexico*

Case 3. Female Patient with Covered Cloacal Exstrophy Variant

(</content/female-patient-covered-cloacal-exstrophy-variant>)

Andrea Bischoff, M.D.; *Assistant Director, International Center for Colorectal and Urogenital Care, Children's Hospital Colorado, Aurora, CO*

Related Links

About the International Colorectal Web Meetings (</node/1296>)

Submit a Patient Case (</node/1470>)

How To Attend the Web Meetings (</node/1287>)

Recent Web Meetings (</node/1543>)

Future Web Meetings (</node/1384>)

Case 4. 8-Month-Old Male Patient Born with an Anorectal Malformation (/content/8-month-old-male-patient-born-anorectal-malformation)


THP Colorectal Surgery Center (/node/1054)

Andrea Bischoff, M.D.; *Assistant Director, International Center for Colorectal and Urogenital Care, Children's Hospital Colorado, Aurora, CO*

Watch an *Interactive Video* of the April 2020 International Colorectal Web Meeting Organized by Slides

(<https://hendrenproject.adobeconnect.com/pw4c3xib6b6y/>)

Web Meeting Video



00:00 00:00

Rate This Presentation:

Your rating: None No votes yet

Add new comment

Your name SKedokteran

Subject

Comment *

✓ Save

Preview

[Terms of Use \(/node/398\)](/node/398) | [Privacy Policy \(/node/397\)](/node/397) | [End User Agreement \(/node/399\)](/node/399)

Copyright © 2020 W. H. Hendren Education Foundation for Pediatric Surgery and Urology



5-Year-Old Female Patient Presenting with Abdominal Pain

Supangat, M.D.

Azka Darajat, General Practitioner

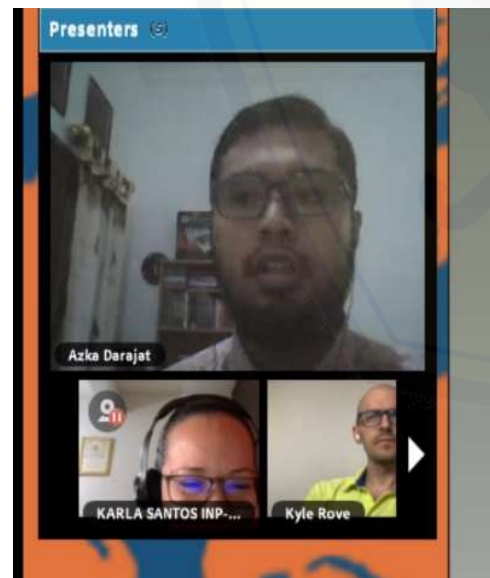Dr. Soebandi General Hospital, Faculty of Medicine, University of Jember, East Java, Indonesia

Summary Slides:

5-Year-Old Female Patient Presenting with Abdominal Pain

(<https://www.hendrenproject.org/sites/default/files/ICWM042020C1.pdf>)

Patient Case Discussion



Case Presentation

- 5-year-old female child
- Patient presented with abdominal pain → referred to our hospital because of suspected acute appendicitis
- Leukocyte 13.000, Neutrophil 56%
- Patient had a history of delayed passage of meconium, chronic constipation, and routine use of laxative

Related Links

About the International Colorectal Web Meetings
(/node/1296)

Submit a Patient Case
(/node/1470)

How To Attend the Web Meetings
(/node/1287)

Recent Web Meetings
(/node/1543)

Future Web Meetings
(/node/1384)

Digital Repository Universitas Jember

Important Web Links on THP

- About the INTERNATIONAL COLORECTAL...
- COVID-19 Resources for Pediatric Surge...
- About THE HENDREN PROJECT

Browse To:

Comments & Questions About the Case (Everyone)

Tim: Greetings from kenya

Brenda Huerta Rengifo: Greeting from Trujillo, Peru
----- (04/23/2020 10:00) -----

Fayza Haider, Bahrain: Greetings from Bahrain

Maricarmen Olivos / Chile: Good Morning!

Feride: Good afternoon from Turkey

Etienne: Canada

Alejandra López: Good morning Everyone!!

THP Colorectal Surgery Center

(/node/1054)

Hosts (1)

- THE HEND...

Presenters (5)

- Andrea Bi...
- Azka Darajat
- KARLA S...
- Kyle Rove

00:00
00:00

Rate This Presentation:

Your rating: None No votes yet

THP Source:

International Colorectal Web Meetings (/webinar/international-colorectal-web-meetings)

5-Year-Old Female Patient Presenting with Abdominal Pain

Key Words:

Female Patient (/tags/female-patient-0)

Abdominal Pain (/tags/abdominal-pain-0)

Idiopathic Constipation (/tags/idiopathic-constipation)

Hirschsprung Disease (/tags/hirschsprung-disease)

[Terms of Use \(/node/398\)](/node/398) | [Privacy Policy \(/node/397\)](/node/397) | [End User Agreement \(/node/399\)](/node/399)

Copyright © 2020 W. H. Hendren Education Foundation for Pediatric Surgery and Urology



supangat Doctor <drsupangat@unej.ac.id>

Your Presentation for the April 23, 2020, Intl Colorectal Web Meeting

5 messages

Ray Everngam <ray@hendrenproject.org>

Thu, Apr 23, 2020 at 4:12 AM

To: dokter supangat Kedokteran <drsupangat@unej.ac.id>, Azka Darajat <azkadarajat96@gmail.com>

Dear Drs. Supangat and Darajat:

We are honored that you will again be presenting a patient case at Thursday's International Colorectal Web Meeting. Here is important information regarding your Patient Case Presentation:

YOUR PRESENTATION

Your presentation will be Cases #1.

STARTING TIME AND DAY**Thursday, April 23, 2020, 10:00 am ET (16:00 GMT/UTC) / 9:00 am CT / 8:00 am MT / 7:00 am PT [9:00 pm (EAST JAVA INDONESIA)]. Please log into the web meeting room (using the instructions below) at 8:30 pm your time on Thursday morning. We will watch for you!**

Please follow these instructions to access the web meeting room for the test and for the presentation:

Step 1. [Link to the Web Meeting](#)**Step 2.** Select "Guest"**Step 3.** Enter your name**Step 4.** Select "Enter" and you will be taken to the online web meeting room. When I see that you have arrived, I will make you a Presenter and then you can set up your webcam and microphone.

We look forward to your presentation tomorrow!

Please let me know if you have any questions.

Ray

Raymond L. Everngam
Executive Director
The Hendren Project
www.hendrenproject.org
717-579-6115



Join us on Twitter!
[@hendrenproject](#)

Ray Everngam <ray@hendrenproject.org>
To: dokter supangat Kedokteran <drsupangat@unej.ac.id>, Azka Darajat <azkadarajat96@gmail.com>

Thu, Apr 23, 2020 at 8:37 PM

Please log into the web meeting! We start soon! Thanks!

Raymond L. Everngam
Executive Director
The Hendren Project
www.hendrenproject.org
717-579-6115



Join us on Twitter!
[@hendrenproject](#)

[Quoted text hidden]

Ray Everngam <ray@hendrenproject.org>
To: dokter supangat Kedokteran <drsupangat@unej.ac.id>, Azka Darajat <azkadarajat96@gmail.com>

Thu, Apr 23, 2020 at 8:47 PM

Please login so we can set up your webcam. The web meeting starts very soon! Thank you.

Raymond L. Everngam
Executive Director
The Hendren Project
www.hendrenproject.org



Join us on Twitter!
[@hendrenproject](#)

[Quoted text hidden]

supangat MD <drsupangat@unej.ac.id>
To: Ray Everngam <ray@hendrenproject.org>

Thu, Apr 23, 2020 at 9:00 PM

I am sorry I can't enter the meeting, the connection was very poor

[Quoted text hidden]

Ray Everngam <ray@hendrenproject.org>
To: supangat MD <drsupangat@unej.ac.id>

Thu, Apr 23, 2020 at 9:29 PM

We are sorry that you were unable to attend. We will post a video soon and I will send you the link! Dr. Darajat did an excellent presentation!

Ray

On Apr 23, 2020, at 10:01 AM, supangat MD <drsupangat@unej.ac.id> wrote:

[Quoted text hidden]

Certificate of Presentation

W. H. Hendren Education Foundation for
Pediatric Surgery & Urology

hereby certifies that

Supangat, M.D., M.Sc., Ph.D., *Pediatric Surgeon*

Henggar Allest Pratama, M.D.

Dr. Soebandi General Hospital, Faculty of Medicine, University of Jember, East Java, Indonesia

presented the following patient case:

5-Year-Old Female Patient Presenting with Abdominal Pain

during the

International Colorectal Web Meeting

April 23, 2020



Case of Hirschsprung Disease

Supangat, Pediatric Surgeon
Azka Darajat, General Practitioner

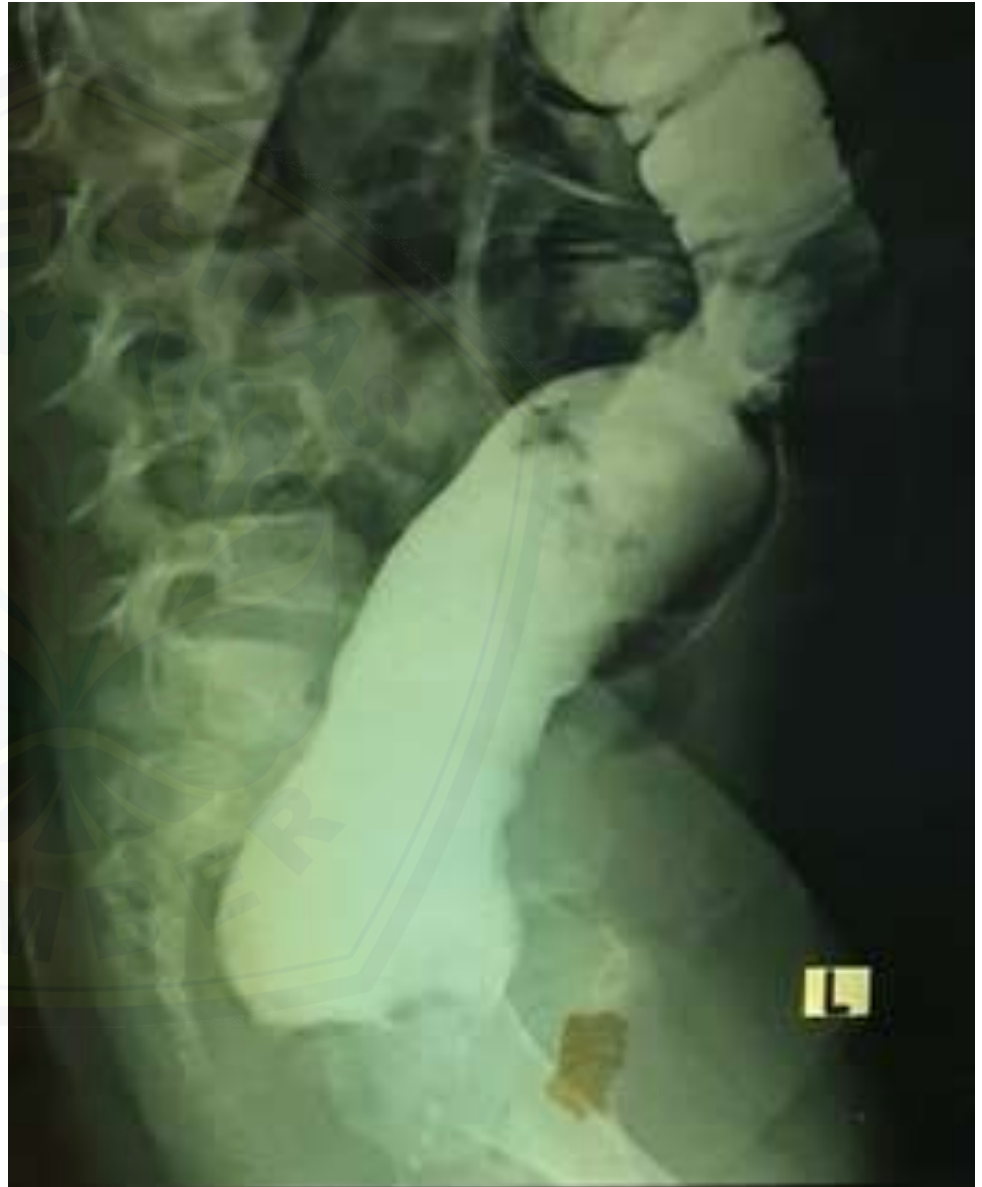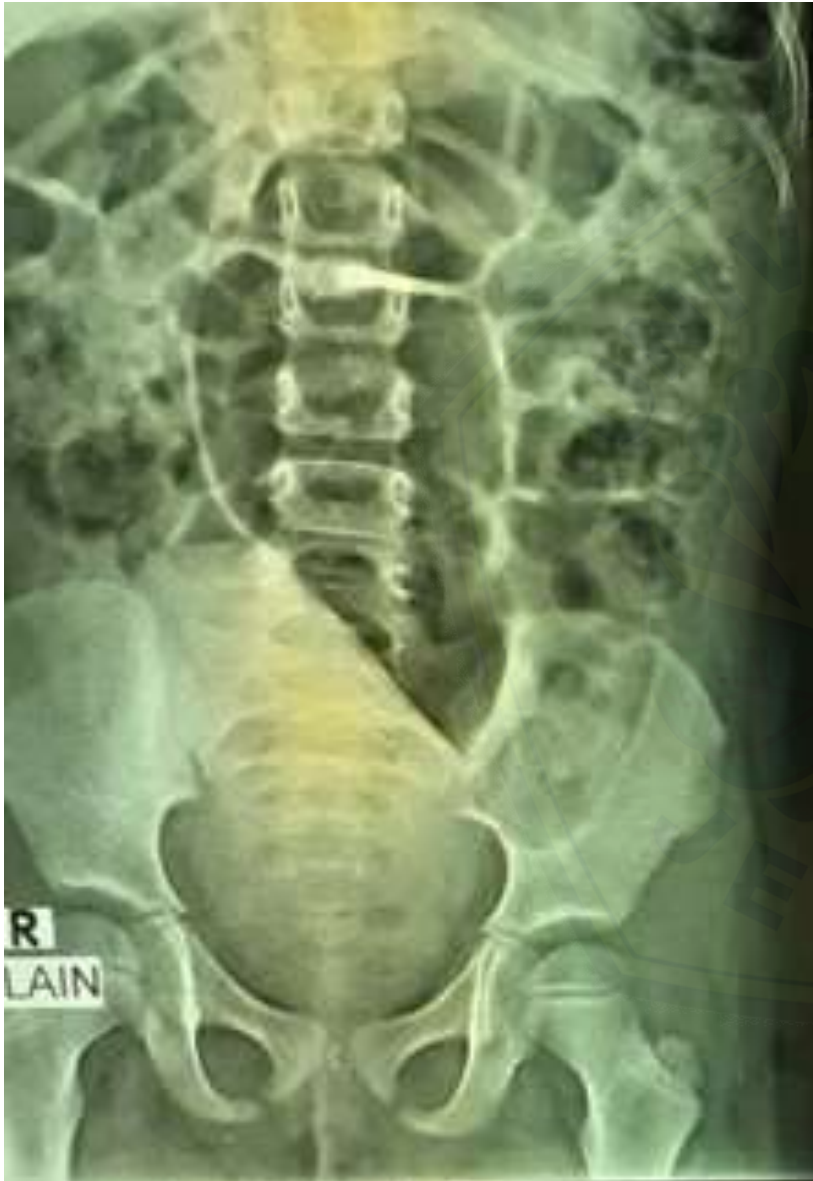dr. Soebandi General Hospital
Faculty Of Medicine
University of Jember
East Java, Indonesia

Case Presentation

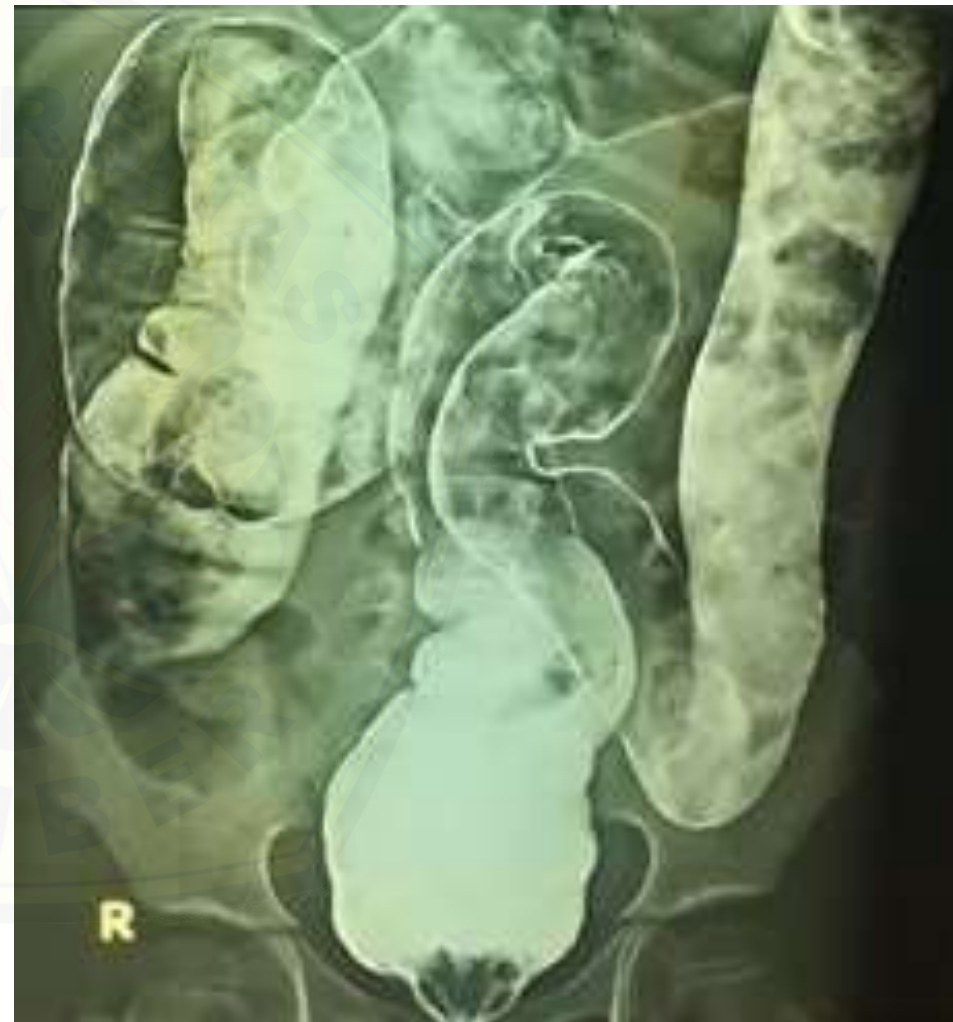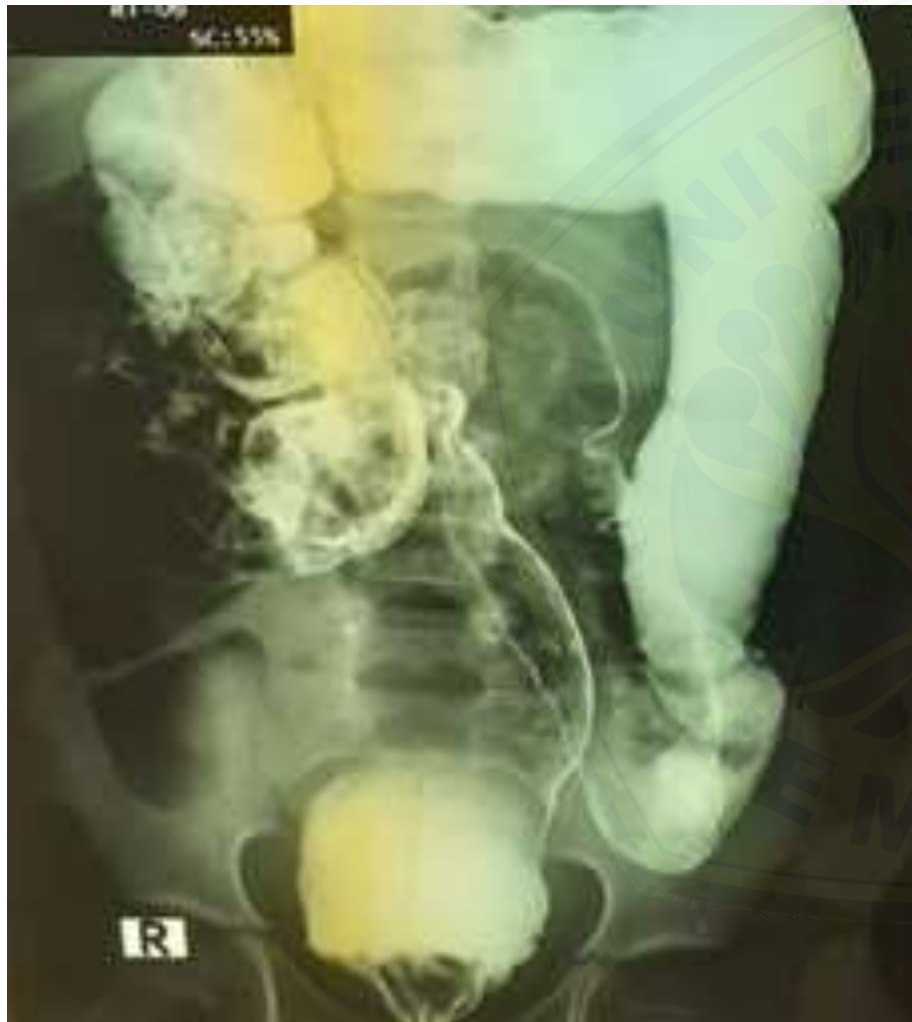- 5 years old female child
- Patient came with abdominal pain → referred to our hospital because of suspected acute appendicitis
- Leukocyte 13.000, Neutrophil 56%
- The patient had a history of delayed passage of meconium, chronic constipation, and routine use of laxative

- We suspected Hirschsprung Disease.
- An enema with NaCl 0,9% + Glycerin was given for three days
- Contrast enema was done on day 4

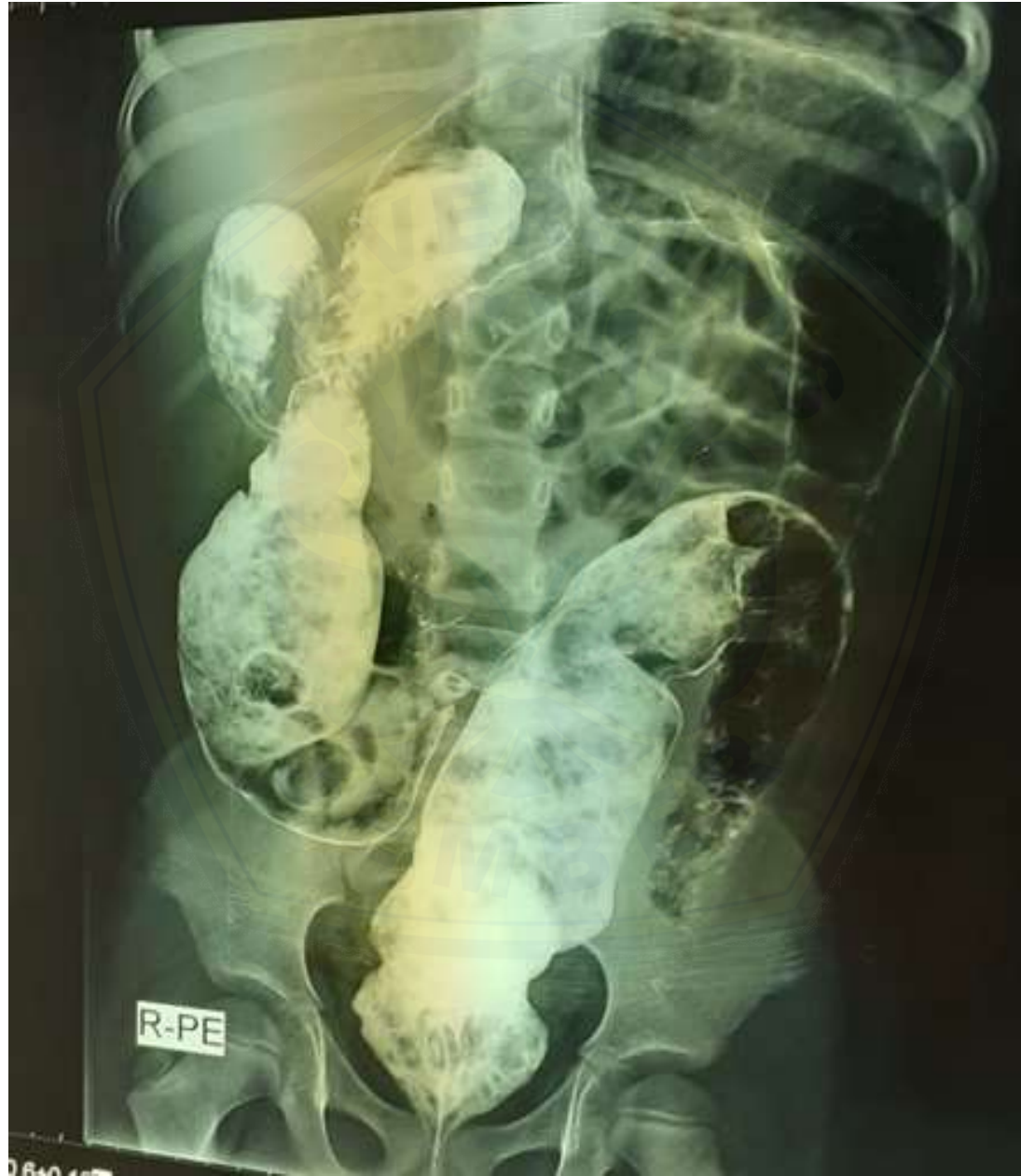Contrast Enema



Digital Repository Universitas Jember
Contrast Enema



Contrast Enema



- Patient was discharged after routine defecation on day 5
- At one month follow up → patient came with history of not passing stool for the past 4 days

Questions

- What is the diagnosis and differential diagnosis?
- Do we need to perform a rectal biopsy?
- What is better: an enema or manual fecal disimpaction under general anesthesia?
- If enemas fail, can we do a disimpaction under anesthesia?



Thank You