

Inflammatory and Immunogenic Response of the Tissue after Application of Freeze-Dried Hydroxyapatite Gypsum Puger Scaffold Compared to Freeze-dried Hydroxyapatite Bovine Scaffold

Abstract

Background: Inflammation is a mechanism or reaction of the natural immune system to defend from external hazards. All foreign objects that enter the body will trigger an immune response in the form of antibodies. In Indonesia, the prevalence of diseases that involve the inflammatory process in the body is high. Freeze-dried hydroxyapatite gypsum puger (HAGP) scaffold is a gypsum powder which is currently under development as a bone replacement material. Freeze-dried hydroxyapatite bovine (HAB) scaffold is a bone substitute material available on the market. **Objective:** To analyze the inflammatory and immunogenic responses in the tissue after application of freeze-dried HAGP scaffold compared to freeze-dried HAB scaffold through mediators of tumor necrosis factor alpha (TNF- α) and immunoglobulin G (IgG) in rats. **Materials and Methods:** This study used Wistar rats. HAGP group and HAB group were applied subcutaneously, settled for 7 and 14 days, then the levels of TNF- α and IgG were measured using enzyme-linked immunosorbent assay. Statistical analysis was done using nonparametric test with the Kruskal-Wallis test. **Results:** TNF- α levels at day 7 in the HAGP group were nearly equal to the control group, while those in the HAB group were higher. Statistically, the significance was $P = 0.184$ ($P > 0.05$). At the 14th day, the level of IgG on the HAGP and HAB groups the level was higher than the control group, statistically it was found $P = 0.127$. **Conclusion:** freeze-dried HAGP scaffold compared to freeze-dried HAB scaffold did not cause inflammatory and immunogenic response on rats through mediators of TNF- α and IgG.

Keywords: Freeze-dried hydroxyapatite gypsum puger scaffold, freeze-dried hydroxyapatite bovine scaffold, immunogenic, inflammation

Introduction

Inflammation is a mechanism or reaction of the body's natural immune system to fight and protect from irritants, microorganisms, and foreign objects. This process is a biological response to danger signals that threaten the body. Inflammatory responses generally occur if there is a foreign body that activates macrophages and other cells to produce and release various cytokines including tumor necrosis factor-alpha (TNF- α). In Indonesia, the number of diseases that involve inflammatory processes is quite high.^[1,2]

In general, all foreign objects that enter the body will trigger the emergence of the foreign body's immune response which is referred as immunogenic or antigen, which can trigger the production of antibodies. Antibodies which are

glycoproteins that produced by B cells will form immunoglobulin (Ig). There are several types of Igs, including IgG which is the most common type in the body.^[2,3] An example of foreign material that is often inserted into human body is bone replacement material.

Biomaterials serve as a medium to deliver inflammatory cells to the desired area and induce local tissue regeneration, acting as a barrier to protect cells implanted in tissues from host immune attacks, or as reactors to stimulate recruitment, and differentiation of the host cells.^[4] Biomaterials function as an integral component of tissue engineering that serves to provide the original extracellular matrix framework so that cell growth and tissue regeneration can take place.^[5]

Freeze-dried hydroxyapatite gypsum puger (HAGP) scaffold is a synthetic

Amiyatun Naini,
Mohamad
Rubianto¹,
Fourier Dzar
Eljabbar Latief²,
Achmad Gunadi,
Dewi Kristiana,
Nike Hendrijantini³,
I. Ketut Sudiana⁴

Department of Prosthodontic,
Faculty of Dentistry,
Jember University, Jember,
Departments of ¹Periodontic
and ³Prostodontic, Faculty
of Dentistry, Airlangga
University, ⁴Department of
Electron Microscope, Faculty
of Medicine, Airlangga
University, Surabaya.

²Physics of Earth and Complex
Systems, Micro-CT Laboratory,
Faculty of Mathematics and
Natural Sciences Institut
Teknologi Bandung, Bandung,
Indonesia

Submitted : 09-Dec-2019

Revised : 16-Apr-2020

Accepted : 22-Jun-2020

Published : 20-Dec-2020

Address for correspondence:

Dr. Amiyatun Naini,
Department of Prosthodontic,
Faculty of Dentistry, Jember
University, Jl. Kalimantan
37 Jember, Indonesia.
E-mail: amiyatunnaini.fkg@
unej.ac.id

Access this article online

Website:
www.contempclindent.org

DOI: 10.4103/ccd.ccd_443_19

Quick Response Code:



This is an open access journal, and articles are distributed under the terms of the Creative Commons Attribution-NonCommercial-ShareAlike 4.0 License, which allows others to remix, tweak, and build upon the work non-commercially, as long as appropriate credit is given and the new creations are licensed under the identical terms.

For reprints contact: WKHLRPMedknow_reprints@wolterskluwer.com

How to cite this article: Naini A, Rubianto M, Latief FD, Gunadi A, Kristiana D, Hendrijantini N, *et al.* Inflammatory and immunogenic response of the tissue after application of freeze-dried hydroxyapatite gypsum puger scaffold compared to freeze-dried hydroxyapatite bovine scaffold. *Contemp Clin Dent* 2020;11:371-5.

bone replacement material derived from natural gypsum powder ($\text{CaSO}_4 \cdot 2\text{H}_2\text{O}$) which is being developed as a preservation material for the alveolar bone.^[6] The freeze-dried HAGP scaffold material has been successfully synthesized by characterization using scanning electron microscopy, X-ray diffraction, and degradation test on alveolar bone sockets.^[7,8] Freeze-dried hydroxyapatite bovine scaffold (HAB) is a bone substitute available readily on the market that is used as a comparison in this research.^[9-11]

HAGP scaffold material as well as HAB scaffold contains hydroxyapatite. Hydroxyapatite ($\text{Ca}_{10}(\text{PO}_4)_6(\text{OH})_2$) is a calcium phosphate crystal that provides rigidity in bone tissue.^[12-14]

In general, a safety measurement of bone replacement material that will be used as tissue preservation needs to be conducted to make sure they are biocompatible. Biocompatibility of materials can be measured *in vivo* by observing the inflammatory and immunogenic responses to tissue.^[15,16]

The freeze-dried HAGP scaffold material has never been tested for its tissue response. Hence, it is important to conduct a research to analyze the inflammatory and immunogenic responses to tissue after application of freeze-dried HAGP scaffold in rat. The purpose of this study was to analyze the inflammatory and immunogenic responses to tissue after administration of freeze-dried HAGP scaffold through a decrease in TNF- α and IgG mediators in rat.

Materials and Methods

The research ethics test was conducted at the Faculty of Dentistry, Airlangga University. The type of research used is purely experimental. The research design used was the posttest-only control group design. This study used three groups of male *Rattus norvegicus* rats, aged 12–14 weeks, weighing 200–250 g ($n = 5$), and adapted for a week.

Preparation of freeze-dried HAGP scaffold was initialized with weighing 4 g of HAGP, diluted solid gelatin with hot water with a temperature of 600°C. The HAGP was mixed with gelatin liquid up to 10 ml, freeze-dried via freeze-drying system, crushed, milled, and sifted with particle sizes of 150–355 μm , and sterilized by Gamma radiation in BATAN. Poly ethylene glycol (PEG) then added to the HAGP scaffold, to obtain a concentration of 10% PEG we mixed liquid PEG 400 and solid PEG 4000. The resulting material then stored in a sterile container and ready for application to the subcutaneous area of rats [Figure 1].^[17,18]

The rats were anesthetized intramuscularly using ketamine 100 mg/ml and xylazine base 20 mg/ml ratio 1: 1 at a dose of 0.08–0.2 ml/kg BW. After anesthetized, they were shaved clean in the back, and an incision was made in the

subcutaneous area with the length of 0.5 mm then closed with stitches using DR SELLA Silk Braided usp 3/0 75 cm (in control group). Next, an incision was made in the subcutaneous area of the rat's back and augmentation was performed by inserting 0.1 ml of HAGP + PEG scaffold material and stitched. The comparison treatment group with HAB + PEG 0.1 ml augmentation was then sewn and waited for 7 and 14 days.

The rats were euthanized using 5 ml ether placed in a cotton inside a closed glass container and then the rats were inserted one by one for 5 min. An open thorax surgery was conducted to draw 2 ml of blood from the heart. Furthermore the determination of TNF- α levels on day 7 and IgG on day 14 were performed using enzyme-linked immunosorbent assay.

Statistical analysis

The data were tested for their normality using Shapiro–Wilk, and data distribution turned out to be abnormal, and the calculation continued using nonparametric test with the Kruskal–Wallis test.

Results

The TNF- α level on day 7 in the HAGP scaffold group was almost identical with the control group while in the HAB scaffold group the levels were higher. The normality test proved that the data is not normally distributed, then we used Kruskal–Wallis test (as nonparametric test) and statistically obtained $P = 0.184$. This means that there is no significant difference between the HAGP and HAB groups compared to the control [Table 1 and Figure 2].

The levels of IgG on day 14 in the HAGP and HAB groups both were higher than in the control group, statistically $P = 0.127$. This shows no significant difference between the HAGP and HAB groups compared to the control group [Table 2 and Figure 3].

Discussion

Inflammatory and immunogenic responses in tissue after subcutaneous application of HAGP scaffold and HAB scaffold in rat was done by observing TNF- α expression on day 7. Results TNF- α expression in the HAGP scaffold group was the same as in the control group, while in the

Table 1: Results of tumor necrosis factor- α expression

Scaffold	n	TNF- α		P
		$\bar{X} \pm \text{SD}$	Minimum-maximum	
Control	5	92.40 \pm 17.13	67.0-102.8	0.184*
HAGP	5	93.70 \pm 17.34	77.4-113.4	
HAB	5	113.05 \pm 11.45	97.2-123.0	

*There were no significant differences between the HAGP and HAB groups compared to controls. n: Number of samples; SD: Standard deviation; HAGP: Hydroxyapatite gypsum puger; HAB: Hydroxyapatite bovine scaffold; TNF: Tumor necrosis factor

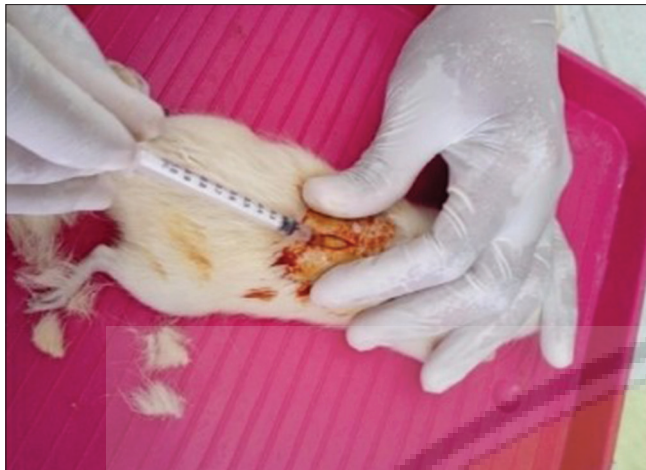

Figure 1: Scaffold application in subcutaneous rats

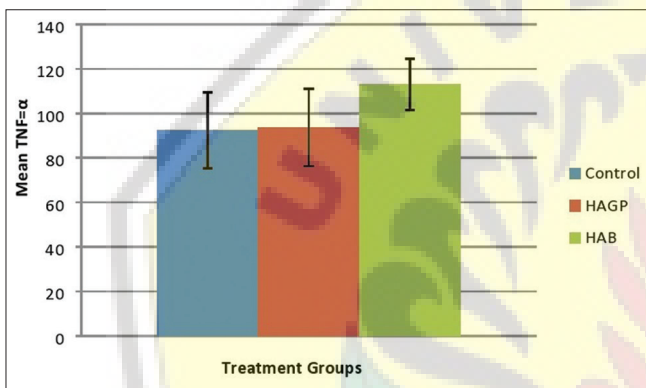


Figure 2: Bar diagram of tumor necrosis factor-alpha expression in the control group, hydroxyapatite gypsum puger scaffold and hydroxyapatite bovine scaffold

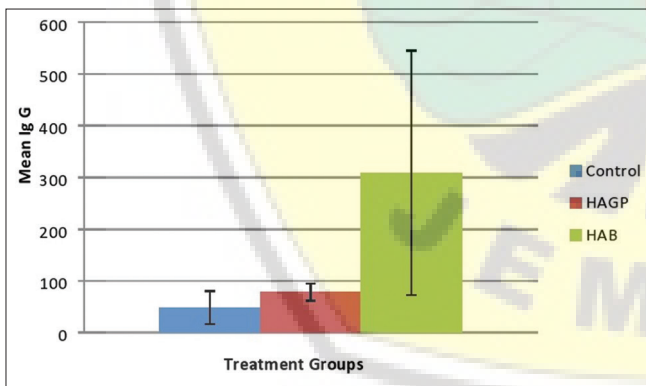


Figure 3: Immunoglobulin G levels in the control group, hydroxyapatite gypsum puger scaffold, and hydroxyapatite bovine scaffold

HAB scaffold group, the expression is higher. It is clear that higher levels of TNF- α indicate an ongoing inflammatory process. TNF- α is a pro-inflammatory mediator produced by macrophages that functions to stimulate inflammatory cells, fibroblasts, and epithelial cells. Inflammatory cells have a function to eliminate nonvital tissue and prevent invasive bacterial infections.^[19]

Table 2: Results of immunoglobulin G levels

Scaffold	n	Ig G		P
		$\bar{X} \pm SD$	Minimum-maximum	
Control	5	48.46 \pm 32.20	21.15-89.23	0.127*
HAGP	5	78.08 \pm 16.82	56.15-94.23	
HAB	5	308.75 \pm 235.98	109.23-610.54	

*There were no significant differences between the HAGP and HAB groups compared to controls. n: Number of samples; SD: Standard deviation; Ig G: Immunoglobulin G; HAGP: Hydroxyapatite gypsum puger; HAB: Hydroxyapatite bovine scaffold

An incision was made before administration of scaffold material in the subcutaneous region so that inflammation occurs in all groups of samples. Inflammation is the initial stage of a protective response from pathogens or foreign bodies, or injuries suffered by the host tissue.^[20] This process is characterized by vascular dilation, increased capillary permeability, increased blood flow and leukocytes. The inflammatory response is very important because it not only warns cells to engage in an immune response during infection but also initiates wound repair and healing process.^[21] Inflammation is marked by the presence of leukocytes, especially neutrophils, macrophages, and eosinophil.^[22]

A few minutes after the beginning of inflammation, the macrophages present in the tissue are histiocytes within the subcutaneous tissue. Macrophages will exclude important factors in inflammation such as TNF, interleukin-1, factors that stimulate granulocyte-monocyte colonies, monocyte colony-stimulating factors (CSFs) and CSF granulocytes. These factors are formed by macrophages that are activated in the tissue that undergoes inflammation, and a small number of others are formed by a network of inflamed cells, resulting in the increase of TNF- α .^[23]

Statistical analysis between the HAGP, HAB, and control groups resulting in $P = 0.184$. This shows that the HAGP and HAB groups compared to the control group were not significantly different. This means none of them induce an inflammatory response compared to control because the HAGP scaffold and the HAB scaffold contain the basic ingredients of hydroxyapatite. Hydroxyapatite material is a bioactive ceramic that has good biocompatibility and bioactivity properties, it is an excellent material used for new bone growth and able to accelerate the regeneration process of damaged bones.^[24] Hydroxyapatite in scaffold has a strong ability to stimulate cell proliferation and induce osteogenic differentiation.^[25] Scaffolds consisting of hydroxyapatite biomaterials have excellent ability in the formation of fibrous tissue between the bone implants.^[26]

TNF- α levels on day 7 are associated with osteoclast precursor recruitment and differentiation into adult osteoclasts in the defect. This is supported by other researchers that the defects are associated with TNF- α expression from the surface of osteoclast markers.^[27]

Determination of immunogenic response to tissue after application of HAGP scaffold and HAB scaffold in rat subcutaneous layer was done by observing IgG expression on day 14. Observations made on day 14 because immune reactions that cause rejection of graft material transplantation are usually happened within 10–14 days. In this study, the expression of IgG in the HAB scaffold group was higher than the HAGP scaffold and control group. This was because the HAB scaffold was hydroxyapatite from bovine bones containing protein. Exposure to this kind of protein can increase the response of IgG. The higher the amount of protein exposure, the higher the amount of IgG antibodies produced. According to Bratawidjaja and Iris (2014) the first (primary) antigen exposure activates T cells and B cells, B cells then differentiate and proliferate to produce small amounts of IgG. Whereas repeated exposure (secondary) with the same antigen will increase the proliferation of B cells to produce more IgG. IgG antibodies are the front line of adaptive immunity and specific humoral response in the body against pathogens.^[2,28]

Statistical analysis between the HAGP, HAB, and control scaffold groups results in $P = 0.127$. This shows that there was no significant difference between the HAGP and HAB groups compared to the control, which means that they did not cause an immunogenic response compared to the controls. This is because the HAGP and the HAB scaffold contain the main ingredients of hydroxyapatite. Hydroxyapatite material is biocompatible, low toxicity, biodegradable, nonimmunogenic, and noncarcinogenic.^[29] bioceramic based composite material and has a potency as a biodegradable bone implant.^[30]

Conclusion

Freeze-dried HAGP scaffold does not cause an inflammatory and immunogenic response to rats through mediators of TNF- α and IgG compared to freeze dried HAB scaffold.

Acknowledgment

The authors would like to thank to research grant supporting the IDB program University of Jember in 2019.

Financial support and sponsorship

Nil.

Conflicts of interest

There are no conflicts of interest.

References

- Janeway Charles A, Travers P, Walport M, Shlomchikn M. Immunobiology. Sec. 2-4. New York: Garland Science; 2001.
- Baratawidjaja KG, Rengganis I. Immunologi Dasar. Edisi ke-11. Fakultas Kedokteran Universitas Indonesia; 2014. p. 52
- Abbas L. Basic Immunology. Functions and Disorders of the Immune System. 2nd ed. Canada: WB Saunders Co.; 2006. p. 34.
- Kearney CJ, Mooney DJ. Macroscale delivery systems for molecular and cellular payloads. *Nat Mater* 2013;12:1004-17.
- Lee EJ, Kasper FK, Mikos AG. Biomaterials for tissue engineering. *Ann Biomed Eng* 2014;42:323-37.
- Tal H, Zvi A, Roni K, Ilan B, Goshen G. Augmentation and Preservation of the Alveolar Process and Alveolar ridge of Bone. Department of Periodontology and Dental Implantology. Tel Aviv University Israel; 2012. p. 25-30.
- Naini A, Ardhiyanto HB, Yustisia Y. Proses sintesis dan karakterisasi hydroxyapatite menggunakan analisis XRD FTIR dari gypsum puger kabupaten jember sebagai material augmentasi ridge alveolar. *J Stomatognatic (J. K. G Unej)* 2014;11:32-7.
- Naini A, Sudiana IK, Rubianto M, Ferdiansyah, Mufti N, Characterization and degradation of hydroxyapatite gypsum puger (HAGP) freeze-dried scaffold as a graft material for preservation of the alveolar bone socket. *J Internat Dent Med Res* 2018;11:532-6.
- Mahyudin F, Djoko R, Fedik AR. Aulanium. Regenerasi pada massive bone defect dengan bovine hydroxyapatite sebagai scaffold mesenchymal stem cell. *JPB* 2011;13:179-95.
- Manalu JL, Soegijono B, Indrani DJ. Characterization of hydroxyapatite derived from bovine bone. *Asian J Appl Sci* 2015;3:758.
- Puspa KA, Asmi D. Sintesis dan karakterisasi biokeramik hidroksiapatit bahan tulang sapi pada suhu 800-1100. *J Teori dan Aplikasi Fisika* 2014;2:125.
- Surbakti A, Oley MC, Prasetyo E. Perbandingan antara penggunaan karbonat apatit dan hidroksiapatit pada proses penutupan defek kalvaria dengan menggunakan plasa kaya trombosit. *J Biomed* 2017;9:137-40.
- Darwis D, Warastuti Y. Sintesis dan karakterisasi komposit hidroksiapatit (Ha) sebagai graft tulang sintetik. *J Ilmiah Aplikasi Isotop dan Radiasi* 2008;4:143-4.
- Mozartha M. Hidroksiapatit dan aplikasinya di bidang kedokteran gigi. *Cakradonya Dent J* 2015;7:807-68.
- Mahyudin F, Hermawan H. Biomaterial and Medical Devices: A Perspective from an Emerging Country. Switzerland: Springer; 2016. p. 54-5.
- Poedjijarti T. Biokompatibilitas Scaffold Hidroksiapatit-Kitosan-Kondroitin Sulfat Secara *in vivo* Sebagai Bone Graft. Thesis Thesis, Sekolah Pasca Sarjana. Universitas Airlangga; 2018.
- Desai LS, Lister L. Biocompatibility Safety Assessment of Medical Devices: FDA/ISO and Japanese Guidelines Toxikon Corp. (Bedford, MA, USA): Toxikon Corp; 2003. p. 7-8.
- KresnoadiU. Toll-Like Receptor 2 Sebagai Signaling Pathway Osteogenesis Tulang Alveolar Yang di Induksi Kombinasi Aloe Vera dan Graft. Disertasi. Fakultas Kedokteran Universitas Airlangga; 2012.
- Kumar V, Abbas AK, Aster JC, Robbin SL. Robbins Basic Pathology. 9th ed. Philadelphia: Saunders; 2013. p. 17-21.
- Marcelo OF, Thomas EV. Natural resolution of inflammation. *Periodontol* 2013;63:149-64.
- Katrin D, Mayer B, Yan B. Clash of the cytokine titans: Counter-regulation of interleukin-1 and type I interferon-mediated inflammatory responses. *Cell Mol Life Sci* 2017;14:22-35.
- Liu M, Kalbasi A, Beatty GL. Functio laesa: Cancer inflammation and therapeutic resistance. *J Oncol Pract* 2017;13:173-80.
- Hall J. Guyton dan Hall Buku Ajar Fisiologi Kedokteran Editors: M Widjajakusumah Antonia Tanzil Paperback. 12th ed. Singapore: Elsevier (Singapore) Pte Ltd Page Count.; 2014. p. 1172.
- Herliansyah MK, Candra M, Alva ET. Natural bioceramics bone

- graft: A comparative study of calcite hydroxyapatite, gypsum hydroxyapatite, bovine hydroxyapatite and cuttlefish shell hydroxyapatite. *Proceed Asia Pacific Indust Eng Manag Syst Confer* 2012;2:1137-46.
25. Li Y, Zhang Z, Zhang Z. Porous chitosan/nano-hydroxyapatite composite scaffolds incorporating simvastatin-loaded PLGA microspheres for bone repair. *Cells Tissues Organs* 2018;205:20-31.
 26. Khoiriyah M, Cahyaningrum SE. Sintesis dan karakterisasi bone graft dari komposit hidroksiapatit/kolagen/kitosan (HA/Coll/Chi) dengan metode *ex-situ* sebagai kandidat implan tulang. *Unesa J Chem* 2018;7:25-9.
 27. Cardemil C, Elgali I, Xia W, Emanuelsson L, Norlindh, Qmar Q, *et al.* Strontium-doped calcium phosphate and hydroxyapatite granule promote different inflammatory and bone remodelling responses in normal and ovariectomised rats. *Plos One* 2013;8:1-17.
 28. Male D, Brostoff J, Roth DB, Roit I. *Immunologia*. Polish ZJ, editor. Elsevier Urban & Partner: Wrocław; 2006. p. 59-86.
 29. Irawan B. Chitosan dan aplikasi klinisnya sebagai biomaterial. *Indonesian J Dent* 2005;12:146-51.
 30. Ulum MF, Arafat A, Noviana D, Yusop AH, Nasution AK, Abdul Kadir MR, *et al.* *In vitro* and *in vivo* degradation evaluation of novel iron-bioceramic composites for bone implant applications. *Mater Sci Eng C Mater Biol Appl* 2014;36:336-44.

