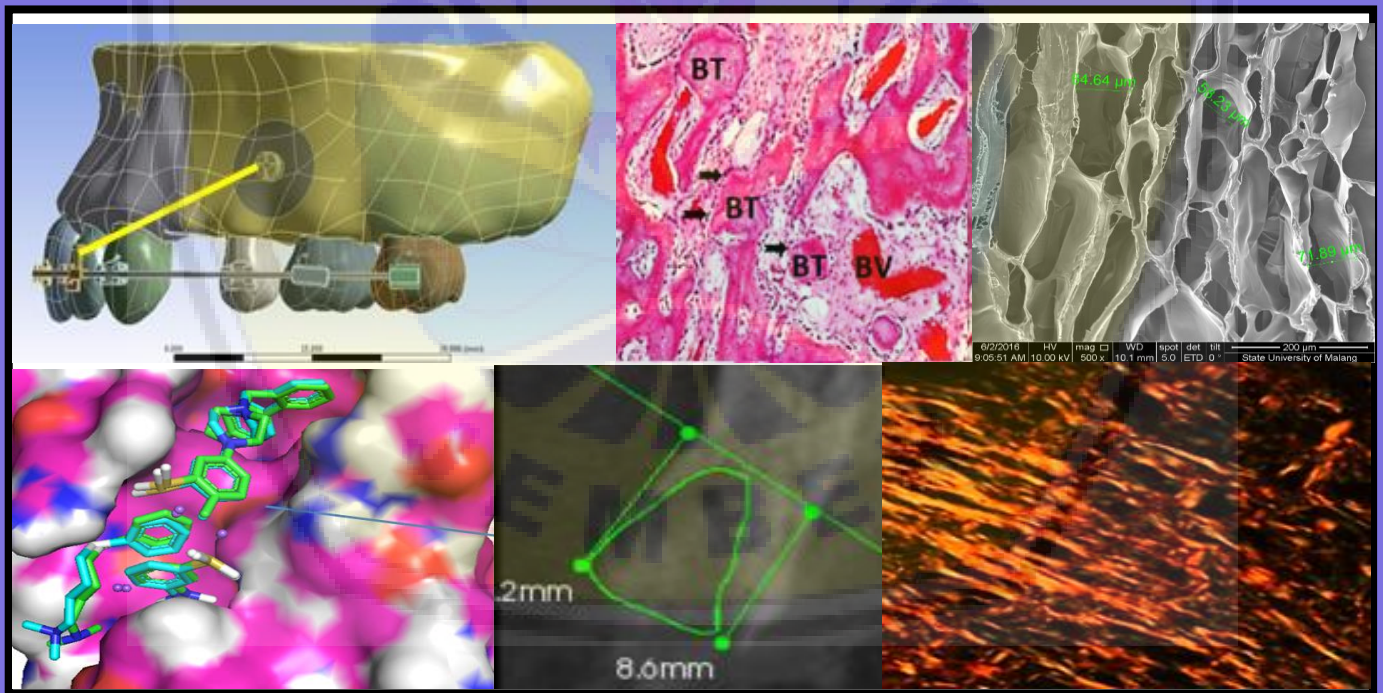


Journal of

International

Dental and Medical

Research



2019 - Vol. 12 – No. 4

<http://www.jidmr.com>

Digital Repository Universitas Jember

Journal of International Dental and Medical Research

Home page | Aims and Scope | Author Guidelines | Editorial Board | Indexing | Archive | Contact Information | Copyright Transfer Form

DENTISTRY

1. Mechanical Properties of Dental Composite Reinforced with Natural Fiber
EXPERIMENTAL ARTICLE
Goh Wan Theng, Yanti Johari, Ismail Ab Rahman, Nor Aidaniza Abdul Mutlib, Mohd Nazrulhuzaimi Md Yusuf, Rabihah Alawi
Pages 1242-1247 **Full Text PDF**

2. Frequency Distribution of Missing Teeth in Down Syndrome Children at POTADS Foundation
EXPERIMENTAL ARTICLE
Nadiya M. Alwafa, Yetty Herdiyati, Erika R, Risti SP, Willyanti Soewondo, Inne S. Sasmita
Pages 1248-1252 **Full Text PDF**

3. MTA1 Expression in Salivary Mucoepidermoid Carcinoma: with Special Emphasis on Grading Systems
EXPERIMENTAL ARTICLE

Ectodermal Dysplasia Group
Turkey
Associate Editor and Director
Assoc. Prof. Dr.
Özkan ADIGÜZEL

1_11_19_Cover JID...pdf Show all X

5:53 AM 12/31/2019

Journal of International Dental and Medical Research

Home page | Aims and Scope | Author Guidelines | Editorial Board | Indexing | Archive | Contact Information | Copyright Transfer Form

61. Applications of PEEK in Implant Retained Finger Prosthesis
CASE REPORT
Pokpong Amornvit, Dinesh Rokaya, Sasiwimol Sanohkan
Pages 1606-1609 **Full Text PDF**

62. Management of Varicella Zoster and Ulcer Manifestation in the Oral Cavity of a 5-years-old Patient
CASE REPORT
Sri Hemawati, Sulisdiyani
Pages 1610-1612 **Full Text PDF**

63. Cone Beamed Computerized Dental Tomography in Dentistry
REVIEW
Ebru Akleyin, Myroslav Goncharuk-Khomyn
Pages 1613-1617 **Full Text PDF**

1_11_19_Cover JID...pdf Show all X

5:54 AM 12/31/2019

Management of Varicella Zoster and Ulcer Manifestation in the Oral Cavity of a 5-years-old Patient

Sri Hernawati¹, Sulistiyani^{2*}

1. Department of Oral Medicine, Faculty of Dentistry, University of Jember, Jember, Indonesia.
2. Department of Pediatric, Faculty of Dentistry, University of Jember, Jember, Indonesia.

Abstract

Case study of chickenpox, Chickenpox is a primary acute viral disease caused by Varicella Zoster virus capable of becoming dormant in the nerve ganglion; attacking the skin, mucosa and mucous membranes, clinical symptoms. Chickenpox usually attacks children between the ages of 5 to 9 year. A 5-year-old boy was taken to the Oral Medicine Clinic of Dental Hospital Faculty of Dentistry University of Jember, the patient had suffered from fever for 5 days. On the third day the patient complained about many lesions appearing both inside and outside of the oral cavity. This study conducted by anamnesis and clinical examination showing fever, vesicles outside the oral cavity. The anamnesis indicated that the patient previously contracted from his schoolmates who suffered from Chickenpox, there had been 3 students suffered from Chickenpox and were in the healing stage in the time the patient started to experience early symptoms of fever and little vesicles on his back. The predisposing factors of Chickenpox infection suffered by the patient were the change of cold temperature in the rainy season, and no Chickenpox immunization got by the patient. Chickenpox immunization should be administered twice, the first at the age of 12-15 months and the second at the age of 3-5 years. The patient experienced Chickenpox with Varicella Zoster virus etiology. The treatment administered were Benzocaine Borax Glycerin as a symptomatic therapy and multivitamin Becomzet as supportive therapy.

Case report (J Int Dent Med Res 2019; 12(4): 1610-1612)

Keywords: Varicella zoster, Chickenpox, Ulcer.

Received date: 04 May 2019

Accept date: 13 July 2019

Introduction

Chickenpox is a primary infection of the Varicella Zoster virus capable of becoming dormant in the nerve ganglion.¹⁻³ Epidemiology; it commonly and frequently attacks children during the rainy season and is highly contagious. Pathogenesis; a mild prodromal image appears post exposure to the virus and incubation period is 2-3 weeks. The spread of infection through direct contact or droplet infection first involves the upper respiratory tract. Touching ruptured vesicular fluids can also be contagious. Infection during pregnancy will pose a significant risk to the fetus.

Chickenpox mainly attacks children under

10 years old, the most aged 5-9 years. Varicella is a highly contagious disease, 75% of children are contracted after transmission. Chickenpox is transmitted from respiratory secretions, spit sparks, contact with vesicle fluid lesions, pustules, and pregnancy or transplacental.

Individuals with zoster can also spread the varicella virus. Incubation period is 11-21 days. The infected individuals become very infective for about 24-48 hours. It usually takes around 5 days from pre-occurrence of skin lesion until the lesion becomes crusted.⁴⁻⁸

Varicella zoster virus enters through the upper respiratory tract, or after the patient has contacted with skin lesions during the incubation period of primary viremia. The early infection occurs in the upper respiratory tract and spreads and becomes primary viremia. In this phase the virus spreads through the bloodstream and lymphatic system.²

Chickenpox clinical manifestations consist of 2 phases i.e. prodromal phase and eruption phase. In the prodromal phase, an individual suffers from mild fever for 1-3 days, shivering,

*Corresponding author:

Sulistiyani

Department of Pediatric,

Faculty of Dentistry, University of Jember,
Jember, Indonesia.

E-mail: sulistiyani.fkg@unej.ac.id

anorexia headaches, and malaise. In the eruption phase, skin rashes like "dew drops on rose petals" appear and are scattered on the face, neck, and scalp and quickly spread to whole body surface and lead to extremities. The spread is centrifugal (from the center), and the macula subsequently turns into papules, vesicles, pustules, and crusts accompanied by feeling of itchy. This change lasts only in 8-12 hours. During its attack, therefore, Chickenpox results in some manifestations e.g. papules, vesicles, and crusts all at once called polymorph.⁵

Case Report

A 5-year-old male patient was taken to the Oral Medicine Clinic, the Dental Hospital, Faculty of Dentistry, the University of Jember complaining about the ulcers in the upper left lip, inner cheek, and on the right and left lower parts of tongue. The patient felt pain and discomfort while eating and drinking. Before the ulcers appeared the patient had suffered from fever. The ulcer appeared after suffering from smallpox five days ago. He had never had medication on his disease before coming to the Dental Hospital.

Based on extra oral examination, vesicles had been found to spread throughout the patient's body some of which had crusted, and there were ulcers in the upper left labial mucosa less than 2 mm in diameter. The ulcers were marked with clear boundaries, erythema, and white pseudomembrane in the middle of the ulcer, and felt painful.

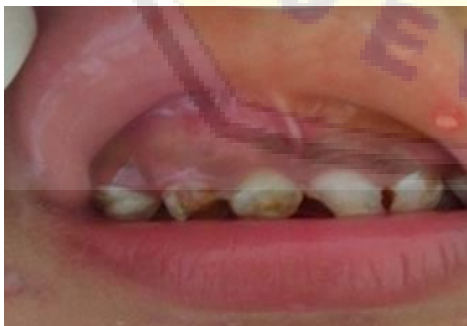

Figure 1. Early photo before Treatment.

The management of Chickenpox suffered by the patient was conducted by cleansing and drying the lesion using a sterile cotton roll and sterile cotton pellet, and antiseptic application. The lesion was subsequently smeared using Benzocaine, Borax, and Glycerin and allowed for

5 minutes. The patient was provided Benzocaine Borax Glycerin, applied 3 times a day, as home medication, and multivitamin once a day, 5 x 1 tablets of acyclovir for 7 days, and acyclovir ointment for extra oral lesions. The patient was instructed to use the medicines as recommended, to maintain oral hygiene, to eat nutritious foods (high protein), to have adequate rest, and to ask for check up after a week.

The patient came to the Dental Hospital for check up after six days. Anamnesis conducted showed that the patient did not feel pain any more on his oral cavity, and extra oral lesions were disappeared. Benzocaine Borax Glycerin provided was nearly used up, and multivitamins left only one tablet. Intraoral examination showed no more ulcers in the oral cavity.

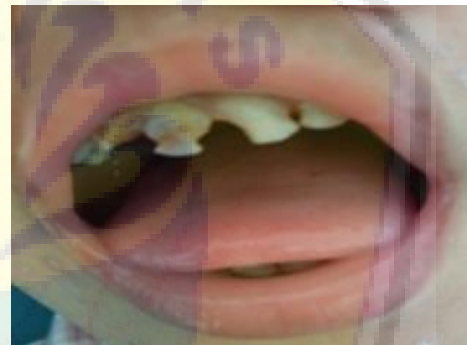


Figure 2. The photograph after checkup (D+ 6 treatments).

Based on the results of the check up, the treatment using Benzocaine Borax Glycerin was discontinued, while multivitamin administration was continued. The patient was instructed to maintain his oral cavity, to eat nutritious food, and to have adequate rest.

Discussion

In the case, the diagnosis is made based on the results of the patient's anamnesis and clinical examination. The anamnesis indicated that the patient previously contracted from his schoolmates who suffered from Chickenpox, there had been 3 students suffered from Chickenpox and were in the healing stage in the time the patient started to experience early symptoms of fever and little vesicles on his back.

The predisposing factors of Chickenpox infection suffered by the patient were the change of cold temperature in the rainy season, and no Chickenpox immunization got by the patient.

Chickenpox immunization should be administered twice, the first at the age of 12-15 months and the second at the age of 3-5 years.⁶

Clinical examination in the oral cavity observed a manifestation of Chickenpox in the left upper left labial mucosa, left cheek mucosa, and left and right parts of lower tongue with average diameters less than 2 mm. The ulcer in the oral cavity showed erythema at the outer periphery of the ulcer, clear border, and a white pseudomembrane in the center of the ulcers, therefore the ultimate diagnosis of the ulcer was Chickenpox. The spread of skin lesions from Chickenpox is generally first in the area of the body then spread centrifugally to the face and extremities, as well as the typical lesions like tear drops. The skin lesions of varicella can also attack the mucous membranes, eyes, oral cavity, and upper respiratory organs. Before oral lesions appear, a patient will feel pain, and the lesion begins with vesicles which then rapidly burst into erosion and become ulcers with reddish inflamed edges.^{2,5}

The treatment plan and therapy performed were symptomatic therapy aiming at reducing pain, shortening the duration of the lesion, and extending the interval for lesion occurrence by using Benzocaine Borax Glycerin (BBG) applied to the ulcer three times a day. Supportive therapy was administered using multivitamin Becomzet tablets with once a day. Benzocaine Borax Glycerin contains benzocaine which serves as a local anesthetic to relieve pain in the ulcer, borax is bactericidal which functions to kill bacteria found in the ulcer thus the spread of secondary infection can be prevented, and glycerin serves as a solvent of both materials.^{1,9}

Supportive therapy Becomzet tablets contain vitamin C, vitamin B1, vitamin B2, vitamin B12, functioning as immune and regeneration of cells in the healing process, vitamin C serves as a collagen-forming compound which is an important protein composing skin tissue, bones, joints. The high antioxidants in vitamin C may also destroy free radicals that may damage cells in the body. The Vitamin B1 or thiamin converts carbohydrates into energy, optimizes brain function and nerves while vitamin B12 is very important to one's body to help DNA formation and red blood cells, maintain healthy nerves and other body functions. Action mechanism of acyclovir; thymidine, kinase, viral (HSV-1, HSV-2 and HZV) convert acyclovir into monophosphate

acyclovir and afterwards is converted to acyclovir diphosphate with guanylate cellular kinase into acyclovir triphosphate by phosphoglycerate kinase, phosphoenolpyruvate carbokinase, and pyruvate kinase. Acyclovir triphosphate competitively inhibits DNA of virus and competing with natural deoxyguanosine triphosphate, to be penetrated into DNA of the virus. Once penetrated, acyclovir triphosphate inhibits DNA synthesis by acting as a chain terminator. The patient was instructed to use the recommended medicines, to maintain oral hygiene, to eat nutritious foods (high protein), and to have adequate rest.^{7,9}

Virus infections is not like bacteria that consist of a single cell and is able to grow independently.¹⁰ The host will destroy virally infected cell in order to eliminate the virus. Virally infection generally affects younger age groups.¹⁰ Clinically, herpes zoster has prodromal symptom, painfull, and there are lesions on one side of trigeminal nerve.¹¹

Conclusion

It can be concluded that the patient experienced Chickenpox with Varicella Zoster virus etiology. The treatment administered were Benzocaine Borax Glycerin as a symptomatic therapy and multivitamin Becomzet as supportive therapy.

References

1. Apriasar, Baharuddi ML. Oral cavity infections diseases. 1st ed. Yuma Pustaka 2010;7-9. (in Indonesia)
2. Handoko RP. Viral diseases in dermatology and venereal diseases. 6th ed. Jakarta: Balai Penerbit FKUI 2010;107-15. (in Indonesia)
3. Crispian S. Oral and Maxillofacial Medicine. The Basis of Diagnosa and Treatment. Churchill Livingstone 2nd ed 2008;234-70.
4. Harahap M. Varicella in dermatology diseases. Jakarta: Gramedia 2009;127-28. (in Indonesia)
5. Sterling JC, Kuitz JB. Viral Injection (varicella and zoster). Textbook of dermatology 6th ed. Oxford Blackwell Science 2006;995-1095.
6. Wolff K, Johnson RA. Fitzpatrick's Color Atlas and Synopsis of Clinical Dermatology 6th ed. McGraw-Hill Education 2009;831-5.
7. Yanhendri, Satya WY. Various of topical and dermatology drug preparation. Padang: Fakultas Kedokteran Universitas Andalas 2012;39(6):423-30. (in Indonesia)
8. Micheal AO, Lewis, Philip, Lamey J. Clinical oral medicine. Penerbit Widya Medika 2012;37-57. (in Indonesia)
9. Michael AO, Lrichard CKJ. Oral medicine, diagnosis and therapy. Manson Pub Ltd 2012;15-36. (in Indonesia)
10. Fajriani. Management of angular cheilitis in children. Faculty of Dentistry; Hasanuddin University. J Dentomaxillofac Sci 2017;2(1):1-3.
11. Jusri M, Erni M. Clinical diagnosis of herpes zooster (case report). Faculty of Dentistry; Hasanuddin University. J Dentomaxillofac Sci 2011;10(3):161-5. (in Indonesia)