

## Effects of hydroxyapatite gypsum puger scaffold applied to rat alveolar bone sockets on osteoclasts, osteoblasts and the trabecular bone area

Amiyatun Naini,<sup>1</sup> I Ketut Sudiana,<sup>2</sup> Moh. Rubianto,<sup>3</sup> Utari Kresnoadi,<sup>4</sup> and Faurier Dzar Eljabbar Latief<sup>5</sup>

<sup>1</sup>Department of Prosthodontics, Faculty of Dentistry, Universitas Jember, Jember – Indonesia

<sup>2</sup>Department of Electron Microscopy, Faculty of Medicine, Universitas Airlangga, Surabaya – Indonesia

<sup>3</sup>Department of Periodontics, Faculty of Dental Medicine, Universitas Airlangga, Surabaya – Indonesia

<sup>4</sup>Department of Prosthodontics, Faculty of Dental Medicine, Universitas Airlangga, Surabaya – Indonesia

<sup>5</sup>Micro-CT laboratory, Faculty of Mathematics and Natural Sciences, Institut Teknologi Bandung, Bandung – Indonesia

### ABSTRACT

**Background:** Damage to bone tissue resulting from tooth extraction will cause alveolar bone resorption. Therefore, a material for preserving alveolar sockets capable of maintaining bone is required. Hydroxyapatite Gypsum Puger (HAGP) is a bio-ceramic material that can be used as an alternative material for alveolar socket preservation. The porous and rough surface of HAGP renders it a good medium for osteoblast cells to penetrate and attach themselves to. In general, bone mass is regulated through a remodeling process consisting of two phases, namely; bone formation by osteoblasts and bone resorption by osteoclasts. **Purpose:** This research aims to identify the effects of HAGP scaffold application on the number of osteoblasts and osteoclasts, as well as on the width of trabecular bone area in the alveolar sockets of rats. **Methods:** This research used Posttest Only Control Group Design. There were three research groups, namely: a group with 2.5% HAGP scaffold, a group with 5% HAGP scaffold and a group with 10% HAGP scaffold. The number of samples in each group was six. HAGP scaffold at concentrations of 2.5%, 5% and 10% was then mixed with PEG (Polyethylene Glycol). The Wistar rats were anesthetized intra-muscularly with 100 mg/ml of ketamine and 20 mg/ml of xylazine base at a ratio of 1:1 with a dose of 0.08-0.2 ml/kgBB. Extraction of the left mandibular incisor was performed before 0.1 ml preservation of HAGP scaffold + PEG material was introduced into the extraction sockets and suturing was performed. 7 days after preparation of the rat bone tissue, an Hematoxylin Eosin staining process was conducted in order that observation under a microscope could be performed. **Results:** There were significant differences in both the number of osteoclasts and osteoblasts between the 2.5% HAGP group, the 5% HAGP group and the 10% HAGP group ( $p = 0.000$ ). Similarly, significant differences in the width of the trabecular bone area existed between the 5% HAGP group and the 10% HAGP group, as well as between the 2.5% HAGP group and the 10% HAGP group ( $p=0.000$ ). In contrast, there was no significant difference in the width of the trabecular bone area between the 2.5% HAGP group and the 5% HAGP group. **Conclusion:** The application of HAGP scaffold can reduce osteoclasts, increase osteoblasts and extend the trabecular area in the alveolar bone sockets of rats.

**Keywords:** alveolar bone; osteoblasts; osteoclasts; scaffold hydroxyapatite gypsum puger; sockets

**Correspondence:** Amiyatun Naini, Department of Prosthodontics, Faculty of Dentistry, Universitas Jember, Jl. Kalimantan 37, Jember 68121, Indonesia. E-mail: amiyatunnaini@yahoo.com

### INTRODUCTION

The post-extraction bone tissue healing process which begins in the alveolar socket area is characterized by bone remodeling, involving a cycle of bone resorption and bone formation.<sup>1</sup> The bone structure that remains after the healing process will experience progressive resorption triggered by

osteoclasts. Resorption in the first six months after tooth extraction is usually extremely rapid, but subsequently decelerates and continues to a limited extent physiologically for the remainder of the life of the tissue.<sup>2</sup>

Damage to bone tissue due to tooth extraction will cause alveolar bone resorption. In the field of dentistry, this process can influence the prognosis arrived at by

prosthodontic treatment clinics. Histologically, active bone formation occurs two weeks after tooth extraction, with the socket being filled with new bone within six months.<sup>3,4</sup>

Furthermore, bone formation results from a complex cascade involving the proliferation of mesenchymal stem cells and differentiation of osteoblast precursor cells, in addition to the maturing of osteoblasts, matrix formation and, finally, mineralization. Osteoblasts move towards the base of the resorption cavity and then form osteoid which initiates mineralization lasting 13 days. Osteoblasts are continuously formed and osteoid mineralization occurs until the cavity is filled. Some osteoblasts differentiate into osteoid and attach to the matrix.<sup>5</sup> It can be said that bone mass is regulated through a remodeling process involving two phases, namely; bone formation by osteoblasts and bone resorption by osteoclasts.<sup>6</sup>

In the field of prosthodontics, maintaining alveolar bone after tooth extraction should be prioritized to support the manufacture of conventional prostheses as well as the placement of implants.<sup>3</sup> Therefore, bone substitution material containing graph material is required for the preservation of alveolar sockets.<sup>7,8</sup>

One graph material developed as a synthetic biomaterial is hydroxyapatite with the chemical formula  $\text{Ca}_{10}(\text{PO}_4)_6(\text{OH})_2$ .<sup>9</sup> Hydroxyapatite also plays a role in the bone regeneration process, including osteointegration since it possesses osteoconductive properties that can stimulate mesenchymal cells to proliferate and differentiate during the bone regeneration process. The interconnected porous hydroxyapatite can even form a bond between extremely strong bones and accelerate the vascular procedure. Nevertheless, the dimension and shape of the pore are also considered to be important factors in the osteointegration process. Hydroxyapatite interconnects pores with rough surfaces and, therefore, facilitates penetration of osteoblast cells and becomes a supportive medium for osteoblast cells to attach to the surface of the bone graft matrix.<sup>10</sup>

Previous research has indicated that hydroxyapatite can be synthesized from gypsum produced at Gamping mountain in Puger sub-district. Consequently, hydroxyapatite gypsum puger (HAGP), can be used as an alternative bioceramic material in the preservation of alveolar sockets.<sup>11</sup> Unfortunately, the effects of HAGP scaffold as alveolar socket preservation material on the number of osteoblasts and osteoclasts as well as the width of trabecular area have not yet been comprehensively investigated. As a result, this research aimed to identify the effects of scaffold HAGP application on the number of osteoblasts and osteoclasts as well as the width of the trabecular area in the alveolar bone remodeling process involving alveolar sockets in rats.

## MATERIALS AND METHODS

Ethical approval for this research was obtained from the Research Ethics Committee of the Faculty of Dental Medicine, Universitas Airlangga (Number: 247/KKEPK.

FKG/X/2016). This research was a pure experimental study with Postest Only Control Group Design. The number of research samples totaled eighteen divided into three groups, each of which contained six members.

This research employed Hydroxyapatite Gypsum Puger (HAGP) and gelatin to form a hydrogel for the manufacture of HAGP scaffold. 10 g of solid gelatin was melted in hot water at a temperature of 60°C to form 10% liquid gelatin. Four grams of hydroxyapatite was subsequently mixed with 10ml of the liquid gelatin, before being frozen and dried using a sublimation/freeze dried system. Thereafter, HAGP particles were crushed, milled and sifted to a particle size of 150-355 µm at the Tissue Bank of Dr. Soetomo General Hospital, Surabaya.

HAGP scaffold at a concentration of 2.5% was prepared by mixing 0.05 grams of HAGP scaffold and 0.45 grams of polyethylene glycol (PEG). HAGP scaffold at a concentration of 5% was then prepared by mixing 0.05 grams of HAGP scaffold and 0.95 grams of PEG. HAGP scaffold at a concentration of 10% was prepared by mixing 0.05 grams of HAGP scaffold and 1.95 grams of PEG. PEG was produced by mixing 3.92 grams of PEG 400 (solid) with 0.98 grams of PEG 4000 (liquid). All ingredients were then placed in a sterile container in preparation for application to the sockets of the rats.

The Wistar rats were anesthetized intra-muscularly with 100 mg/ml of ketamine and 20 mg/ml of xylazine base at a ratio of 1:1 and a dose of 0.08-0.2 ml/kgBM. After the subjects had been anesthetized, their left mandibular incisor was extracted with a needle holder. 0.1 ml of HAGP scaffold + PEG material was then applied to the extraction socket which was sutured with 75 cm of DR SELLA Silk Braided usp 3/0.

Seven days later, the subjects were sacrificed by means of a cotton swab moistened with ether and placed in a sealed glass box container for five minutes. Their left lower jaw was carefully cut posteriorly from the anterior and then washed with PBS before the tissue was fixated in a 10% formalin buffer for 24 hours. Alveolar bone demineralization was then carried out using 15% EDTA solution for 4-6 weeks (the solution being replaced once every three days). Once the tissues had softened, they were processed into paraffin blocks.

The soft tissues were washed with PBS at pH 7.4 three times for five minutes. Dehydration using alcohol was performed at multilevel concentrations (70%, 80%, 96% and absolute) for 60 minutes in each case. Clearing was then effected with xilol on two occasions times each of 60 minutes' duration prior to infiltration with soft paraffin being conducted for 60 minutes at a temperature of 58-60°C. Blocking was carried out for a day inside the hard paraffin in the molds. On the following day, the soft tissues were affixed to the holder and cut into pieces 4-6 microns wide with a rotary microtom. Mounting on glass objects was subsequently performed using adhesive material. Thereafter, they were sliced and put into a hot plate and then colored with hematoxylin-eosin (HE).

The HE staining was carried out to enable observation of osteoblasts and osteoclasts. The slides were washed with PBS at pH 7.4 three times for five minutes, before being colored with hematoxilen for ten minutes, soaked in tap water for the same period of time and rinsed with H<sub>2</sub>O. Dehydration was conducted with 30% and 50% alcohol for five minutes respectively. The slides were colored with hematoxilen solution for 15 minutes, washed with running water and stained with Eosin solution for three minutes. They were rinsed with 70%, 80%, 90% and 95% alcohol twice and with xylol three times. Mounting was carried out with an entanglement and they were covered with a glass cover before being observed through a microscope.

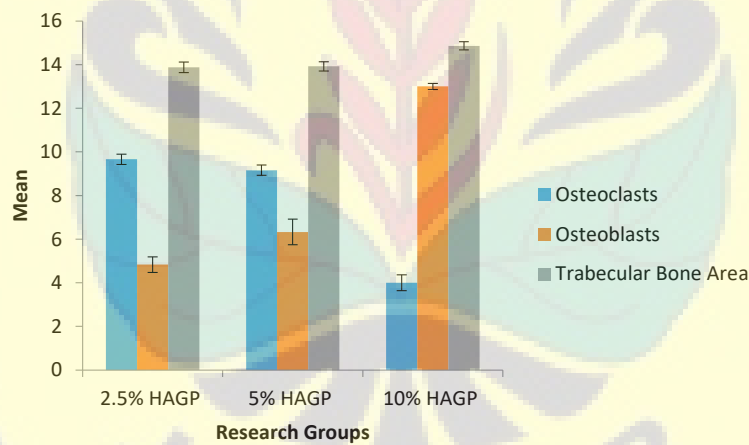
The number of osteoblasts and osteoclasts in the alveolar bone tissue incisions taken from the alveolar socket areas was measured using the HE method and observed from 10 visual fields under a light microscope at 400x magnification. The trabecular area width was also measured by calculating the width of the trabecular bone formed in the alveolar socket area using HE preparations using an Optilab microscope camera and Raster 3.0 image software. Finally, statistical analysis was performed using a one-way ANOVA test with a significance level of less than 0.05 ( $p < 0.05$ ).

**RESULTS**

The mean number of osteoblasts and osteoclasts, as well as the mean trabecular area width in the 2.5% HAGP group, the 5% HAGP group and the 10% HAGP group can be seen in Table 1 and Figure 1. The same superscript indicated no difference between groups when multiple LSD comparisons were made.

The results of the ANOVA test on the number of osteoclasts and osteoblasts as well as the width of the trabecular bone area indicated a p value of 0.000. This means that there was a significant difference between the 2.5% HAGP group, the 5% HAGP group and the 10% HAGP group. Consequently, an LSD multiple comparison test was conducted to identify any differences between two of the research groups.

The LSD test results relating to the number of osteoclasts confirmed that there were significant differences between the 2.5% HAGP group and the 5% HAGP group with a p value of 0.034, between the 2.5% HAGP group and the 10% HAGP group with a p value of 0.000, as well as between the 5% HAGP group and the 10% HAGP group with a p value of 0.000. Similarly, there were significant differences in the number of osteoblasts between the 2.5%



**Figure 1.** The histogram of the mean number of osteoblasts and osteoclasts as well as the mean width of trabecular bone area in each research group.

**Table 1.** The mean and standard deviation of the number of osteoclasts and osteoblasts as well as the width of trabecular area in each research group.

Groups	2.5% HAGP	5% HAGP	10% HAGP	Levene test	ANOVA
	X±SD, Shapiro wilk	X±SD, Shapiro wilk	X±SD, Shapiro wilk		p
Osteoclasts	9.67±0.235 <sup>a</sup> . 0.167	9.17±0.235 <sup>a</sup> . 0.167	4.00±0.359 <sup>b</sup> . 0.561	0.727	0.000
Osteoblasts	4.83±0.357 <sup>a</sup> . 0.578	6.33±0.592 <sup>b</sup> . 0.399	13.00±0.138 <sup>c</sup> . 0.683	0.205	0.000
Trabecular	13.88±0.242 <sup>a</sup> . 0.198	13.92±0.208 <sup>a</sup> . 0.550	14.86±0.189 <sup>b</sup> . 0.365	0.908	0.000

Note: significance at  $\alpha=0.05$



HAGP group and the 5% HAGP group with a p value of 0.001, between the 2.5% HAGP group and the 10% HAGP group with a p value of 0.000, as well as between the 5% HAGP group and the 10% HAGP group with a p value of 0.000. There were also significant differences in the width of trabecular bone area between the 2.5% HAGP group and the 10% HAGP group with a p value of 0.000 as well as between the 5% HAGP group and the 10% HAGP group with a p value of 0.000.

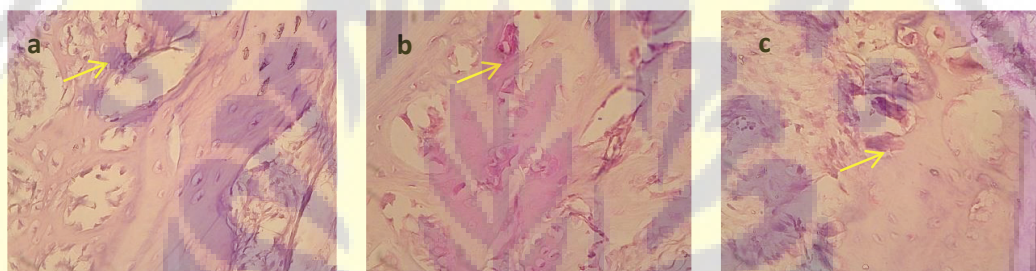
Histopathological Anatomy descriptions showed osteoclast to be a multinucleated giant cell (Figure 2), osteoblast to be a flat to round nucleated single nucleus (Figure 3) and the trabecular bone area to be the hollow section of the bone (Figure 4).

## DISCUSSION

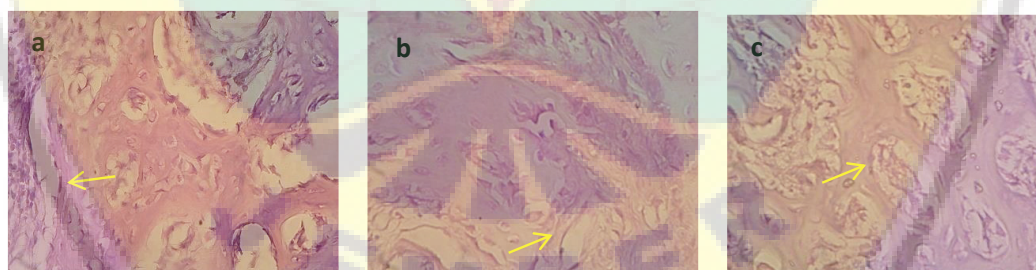
In this research, HAGP scaffold at respective concentrations of 2.5%, 5% and 10% was employed to determine the

appropriate and optimal concentration capable of increasing osteoblasts, extending the trabecular bone area and reducing the number of osteoclasts. It was demonstrated that, at the optimal concentration of 10%, HAGP scaffold can increase osteoblasts, extend the trabecular bone area and decrease osteoclasts at concentrations higher than 5% and 2.5%.

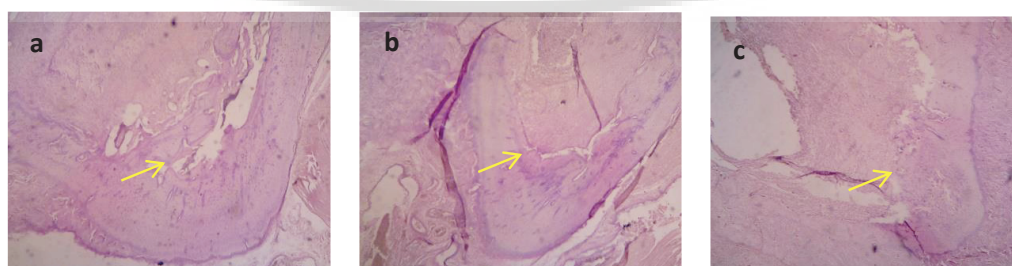Osteoblast and osteoclasts are the main components that play a role in bone remodeling. Osteoblasts act as new bone formation, whereas osteoclasts are active in bone resorption processes.<sup>6,12</sup> Hydroxyapatite (HA), already known as a biomaterial in the biocompatible health field, constitutes a major constituent of bone material with specific properties such as the ability to promote chemical attachment to bone as well as that of reducing toxicity and inflammation. Moreover, HA also possesses osteoconductive properties capable of stimulating mesenchymal cells to proliferate and differentiate as part of the bone regeneration process and osteoprogenitor cells which are considered active precursors of osteoblasts.<sup>10,13</sup>



**Figure 2.** Accumulation of osteoclasts on the socket wall during microscopic observation at 400X magnification, in groups: (a) 2.5% HAGP; (b) 5% HAGP; and (c) 10% HAGP.



**Figure 3.** Accumulation of osteoblasts on the socket wall during microscopic observation at 400X magnification, in groups: (a) 2.5% HAGP; (b) 5% HAGP; and (c) 10% HAGP.



**Figure 4.** Accumulation of trabecular area on the socket wall during microscopic observation at 400X magnification, in groups: (a) 2.5% HAGP; (b) 5% HAGP; and (c) 10% HAGP.

The contents of Table 1 indicate that the higher the concentration of scaffold, the greater the increase in the number of osteoblasts and the more pronounced the reduction in the number of osteoclasts. In the initial phase, osteoblasts express RANKL and stimulate the osteoclastogenic cascade. Calcium released from the bone during resorption produces osteoclast apoptosis. As a result, osteoclastic differentiation is suppressed and bone formation is increased. Osteoprotegrin produced by osteoblasts then prevents the interaction of RANK with RANK Ligands. Osteoprotegrin activity in osteoclast precursors (RANK) inhibits osteoclastic formation.<sup>14–16</sup>

Osteoblasts are commonly known as bone-forming cells derived from osteoprogenitor mesenchymal stem cells. Osteoprogenitor cells, through calcium pathways or bone morphogenic protein (BMP) pathways, form and differentiate osteoblasts. The main function of osteoblasts is the formation of a bone matrix. Osteoblasts also secrete certain products, such as collagen type I and type V, proteoglycans and non-collagen proteins (sialoprotein and osteopontin). On the other hand, osteoclasts, play a role both physiological and pathological in bone resorption. Osteoclasts are derived from hematopoietic stem cells, their main function being in the resorption of bone matrix mineralized by the breakdown of hydroxyapatite crystals and organic matrix cleavage.<sup>14,17</sup>

In addition, the bone formation measurement results relating to post-extraction tooth sockets in rats indicated that HAGP scaffold induction could have a positive effect on osteoblast response, thereby improving the physical properties of bone. Similarly, research conducted by Nishida *et al.* (2016), argues that Graphene Oxide scaffold can increase osteoblast proliferation.<sup>18</sup>

Functionally, the surface of HAGP is required for the interaction of cations and anions in order that calcium absorption can be increased. Ca ions can actually stimulate bone marker expression in osteoblasts, stimulate alkaline activity and also adapt to the in-vivo environment for bone regeneration.<sup>19</sup> Accumulation of Ca in HAGP scaffold may even provide a favorable environment for bone tissue formation with the result that HAGP scaffold is expected to have clinical applications in post-tooth extraction. These results indicate that HAGP scaffold has high bone formation ability and is also expected to be useful for bone remodeling, especially for bone tissue engineering therapy. Finally, it can be concluded that HAGP scaffold at a concentration of 10% can increase osteoblasts, extend bone trabecular area and decrease osteoclasts in the alveolar bone of teeth sockets of rats more than that at concentrations of 5% and 2.5%.

## REFERENCES

1. Yang X, Qin L, Liang W, Wang W, Tan J, Liang P, Xu J, Li S, Cui S. New Bone Formation and Microstructure Assessed by Combination of Confocal Laser Scanning Microscopy and Differential Interference Contrast Microscopy. *Calcif Tissue Int.* 2014; 94(3): 338–47.
2. Sadr K, Aghbali A, Sadr M, Abachizadeh H, Azizi M, Mesgari Abbasi M. Effect of Beta-Blockers on Number of Osteoblasts and Osteoclasts in Alveolar Socket Following Tooth Extraction in Wistar Rats. *J Dent (Shiraz, Iran).* 2017; 18(1): 37–42.
3. D'Souza D. Residual ridge resorption—revisited. In: Virdi M, editor. *Oral health care - prosthodontics, periodontology, biology, research and systemic conditions.* Shanghai: InTech; 2012. p. 15–24.
4. Gupta A, Tiwari B, Goel H, Shekhawat H. Residual ridge resorption: a review. *Indian J Dent Sci.* 2010; 2(2): 7–11.
5. Kunert-Keil C, Gredes T, Gedrange T. Biomaterials applicable for alveolar sockets preservation: in vivo and in vitro studies. In: Turkyilmaz I, editor. *Implant dentistry - The most promising discipline of dentistry.* Shanghai: InTech; 2011. p. 17–52.
6. Vieira AE, Repeke CE, Ferreira Junior S de B, Colavite PM, Bigueti CC, Oliveira RC, Assis GF, Taga R, Trombone APF, Garlet GP. Intramembranous bone healing process subsequent to tooth extraction in mice: micro-computed tomography, histomorphometric and molecular characterization. *PLoS One.* 2015; 10(5): 1–22.
7. Allegrini S, Koenig B, Allegrini MRF, Yoshimoto M, Gedrange T, Fanghaenel J, Lipski M. Alveolar ridge sockets preservation with bone grafting—review. *Ann Acad Med Stetin.* 2008; 54(1): 70–81.
8. Kubilius M, Kubilius R, Gleiznys A. The preservation of alveolar bone ridge during tooth extraction. *Stomatologija.* 2012; 14(1): 3–11.
9. Balgies, Dewi SU, Dahlan K. Sintesis Dan Karakterisasi Hidroksiapatit Menggunakan Analisis X - Ray Diffraction. In: *Prosiding Seminar Nasional Hamburan Neutron dan Sinar-X ke 8.* Tangerang: BATAN; 2011. p. 10–3.
10. Kumar P, Vinitha B, Fathima G. Bone grafts in dentistry. *J Pharm Bioallied Sci.* 2013; 5(Suppl 1): S125–7.
11. Naini A, Ardhiyanto HB, Yustisia Y. Proses sintesis dan karakterisasi Hydroxyapatite menggunakan analisis XRD FTIR dari gypsum Puger Kabupaten Jember sebagai material augmentasi ridge alveolar. *Stomatognatic.* 2014; 11(2): 32–7.
12. Tanaka H, Mine T, Ogasa H, Taguchi T, Liang CT. Expression of RANKL/OPG during bone remodeling in vivo. *Biochem Biophys Res Commun.* 2011; 411(4): 690–4.
13. Pepla E, Besharat LK, Palaia G, Tenore G, Migliau G. Nano-hydroxyapatite and its applications in preventive, restorative and regenerative dentistry: a review of literature. *Ann Stomatol (Roma).* 2014; 5(3): 108–14.
14. Veni MAC, Rajathi P. Interaction between bone cells in bone remodelling. *J Acad Dent Educ.* 2017; 2: 1–6.
15. Sims NA, Martin TJ. Coupling signals between the osteoclast and osteoblast: how are messages transmitted between these temporary visitors to the bone surface? *Front Endocrinol (Lausanne).* 2015; 6: 1–5.
16. Tjoa STS, de Vries TJ, Schoenmaker T, Kelder A, Loos BG, Everts V. Formation of osteoclast-like cells from peripheral blood of periodontitis patients occurs without supplementation of macrophage colony-stimulating factor. *J Clin Periodontol.* 2008; 35(7): 568–75.
17. Feng X, McDonald JM. Disorders of Bone Remodeling. *Annu Rev Pathol Mech Dis.* 2011; 6: 121–45.
18. Nishida E, Miyaji H, Kato A, Takita H, Iwanaga T, Momose T, Ogawa K, Murakami S, Sugaya T, Kawanami M. Graphene oxide scaffold accelerates cellular proliferative response and alveolar bone healing of tooth extraction socket. *Int J Nanomedicine.* 2016; 11: 2265–77.
19. Lü L-X, Zhang X-F, Wang Y-Y, Ortiz L, Mao X, Jiang Z-L, Xiao Z-D, Huang N-P. Effects of hydroxyapatite-containing composite nanofibers on osteogenesis of mesenchymal stem cells in vitro and bone regeneration in vivo. *ACS Appl Mater Interfaces.* 2013; 5(2): 319–30.