

**The Effectiveness of Merremia mammosa (Lour.)
Extract Fractions as Diabetic Wound Healers on
Diabetic Rat Model**

**Hiroshima J. Med.
Sci. Vol. 67, Special
Issue, May, 2018**

Oleh:

**dr. Elly Nurus Sakinah, M.Si
NIP. 19840916 200801 2 003**



**KEMENTERIAN RISET, TEKNOLOGI,
DAN PENDIDIKAN TINGGI
FAKULTAS
KEDOKTERAN
UNIVERSITAS JEMBER**



Editorial Board

Editor **Norio Sakai**

Associate Editors

Hirohiko Aoyama

Tomoichiro Asano

Kazuo Awai

Akira Eboshida

Hideki Ohdan

Kaoru Kurisu

Taijiro Sueda

Yukio Takeshima

Shinji Tanaka

Noboru Hattori

Michihiro Hide

Hirofumi Maruyama



The Effectiveness of *Merremia mammosa* (Lour.) Extract Fractions as Diabetic Wound Healers on Diabetic Rat Model

Elly Nurus SAKINAH¹, Evi Umayah ULFA², Ancah Caesarina Novi MARCHIANTI^{3*}

¹Department of Pharmacology, Medical Faculty, University of Jember, Kalimantan street No. 37, Jember, Indonesia, 68121

²Department of Microbiology and Pharmaceutical Biotechnology, Pharmacy Faculty, University of Jember, Kalimantan street No. 37, Jember, Indonesia, 68121

³Department of Public Health, Medical Faculty, University of Jember, Kalimantan street No. 37, Jember, Indonesia, 68121

ABSTRACT

Introduction: Prevalence of diabetic ulcers in Indonesia ranges from 17.3 to 32.9% of hospitalized diabetes patients. Approximately 14-24% of them cannot be healed and require amputation. Treatment of diabetic ulcers is quite difficult, because of the failure of blood vessels and bacterial infection. *Merremia mammosa* (Mm) (Lour.) that contains flavonoids are thought to have potential antioxidant that helps the wound healing process. This study aimed to determine the effect of Mm (Lour.) extract fractions in wound healing process of diabetic rat model and searching the most potent fraction in 25 mg effective dose. The dose was proven effective in other plant fraction and smaller dose in our preliminary study was ineffective. **Method:** This experimental study used twenty-five male Wistar rats that were made diabetic by intraperitoneal injection of 40 mg/kg body weight streptozotocin. Rats divided into five groups, which consist of positive control (gentamicin 0.1%), negative control (aquadest) and Mm (Lour.) dose 25 mg each of n-hexane, ethyl acetate and water fraction. Wound was made by Morton method and treatment applied on the wound every other day for 10 days. Wound healing process were observed by calculating the percentage of reduction in wound size. Data were described and analyzed further using appropriate statistic tools. **Results :** The percentage of reduction in wound size comparison at day 11 of the excision showed n-hexane fraction group has 90,1% , ethyl acetate fraction group has 88,5% water fraction group has 93,4%, positive control group has 92,2% and negative control grup has 81,8%. It showed significant different in every fraction when compared with negative control and no significant different when compared with positive control. This study showed that among the three factions, water fraction showed the fastest healing rate (93.4 %). **Conclusion:** Mm (Lour.) extract fractions significantly accelerated the process of wound healing in diabetic rat model and the most effective fraction was water fraction. Therefore, it is potential to be developed further as a topical drug.

Keywords: *Merremia mammosa* (Lour.), wound healing, diabetic ulcers

Diabetic ulcer and gangrene diabetic is one of the diabetes mellitus complication. Prevalence of diabetic ulcers in Indonesia was 12 % of hospitalized diabetes patients and diabetes mellitus risk factors was 55.4%. Approximately 14-24% of them cannot be healed and require amputation. Treatment of diabetic ulcers is quite difficult, because of ineffectiveness inflammatory responses, endothel dysfunction, the failure of blood vessels and bacterial infection thus interfering wound healing process.^{14,17}

Treating diabetic wound need comprehensive management which are blood glucose control, reduce offloading, keep the wound moisture and treat infection and also debridement of the wound. Highly cost, amputation requirement and the difficulty of diabetic wound care encouraging us to seek alternative treatment.¹⁶ One of the Indonesian medicinal plants have potential use for diabetic wound is *Merremia mammosa* (Mm) (Lour).¹¹ Mm (Lour) has four chemicals component that needed in wound healing. There

*Corresponding author : Ancah Caesarina Novi Marchianti, Department of Public Health, Medical Faculty, University of Jember, Kalimantan street No. 37, Jember, Indonesia, 68121, E-mail: ancah@unej.ac.id

are four new resin-glycosides named merremosides A, B, H1 and H2 were isolated from the tuber of *Mm* (Convolvulaceae) has anti-inflammatory activity through COX1 and COX2 inhibitory.⁴ *Mm* (Lour.) has antidiabetic activity through dipeptidyl peptidase-IV (DPP-IV) inhibitory activity.¹¹ Recent study show that ethanol extract of *Mm* (Lour) can decreasing blood glucose and accelerate wound healing of hyperglycemic rats by increasing fibroblast.²

Ethanol extract of *Mm* (Lour) has some limitation because its contains all component of tuber bulb that gives wound healer effect or not. The amount of extract required is large (200mg) because the active ingredients are still mixed with other component that are not active. Fractionation or stratified purification of *Mm* (Lour) should be performed to increase the yield of the active ingredient and decrease side effect from the amount of non-active material. Fractionation can decrease the amount of non-active material contaminant in the extract to facilitate the formulation phase to improve the acceptability. The purpose of this study was determining the healing wound activity of fraction n hexane, ethyl acetate and water *Mm* (Lour) and standardize the most potent fraction of *Mm* (Lour) extract.

MATERIALS AND METHODS

Ethanolic Extraction method

The material used is the *Mm* (Lour) that has been identified in herbarium Jemberiense University of Jember. Two kg *Mm* (Lour) dried by airflow to get the simplicial, then mix and sieved to obtain simplicial powder. Simplicial powder extracted with ultrasonicator with 96% ethanol solvent for 1 hour. The extract produced was filtered with a Buchner funnel to obtain the filtrate and macerated three times. Filtrate concentrated with a rotary evaporator until a viscous extract is obtained.

Fractionation Method

Viscous extract is fractionated by partition using 3 different solvents of polarity i.e. n-hexane, ethyl acetate and water. 50 grams viscous extract added with 100 mL of water and stirred until homogeneous. This water fraction on the partition with n-hexane, ethyl acetate with comparison 2:3 three times. The partition evaporated with rotavapor to get n-hexane and ethyl acetate fraction. The water fraction concentrated with freeze dryer until viscous fraction is obtained.⁷

Diabetic rat model

This experimental study used twenty-five male Wistar rats aged 2 months. Rats were treated based on Helsinki convention. An ethical approval was obtained from the Ethical Committee of Faculty of Medicine University of Jember (No. 1.134/H25.1.11/KE/2017. After adapted in 7 days, rats were made diabetic by intraperitoneal injection of 40 mg/kg body weight streptozotocyn (STZ) dissolved in 0,05 mol/L buffer sitrat (pH 4,5) and given dextrose 10% in one night after injection of STZ to prevent hypoglycemic sudden death. Rat has positive diabetes if serum blood glucose were more than 200mg/dL on the fifth day after STZ injection. Blood glucose were measured once a week.⁹

Wound Excision

The diabetic wound was made by Morton modified method. Wound excision made on the day after diabetic condition confirmed. Rats anesthetized with a combination of ketamine HCl dose of 50 mg / kg body weight and Xylazine dose 10 mg / kg body weight intramuscular. After anesthetic condition, excision was made until subcutaneous with an area of 2,5x2,5cm.⁶ The rats with non-infected wounds treated after one day of wounding. If there is pus or infection animal will be excluded. Treatment applied on the wound every other day for 10 days. Rats divided into five groups, which consist of positive control (gentamicin 0.1%), negative control (aquadest) and *Mm* (Lour.) dose 25 mg each of n-hexane, ethyl acetate and water fraction. After the completion of 11 days of topical application, the animals were subjected to wound examination and the percentage of reduction in the size of the wound was calculated.⁵

Measurement of percent wound healing

Wound margin was traced after wound creation by using transparent paper and the area was measured by graph paper. Wound contraction was measured every two days interval throughout the experimental period. Data were described and analyzed further using independent t-test statistic tools. Percent wound healing were observed by calculating the percentage of reduction in wound size.

Percent wound healing =

$$\frac{(\text{initial wound size} - \text{specific day wound size})}{100\% \text{ Initial wound size}} \times 100$$

Fraction standardization

Preparation of *Mm* (Lour.) extract using ethanol 70% with ultrasonication technique then continued fractionation phase with three different types of solvents ie water, ethyl, and n-hexane.

Fraction standardization has several parameters i.e. organoleptic examination, drying shrinkage, chromatogram profile and total flavonoid content. An organoleptic examination needs to be done to provide the identity of the fraction. Changes to this identity can be used to determine whether or not physical changes are extracted during the storage process. The chromatogram profile of the water content of upara bidara was carried out by TLC using eluent butanol, ethyl acetate and water ratio (6: 4: 1). The chromatogram profile is made by making payments to the elemation TLC plate at wavelength 254 using the TLC Scanner tool.

RESULTS

Induction of diabetes

The mean of body weight and non-fasting blood glucose level before and after diabetes induction were shown in figure 1. Mean of blood glucose before induction were 82,4mg/dL (negative control), 119,2 mg/dL (positive control), 92,4 mg/dL (dose 25 mg of ethyl acetate), 77,4 mg/dL (dose 25 mg of n-hexana), and 82,4mg/dL (dose 25 mg of water fraction). This result indicates that the initial condition of rats was normal. After STZ induction, mean of blood glucose were 472mg/dL (negative control), 472,4 mg/dL (positive control), 447,6 mg/dL (dose 25 mg of ethyl acetate), 450,2 mg/dL (dose 25 mg of n-hexana), and 444,6 mg/dL (dose 25 mg of water fraction). These results indicate that there is an increase of blood glucose level after induction with streptozotocin and rat had diabetic condition. Blood glucose were measured once a week and this hyperglycemia condition is still appeared until two weeks. It means that the diabetic rat models still in diabetic condition until the end of experiment.

Wound healing process

The rate of wound healing size and percent wound healing of the positive control group (gentamicin 0.1%), negative control group

(aquadest) and Mm (Lour.) dose 25 mg each of n-hexane group, ethyl acetate group and water fraction group is shown in Table 1 and Figure 2. Water fraction group has 93,4% wound healing process when compared with negative control grup (81,8%) at day 11. Water fraction group has the smallest wound diameter (54 mm) when compared with control negative group (114 mm) and other fraction group at day 11.

Water Faction Standardization

Standardization parameters of the determined Mm (Lour) extract water fraction are organoleptic examination, drying shrinkage, chromatogram profile and total flavonoid content. The organoleptic parameters of water fraction examined the thick form, greenish brown, no odor and bitter taste. The loss on drying result showed 2.06% ± 0.13% w / w. The chromatogram profile of the Mm (Lour) water fraction was carried out by TLC using eluent butanol, ethyl acetate and water ratio 6: 4: 1. The chromatogram profile is made by scanning the TLC plate at wavelength of 254 using the TLC Scanner tool. Results of TLC prior to scan and after scan can be seen in Figure 1. Based on the image, the stain that appeared under the UV lamp were 5 stains with Rf respectively in sequence 0.706; 0.588; 0.459; 0.294 and 0.188. The scan results obtained 10 peaks with a larger area of 1000 AU (Figure 3).

Determination of chromatogram profile is used to provide an overview of the compounds contained in the water fraction. Analysis of the flavonoid and terpenoid compounds was also done by using TLC and the ammonia and anisaldehyde sulphate vapor smears. The results of the content analysis showed that the water fraction of Mm (Lour) extract contains no terpenoid but contains flavonoids. Figure TLC water fraction of Mm (Lour) extract after stained with ammonia vapor and anisaldehyd sulphate dye can be seen in Figure 3.

Table 1. Wound size and percent wound healing*

Days	C(-)		C(+)		FE		FN		FW	
	Wound size	Percent wound healing	Wound size	Percent wound healing	Wound size	Percent wound healing	Wound size	Percent wound healing	Wound size	Percent wound healing
1	452.4	27.6	434.8	30.4	493.3	21.1	411.5	34.2	434.0	30.6
3	347.4	44.4	309.6	50.4	326.6	47.7	318.8	48.9	353.5	43.0
5	208.5	66.6	208.0	66.7	293.5	53.0	244.3	60.9	195.4	68.1
7	197.8	68.3	121.6	80.5	173.8	72.2	135.4	78.3	116.8	81.0
9	164.0	73.6	92.4	85.2	110.6	82.3	109.0	82.3	62.0	90.0
11	114.0	81.8	49.2	92.2 ^b	71.8	88.5 ^a	61.6	90.1 ^a	54.0	93.0 ^b

*All data are expressed as mean in millimeter for wound size and mean in percent for percent wound healing. C(+): Gentamicin 0.1%, C(-): Aquadest, and FE, FN, FW are ethyl acetate, n-hexane, water fraction of *Merremia mammosa (Lour.)*. ^ap<0.05 or ^bp<0.001 v.s. negative control (aquadest) at day 11 using unpaired Student T test.

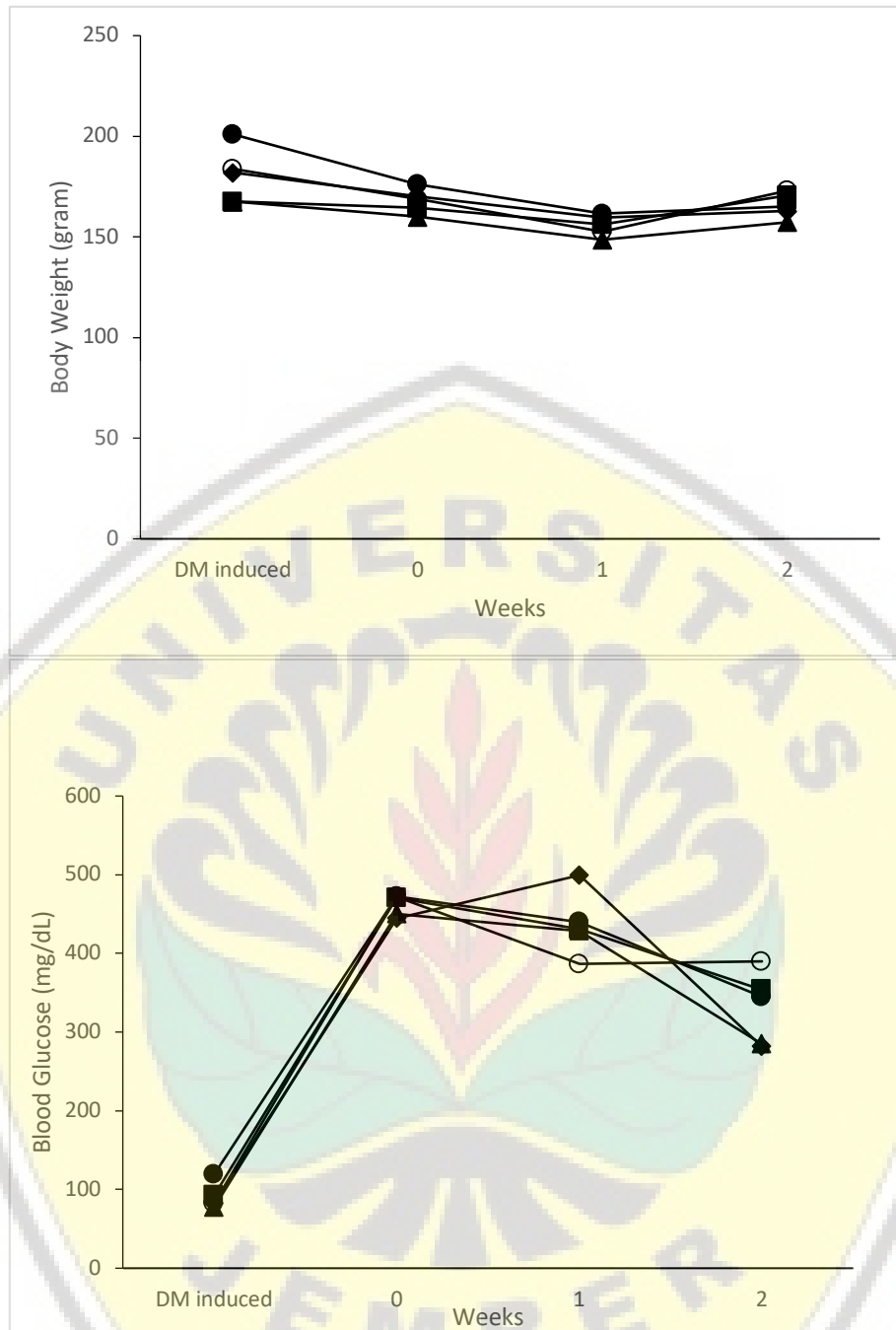


Figure 1. Body weight and non-fasting blood glucose level during the experimental period.

Mean values of body weight (A), non-fasting blood glucose (B) and percent wound healing (C) are shown. Opened and closed circles represent negative and positive control. Closed square, triangle and diamond represent groups of *Merremia mamossa* (Lour) extract fraction dose 25 mg of ethyl acetate, n-hexane and water fraction in a sequent.

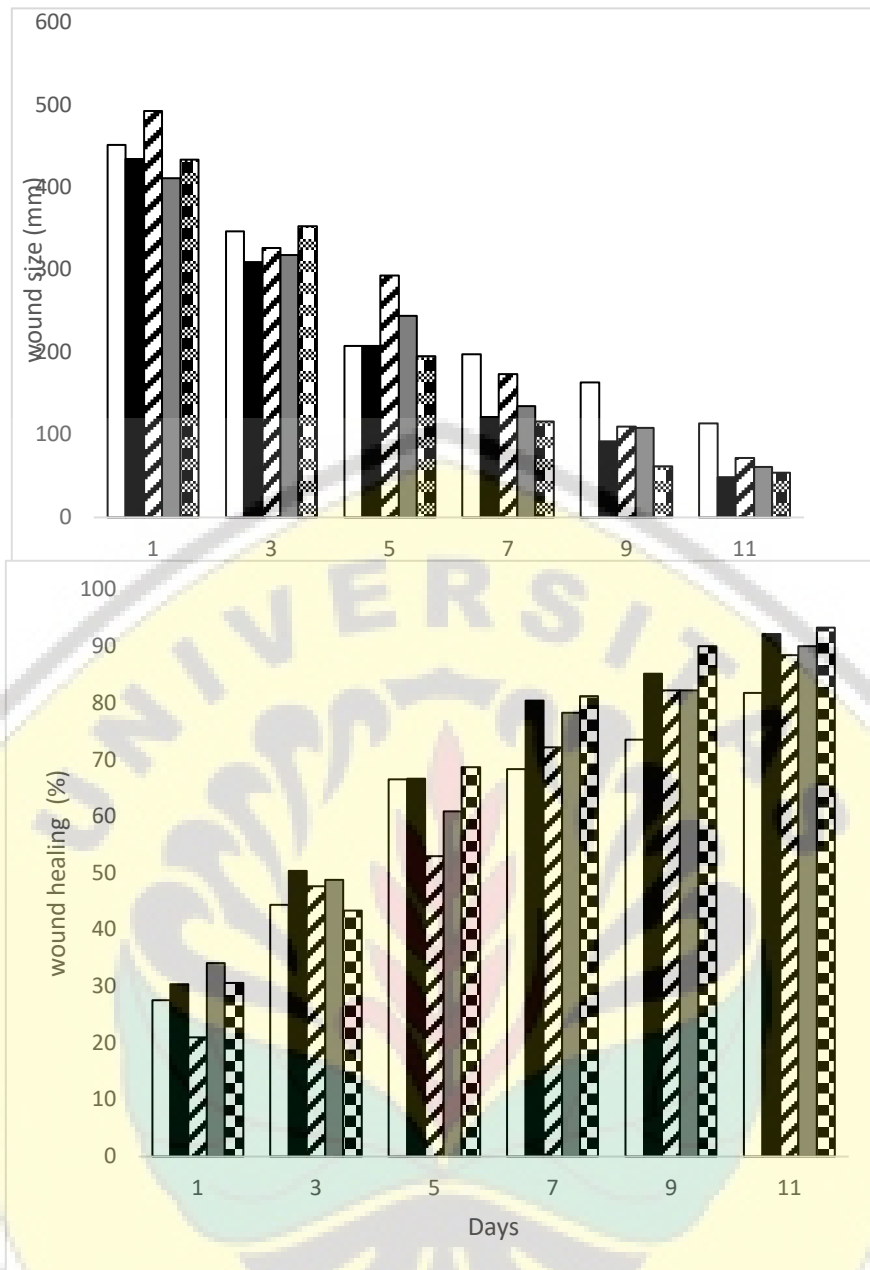


Figure 2. Wound size and percent wound healing during the experimental period. All data are expressed as mean in millimeter for wound size and mean in percent for percent wound healing. *Opened column*, negative control; *closed column*, positive control; *hatched*, gray and *cubed column* are ethyl acetate, n-hexane and water fraction of *Merremia mammosa (Lour.)*.

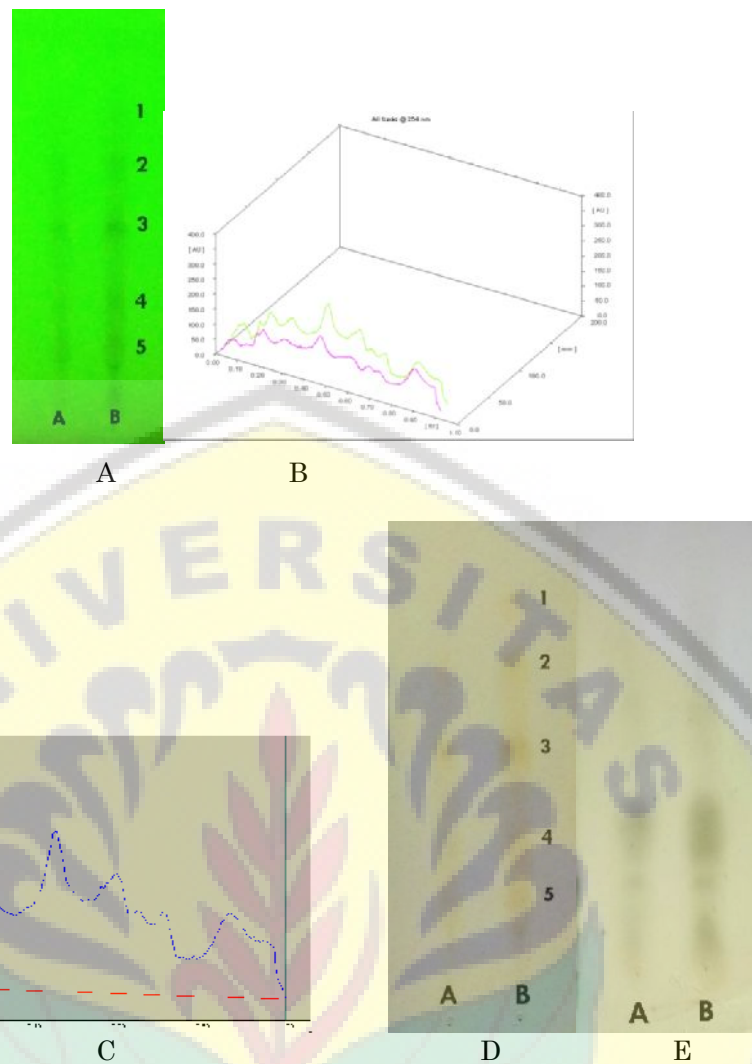


Figure 3. TLC chromatogram profile of Mm (Lour) water fraction using silica gel stationary phase, butanol mobile phase: acetic acid: water (6: 4: 1). (A,B,C); TLC results of water fraction of Mm (Lour) extract with butanol mobile phase: acetic acid: water (6: 4: 1), A. 2 uL Band; B. 4 uL Band. Ammonia vapor (1) and anisaldehyde sulfate (2) smear.

DISCUSSIONS

Diabetic ulcer is one of diabetes complication. In this study, we use 40 mg / kg body weight STZ to make a diabetic rat model. This dose has been successful in making the animal experience hyperglycemia and persisted until the end of this experiment in the second week. After STZ injection, body weight showed a slightly decreased in all group and then increased gradually, this is relevant with DM pathogenesis.^{6,9} STZ are diabetogenic agent that selectively beta cell pancreas toxicity. STZ will be uptakes the langerhans beta cell pancreas by GLUT2 and make beta cell pancreas damage so its failed to produce insulin resulting in increased blood glucose levels.¹ Excisional wound is most suitable method in wound research due to the broader morphological changes during healing process.

Wound size is an essential parameter to assess wound closure. Wound closure shows better re-epithelialization process during healing process.

The ethanol extract Mm (Lour) was partitioned using two solvents having different polarity levels i.e. n-hexane, ethyl acetate and water. It is aimed to separating the group of low-polymer compounds into n-hexane solvents, the group of compounds whose polymer is solvent of ethyl acetate and the high polarity to water. In this present study, treatment with water fraction resulted in faster wound healing process and smallest wound diameter compare to negative control and other fractions at day 11. This study showed that among the three factions, water fraction showed the most effective fraction for diabetic wound healing process. This is suggest that healing process occurs to be due to presence of glycoside flavonoid that have anti-

inflammatory effect more dissolved in the water fraction than with other fraction. It is because the flavonoid is a polar compound so it more easily soluble in the polar solvent fraction of water. This means that the solubility of an active material depends on polarity of solution, the active material of this compound dilutes mostly in water fraction..^{10,13} Because of water fraction is most effective, to prove the existence of flavonoid compound in water fraction, standardization of water fraction of Mm (Lour) was done.

An organoleptic examination needs to be done to provide the identity of the fraction. Changes to this identity can be used to determine whether there were extract fraction physical changes or not during the storage process. Physical changes are generally followed by chemical changes that may affect the efficacy of the extract.¹³ Examination of loss on drying aims to determine the amounts of volatile compounds in the fraction. The loss on drying rate is determined using gravimetry. The loss on drying result showed $2.06\% \pm 0.13\% \text{ w / w}$. This shows that from 100 grams of extract there are 2.06 grams of compounds lost during the heating process. The compound lost in the water fraction of this Mm (Lour) extract is probably water. Low water levels will prevent the growth of microorganisms and molds. Water content that exceeds 10% can cause the extract will easily overgrown with fungi.³

Determination of total flavonoid content of Mm (Lour) water fraction using colorimetric method of aluminum chloride with quercetin as comparison. Quercetin is a flavonoid of a flavonol group that has a keto group on C-4 and a hydroxy group on C-3 or C-5 atoms. The maximum wavelength resulting from the measurement of quercetin is 438 nm. The quercetin regression line for this study was $y = 0.0121x - 0.0934$ with $r = 0.948$. Flavonoid levels with AlCl_3 method were $0.17 \pm 0.009\% \text{ w/w}$. Flavonoids are polyphenol compounds found in plants. Flavonoids have various activities including antioxidants and anti-inflammatory. Based on this result, it is indicated that the water fraction of Mm (Lour) contain flavonoids

ACKNOWLEDGMENT

The authors are grateful to the Ministry of Research, Technology and Higher Education for financial supporting this research.

REFERENCES

1. Eleazu, C. O., Eleazu, K. C., Chukwuma, S. and Essien, U. N. 2013. Review of the

mechanism of cell death resulting from streptozotocin challenge in experimental animals, its practical use and potential risk to human. *Journal of diabetes and metabolic disorders*. BioMed Central, 12(1):60. doi: 10.1186/2251-6581-12-60.

2. Hidayat, F. K., Elfiah, U. and Sofiana, K. D. 2015. Comparison of the number of macrophage in full thickness wound incision between merremia mammosa extract treatment and nacl in male wistar rats. *Journal of Agromedicine and Medical Sciences*. 1(1):9–13. Available at: <https://jurnal.unej.ac.id/index.php/JAMS/article/view/1697> (Accessed: 31 August 2017).
3. Isnawati, A., Arifin, K.M. 2006. KARAKTERISASI DAUN KEMBANG SUNGSANG (*Gloria superba* (L)) DARI ASPEK FISIKO KIMIA. *Media of Health Research & Development*. 16(4): 8-14.
4. Kitagawa, I., Ohashi, K., Baek, N. I., Sakagami, M., Yoshikawa, M. and Shibuya, H. 1997. Indonesian medicinal plants. XIX. 1) Chemical structures of four additional resin-glycosides, mammosides A, B, H1, and H2, from the tuber of *Merremia mammosa* (Convolvulaceae).', *Chemical & pharmaceutical bulletin*, 45(5):786–94. Available at: <http://www.ncbi.nlm.nih.gov/pubmed/9178519> (Accessed: 31 August 2017).
5. Mahmood, A. Tiwari, A.K. Sahin, K. KÜÇÜK, Ö, Ali, S. 2016. Triterpenoid saponin-rich fraction of *Centella asiatica* decreases IL-1 β and NF- κ B, and augments tissue regeneration and excision wound repair. *Turk J Biol* (2016) 40: 399-409
6. Marchianti, A.C.N., Arimura, E., Ushikai, M, Horiuchi, M. 2014. Voluntary exercise under a food restriction condition decreases blood branched-chain amino acid levels, in addition to improvement of glucose and lipid metabolism, in db mice, animal model of type 2 diabetes. *Environmental Health and Preventive Medicine*. 19(5): 339–347.
7. Morton, J. J. and Malone, M.H. 1972. Evaluation of vulnerary activity by an open wound procedure in rats. *Arch. Int. Pharmacodyn. Ther.*, 196 (1) 117-126.
8. Mukhriani. 2014. Ekstraksi, Pemisahan

- Senyama, dan Identifikasi Senyawa Aktif. *Jurnal Kesehatan* 7(2):361-367
9. **Mustaghfiroh, I. T. and Probosari, E.** 2014. Pengaruh pemberian tepung tempe dan pati garut (*marantha arundinacea*) termodifikasi terhadap kadar glukosa darah tikus hiperglikemi. *Journal of Nutrition College*, 3(1). Available at: <http://download.portalgaruda.org/article.php?article=142586&val=4711> (Accessed: 31 August 2017).
10. **Ramadhani,N., Sumini, S.A.** 2017. Aktivitas Antiinflamasi Berbagai Tanaman Diduga Berasal Dari Flavonoid. *Farmaka*. Volume 4 Nomer 4 Suplemen 1.
11. **Redaksi Agromedia,** 2008, Buku Pintar Tanaman Obat : 431 jenis tanaman penggempur penyakit, Penyunting Damayanti, Agromedia Pustaka.
12. **Riyanti, S., Suganda, A. G. and Sukandar, E. Y.** 2016. Dipeptidyl peptidase-iv inhibitory activity of some indonesian medicinal plants. 9(2). Available at: <https://innovareacademics.in/journals/index.php/ajpcr/article/viewFile/11019/4089> (Accessed: 31 August 2017).
13. **Sapri., S, Eka Siswanto., Yulianti, A.** 2017. Uji aktivitas Antiinflamasi Fraksi Air ekstrak daun Seledri pasa Mencit Jantan. *Jurnal Ilmu Ibnu Sina*, 2(1). 6-67
14. **Tellechea, A., Leal, E., Veves, A. and Carvalho, E.** 2010. Inflammatory and angiogenic abnormalities in diabetic wound healing: role of neuropeptides and therapeutic perspectives. *The Open Circulation and Vascular Journal*, 3:43–55. doi: 10.2174/1877382601003020043.
15. **Ulfa, E.U., Rachmawati, E.** 2015. Standarisasi Ekstrak Batang Kayu Kuning (*Arcangelisia flava* (L.) Merr). In *Current Challenges in Drug Use and Development Seminar*. 20-25. Jember: UNEJ Press.
16. **Yazdanpanah, L., Nasiri, M. and Adarvishi, S.** 2015. Literature review on the management of diabetic foot ulcer. *World journal of diabetes*. Baishideng Publishing Group Inc, 6(1):37–53. doi: 10.4239/wjd.v6.i1.37.
17. **Yusuf, S., Okuwa, M., Irwan, M., Rassa, S., Laitung, B., Thalib, A., Kasim, S., Sanada, H., Nakatani, T. and Sugama, J.** 2016. Prevalence and risk factor of diabetic foot ulcers in a regional hospital, eastern indonesia. *Open Journal of Nursing*. 6(6):1–10. doi: 10.4236/ojn.2016.61001.