



## Case report

## Total recovery spinal cord injury in cervical 5–6 dislocation: Case reports

I Nyoman Semita<sup>a,\*</sup>, Ni Njoman Juliasih<sup>b</sup>, Parama Gandi<sup>c</sup>, Heni Fatmawati<sup>d</sup><sup>a</sup> Departement of Orthopedic and Traumatology, Dr. Soebandi General Hospital, Faculty of Medicine, University of Jember, Indonesia<sup>b</sup> Department of Public Health, School of Medicine, Universitas Ciputra, Surabaya, Indonesia<sup>c</sup> Department of Cardiology and Vascular Medicine, Faculty of Medicine, Soetomo General Hospital, Universitas Airlangga, Surabaya, Indonesia<sup>d</sup> Departement of Radiology, Dr. Soebandi General Hospital, Faculty of Medicine, University of Jember, Indonesia

## ARTICLE INFO

## Keywords:

Cervical spine dislocation  
Spinal cord injury  
Posterior approach  
Open reduction  
Mechanical ventilation

## ABSTRACT

**Introduction and importance:** The challenges in spinal cord injury (SCI) cases are the regeneration mechanism, low recovery rate, and absence of neuroprotective agent. The recovery rate for SCI in cervical spine dislocation is still around 1 %.

**Case presentation:** The patient is a 59-year-old woman, suffer from SCI in cervical dislocation C4-C5. The initial assessment was cervical trauma with airway, breathing, circulation, and disability problems. The cervical spine was controlled with a collar brace. ASIA impairment scale was grade A. Posterior approach surgery was performed, including open reduction, laminectomy, stabilization, and fusion. It was continued with mechanical ventilation and rehabilitation. Monitoring and follow up was done for three months of surgery.

**Clinical discussion:** Early diagnosis, prompt treatment of an interprofessional team, early surgery, mechanical ventilation, steroid administration, and rehabilitation will provide better results. The activity daily living (ADL) assessment was normal, either function of JOA score or disability of ODI score.

**Conclusions:** The patient has normal neurologic function, including motoric, sensory, urination, and defecation. There is still hope SCI recovery in cervical spine dislocation after early and multidisciplinary treatment.

## 1. Introduction

Sub axial C3-C7 cervical spine facet dislocations constitute approximately 10 % of all sub axial cervical spine injuries, 40 % of which is associated with neurological insult [1]. Total recovery spinal cord injury (SCI) in cervical dislocation is very rare because the level of damage is significant and the process of recovery of sensory and motor functions is hampered [2]. Cervical dislocation often associate with 1.3 % SCI [3]. Zheng et al. stated that disability was 98 %, death was 10–20 %, and load economy 40 M for tetraplegia [4]. Length of stay in the intensive care unit (ICU) room was 11 days with 31 days of rehabilitation [5]. SCI change neurological skills as well as influences the physical, psychological, social, and financial well-being of patients [6]. Our case reports SCI in cervical dislocation of C4-C5 with significance neurological improvement. The case report has been reported in line with the SCARE criteria [7].

## 2. Case presentation

A 59-year-old woman, SCI in cervical dislocation of C5-C6 caused by fell from second floor at 4.30 a.m. The patient said that the moment, his head hit the wall behind him and lost consciousness. After waking up, the patient complained of difficulty in moving his neck and weakness of all extremities. The patient came by ambulance to the emergency room at 3 p.m. Primary survey had been done at referring hospital started at 8 a.m., the patient was immobilized using a neck collar, got an injection of methylprednisolone (5 mg/kgBW), methyl cobalt (500 µg × 3), and pantoprazole (40 mg/day).

Primary survey and initial management were done in the emergency room of our hospital. A secondary survey is carried out after the patient is stable with inspection from head to toe. The right/left hand and leg motor strength of 1 and 0. The pathological reflex showed Hoffman +/+, Tromner +/+, Babinski +/+. On sensory inspection, it was shown that there was hypoesthesia below C6. The breathing was dominated abdominally; anal sphincter tone was negative. The patient was unable to urinate and defecate spontaneously. Supporting examinations were

\* Corresponding author at: Jl. Nusantara 2 No A5 Gor Kaliwates, Jember, Surabaya, East Java, Indonesia.

E-mail addresses: [761017007@mail.unej.ac.id](mailto:761017007@mail.unej.ac.id) (I.N. Semita), [njoman.juliasih@ciputra.ac.id](mailto:njoman.juliasih@ciputra.ac.id) (N.N. Juliasih), [paramagandi-2018@fk.unair.ac.id](mailto:paramagandi-2018@fk.unair.ac.id) (P. Gandi), [fatmawatiheni@unej.ac.id](mailto:fatmawatiheni@unej.ac.id) (H. Fatmawati).

<https://doi.org/10.1016/j.ijscr.2025.111432>

Received 17 February 2025; Received in revised form 2 May 2025; Accepted 10 May 2025

Available online 13 May 2025

2210-2612/© 2025 Published by Elsevier Ltd on behalf of IJS Publishing Group Limited. This is an open access article under the CC BY-NC-ND license (<http://creativecommons.org/licenses/by-nc-nd/4.0/>).

including CT scans and plain x-ray of the cervical spine; and laboratory complete blood count, kidney function, blood gas analyses (BGA) were normal (Fig. 1, Table 1).

The operation was done 20 h after injuries. The patient has an American Society of Anesthesiologists (ASA) score of 2, vital signs were normal, and blood loss of as much as 200 cc. Preparations of surgery were made by receiving physiologic saline (0.9%NaCl solution), methylprednisolone (5 mg/kgBW), methyl cobalt (500  $\mu\text{g} \times 3$ ), and ranitidine (3 g/day). The patient underwent surgery, posterior approach, open reduction, laminectomy, stabilization, and fusion (Fig. 2 A, B). Post operative care was in the ICU for four days (Fig. 3), the patient could breathe with ventilator assistance in VC-SIMV mode with  $\text{FiO}_2$  40 %, PEEP 5 and got infusion with Tutosol 1000 cc/24 h, injection of methylprednisolone (5 mg/kgBW), methyl cobalt (500  $\mu\text{g} \times 3$ ), ceftriaxone (2 g/day), and tramadol (1 g/6 h). On the seventh day, patient could breathe with thoracic breathing, ventilator was extubated, and the patient could spontaneously breathe. The right- and left-hand motor strengths of the patient were 3 and 2, while right and left leg motor skills of the patient were 4 and 3. The patient underwent rehabilitation for ten days before sent home. The muscle tone decreased in the extremities on left was score 2. The physiological reflex showed BPR +2/+3, TPR +2/+3, KPR +2/+2, APR +2/+2. The pathological reflex showed Hoffman +/+, Tromner +/+, Babinski +/+. The sensory was shown within normal limits. The patient could already defecate and urinate.

Three months after surgery, the right- and left-hand motor strengths of the patient were 5 and 5; while right- left leg motor skills of the patient were 5 and 5; normal function of bowel and bladder. Activity daily living (ADL) was evaluated using the Japanese Orthopedic Association (JOA) and Oswestry Disability Index (ODI) score are 16/17 (normal

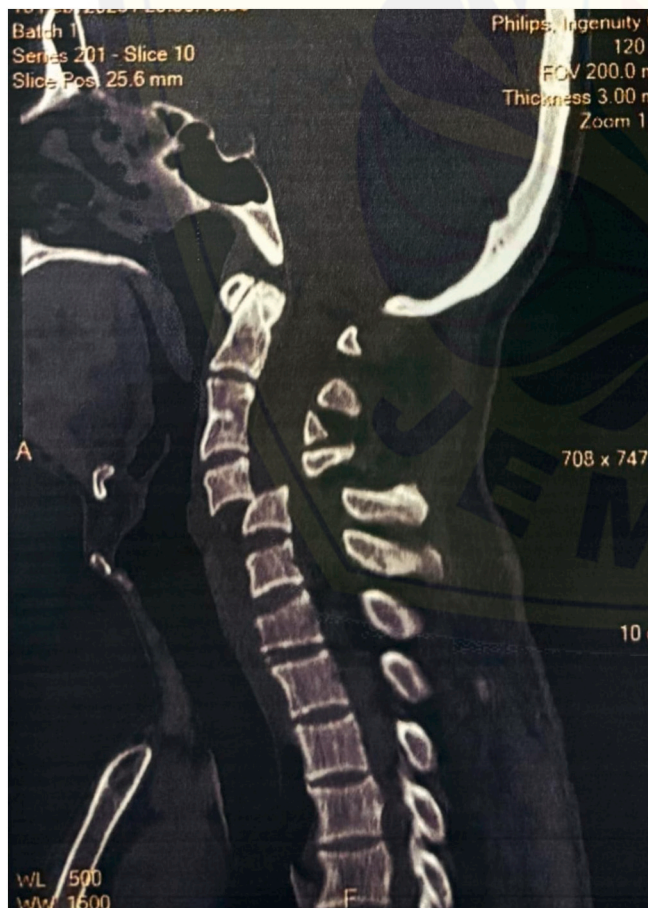

Fig. 1. Lateral plain x-ray of the cervical before surgery, shows dislocation of 5–6 cervical vertebrae.

Table 1

Examination laboratory results.

Hematology Complete	Check-up result	Normal Value
Hemoglobin	11.2	12–16 g/dL
Leukocytes	13.5	4.5–11.0 $\times 10^3$ / uL
Hematocrit	31.6	36–46 %
Platelets	240	150–450 $\times 10^3$ / uL
PPT	10.3	10.2
APTT	20.4	28.7
Heart Physiology		
SGOT	24	10–31 U/L
SGPT	15	9–36 U/L
Albumin	3.9	3.4–4.8 g/dL
Electrolyte Serum		
Sodium	138.9	135–155 mmol/L
Potassium	4.27	3.5–5.0 mmol/L
Chloride	108.7	90–110 mmol/L
Kidney Physiology		
Serum Creatinine	1.0	0.5–1.1 mg/dL
BUN	17	6–20 mg/dL
Blood Gas Analysis	Check-up result	Normal Value
pH	7.58	7.35–7.45
PCO <sub>2</sub>	31.4	35–45 mmHg
pO <sub>2</sub>	65	83–108 mmHg
BE	8.5	(–2) – (+2)
HCO <sub>3</sub>	30	22–26 mmol/L
SO <sub>2</sub>	94	95–98 %
AaDO <sub>2</sub>	44	mmHg
Lactic Acid	1,2	0.9–1.7 mmol/L

function) and 10/60 (minimal disability) successively (Fig. 4 A, B).

### 3. Discussion

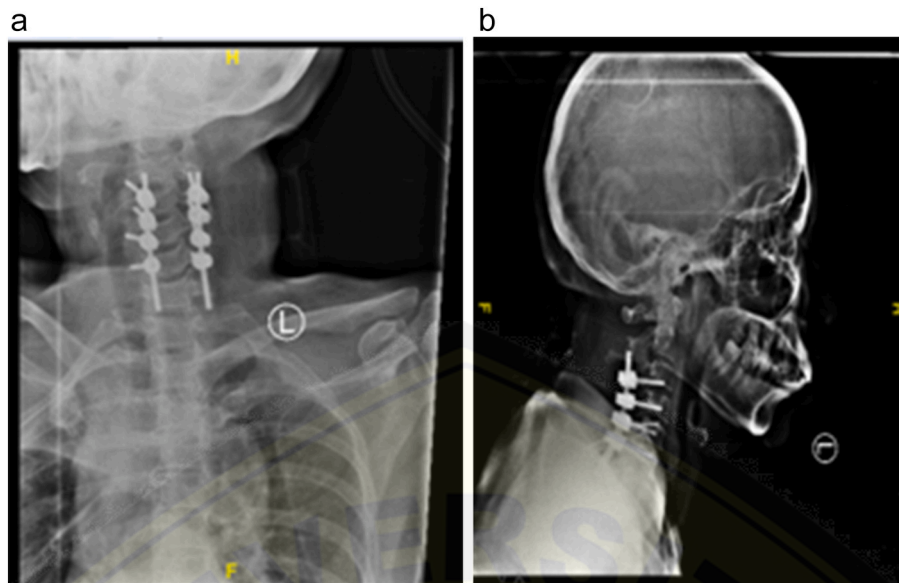
In this case report, the outcome of SCI treatment in cervical dislocation was better than previously prediction in our hospital. The treatment of lower cervical facet dislocation is generally recognized as reduction, decompression, fixation, and fusion [8]. Although there were many treatment strategies and algorithms in the past, the optimum treatment strategy and algorithm of cervical facet dislocation is still a matter of debate. Despite agreement in the literature over the role of closed reduction and surgical treatment of these injuries, there are still areas of debate including indications for MRI and MRI timing [8]. The selection of surgical approach depends on a combination of factors, including surgeon preference, patient factors, injury morphology, and inherent advantages and disadvantages of any given approach [8].

The patient had been wearing a collar brace from the start, referred immediately, early diagnosis, and prompt treatment. Using a collar brace is very useful in preventing secondary damage SCI [9]. Liu and Zhang (2023) state that the reduction techniques are categorized into 4 main types: closed reduction, anterior alone, posterior alone, and combined approach techniques [8]. Early open reduction, laminectomy, and fusion are useful in preventing secondary damage SCI; improve perfusion; and minimize ischemia, inflammation, and apoptosis process [8]. In this case, posterior stabilization is preferred because the pathologic lesion is in the posterior part and reduce the tension of posterior ligaments and muscles.

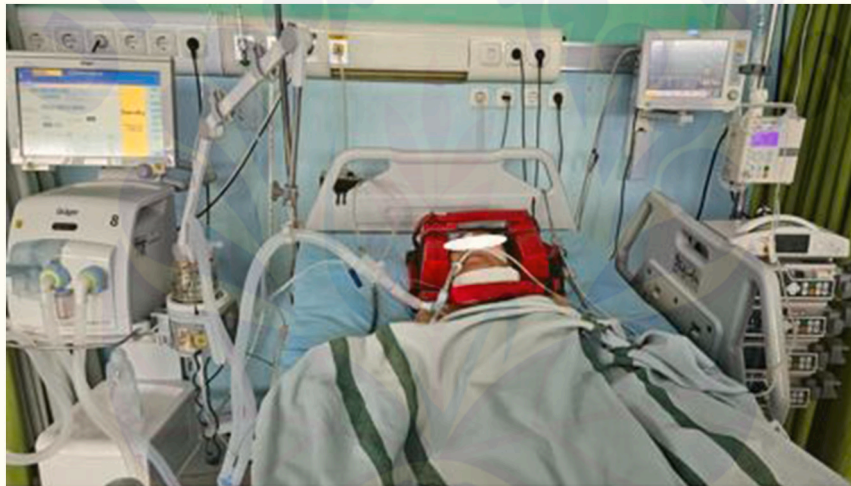Methylprednisolone reduce inflammation and increase blood flow in the spinal cord [10]. Mechanical ventilation useful in prevention of respiratory distress [11]. Rehabilitation is meaning full in early ambulation, for training of muscle strength, gait, and activities of daily living [12].

The pathophysiology of SCI in cervical spine dislocation is vascular





**Fig. 2.** Plain x-ray of the cervical after operation: A. anterior-posterior cervical photo, B. Lateral cervical photo.



**Fig. 3.** Post-operative care in the ICU.

problem, result in ischemia, inflammation, apoptosis, and degeneration in formation of glial scar [13]. Excessive inflammatory response causes cytokine and chemokine release, lipid peroxidation, apoptosis, and destroy the normal tissue in spinal cord [14]. The acute phase, which includes damage to blood vessels, electrolytes imbalance, accumulation of neurotransmitters, formation of free radicals, calcium deficiency, lipid peroxidation, inflammation, oedema, and necrotic cell death, starts immediately after SCI [15].

Macrophages collaborate with endogenous neural stem cells originating from ependymal cells in the central canal of the spinal cord and periventricular [14,16]. The balance between the proinflammatory M1 phenotype macrophage/microglia responses and pro-regenerative M2 phenotype responses is beneficial for SCI repair [16].

Early onsite good management, early referral, prompt treatment within 24 h of injuries, interprofessional team, early surgery, adapted postoperative care with mechanical ventilation, steroid administration, and rehabilitation will provide better results, although there is still debatable, considering the complexity of the pathophysiology and regeneration of the spinal cord. In this case report, there is still hope total recovery of SCI associated with cervical dislocation. The limitation of this case report is only focuses on one case, making it difficult to

conclude that the findings apply to a wider population and the treatment algorithm cannot be used as a standard or guideline for treatment cervical spine dislocation.

#### 4. Conclusions

There is still hope SCI recovery in cervical spine dislocation with proper primary management and early referral as elements essential to good results.

#### Ethical approval

This study was approved by the research ethics committee (No. 420/2099/610/2024).

#### Guarantor

I Nyoman Semita

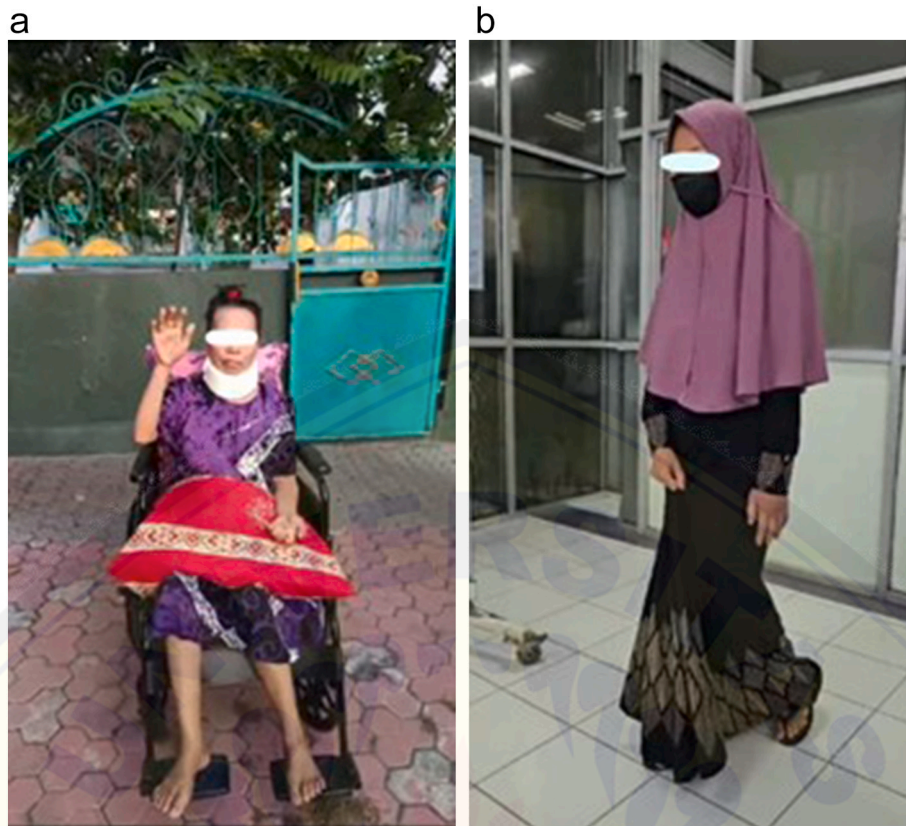

Fig. 4. Post-operative patient development process: A. Seven days after leaving the hospital, B. Three months after leaving the hospital.

## Funding

Not applicable.

## Author contribution

I Nyoman Semita: Conceptualization or design, Visualization, Writing-original draft, Writing-review & editing  
 Ni Njoman Juliasih: Writing-original draft, Writing-review & editing  
 Parama Gandhi: Conceptualization or design, Visualization  
 Heni Fatmawati: Visualization and Writing-original draft

## Declaration of competing interest

The authors declare no conflict of interest.

## Acknowledgement

Not applicable.

## References

- [1] W. Lee, C.C. Wong, Anterior-alone surgical treatment for subaxial cervical spine facet dislocation: a systematic review, *Glob. Spine J.* 11 (2) (2021) 256–265.
- [2] F.C. Tamburrelli, M.C. Meluzio, A. Perna, M.I. Borruto, M. Genitempo, L. Proietti, Cervical Spine Fractures and Dislocations, Classification and Treatment, in: *Cervical Spine: Minimally Invasive and Open Surgery: Second Edition*, 2022, pp. 211–229.
- [3] P. Foroutan, R.D. Quarrington, C.F. Jones, Mechanisms and risk factors associated with spinal cord injury, facet fracture, and level of dislocation, in occupants with cervical spine dislocations sustained in motor vehicle crashes, *Traffic Inj. Prev.* 0 (0) (2024) 1–8, <https://doi.org/10.1080/15389588.2024.2378133>.
- [4] R. Zheng, B. Guan, Y. Fan, R. Fu, L. Yao, W. Wang, Guoyu Li, Lingxiao Chen, Hengxing Zhou, Shiqing Feng, A critical appraisal of clinical practice guidelines for management of four common complications after spinal cord injury, *Spine J.* 23 (6) (2023) 888–899, <https://doi.org/10.1016/j.spinee.2022.12.001>.
- [5] National Spinal Cord Injury Statistical Center, *Spinal Cord Injury Facts and Figures at a Glance* 36 (1) (2021) 1–2.
- [6] B. Fiani, M.A. Arshad, E.S. Shaikh, A. Baig, M. Farooqui, M.A. Ayub, et al., Current updates on various treatment approaches in the early management of acute spinal cord injury, *Rev. Neurosci.* 32 (5) (2021) 513–530.
- [7] C. Sohrabi, G. Mathew, N. Maria, A. Kerwan, T. Franchi, R.A. Agha, The SCARE 2023 guideline: updating consensus surgical Case Report (SCARE) guidelines, *Int. J. Surg.* 109 (5) (2023) 1136–1140.
- [8] K. Liu, Z. Zhang, Reduction of lower cervical facet dislocation: a review of all techniques, *Neurospine* 20 (1) (2023) 181–204.
- [9] S. Kolli, R. Medina, C. DeYoung, B. Lucke-Wold, Cervical collar use in spinal cord injury management, *Clin. Transl. Discov.* 4 (3) (2024) 1–9.
- [10] S. Zagorac, Methylprednisolone therapy in acute spinal cord injuries, *Serbian J. Med. Chamb.* 2 (4) (2021) 409–415.
- [11] A. Roquilly, B. Vigué, M. Boutonnet, P. Bouzat, K. Buffenoir, E. Cesario, et al., French recommendations for the management of patients with spinal cord injury or at risk of spinal cord injury, *Anaesth. Crit. Care Pain Med.* 39 (2) (2020) 279–289.
- [12] I. Okereke, K. Mimerem, D. Balasubramanian, The management of cervical spine injuries – a literature review, *Orthop. Res. Rev.* 13 (2021) 151–162.
- [13] A. Anjum, M.D. Yazid, M.F. Daud, J. Idris, A.M. Hwei Ng, A.S. Naicker, et al., Spinal cord injury: pathophysiology, multimolecular interactions, and underlying recovery mechanisms, *Int. J. Mol. Sci.* 21 (20) (2020) 1–35.
- [14] D.J. Hellenbrand, C.M. Quinn, Z.J. Piper, C.N. Morehouse, J.A. Fixel, A.S. Hanna, Inflammation after spinal cord injury: a review of the critical timeline of signaling cues and cellular infiltration, *J. Neuroinflammation* 18 (1) (2021) 1–16, <https://doi.org/10.1186/s12974-021-02337-2>.
- [15] Y. Zhang, A. Al Mamun, Y. Yuan, Q. Lu, J. Xiong, S. Yang, et al., Acute spinal cord injury: pathophysiology and pharmacological intervention (Review), *Mol. Med. Rep.* 23 (6) (2021) 1–18.
- [16] O. Honmou, T. Yamashita, T. Morita, T. Oshigiri, R. Hirota, S. Iyama, J. Kato, Y. Sasaki, S. Ishiai, Y.M. Ito, A. Namioka, T. Namioka, M. Nakazaki, Y. Kataoka-Sasaki, R. Onodera, S. Oka, M. Sasaki, S.G. Waxman, J.D. Kocsis, Intravenous infusion of auto serum-expanded autologous mesenchymal stem cells in spinal cord injury patients: 13 case series, *Clin. Neurol. Neurosurg.* 203 (November 2020) (2021) 106565, <https://doi.org/10.1016/j.clineuro.2021.106565>.