

Publikasi Jurnal

A Combination of Cheek Flap, Cartilage Insertion, and Fat Transfer on Post-Trauma Lower Eyelid Ectropion Reconstruction

Dr. dr. Ulfa Elfiah, M.Kes., Sp.BP-RE., Subsp.L.B.L.(K)
NIP.197607192001122001

- Tenaga Pengajar
Fakultas Kedokteran Universitas Jember

KEMENTERIAN PENDIDIKAN, KEBUDAYAAN, RISET DAN
TEKNOLOGI UNIVERSITAS JEMBER

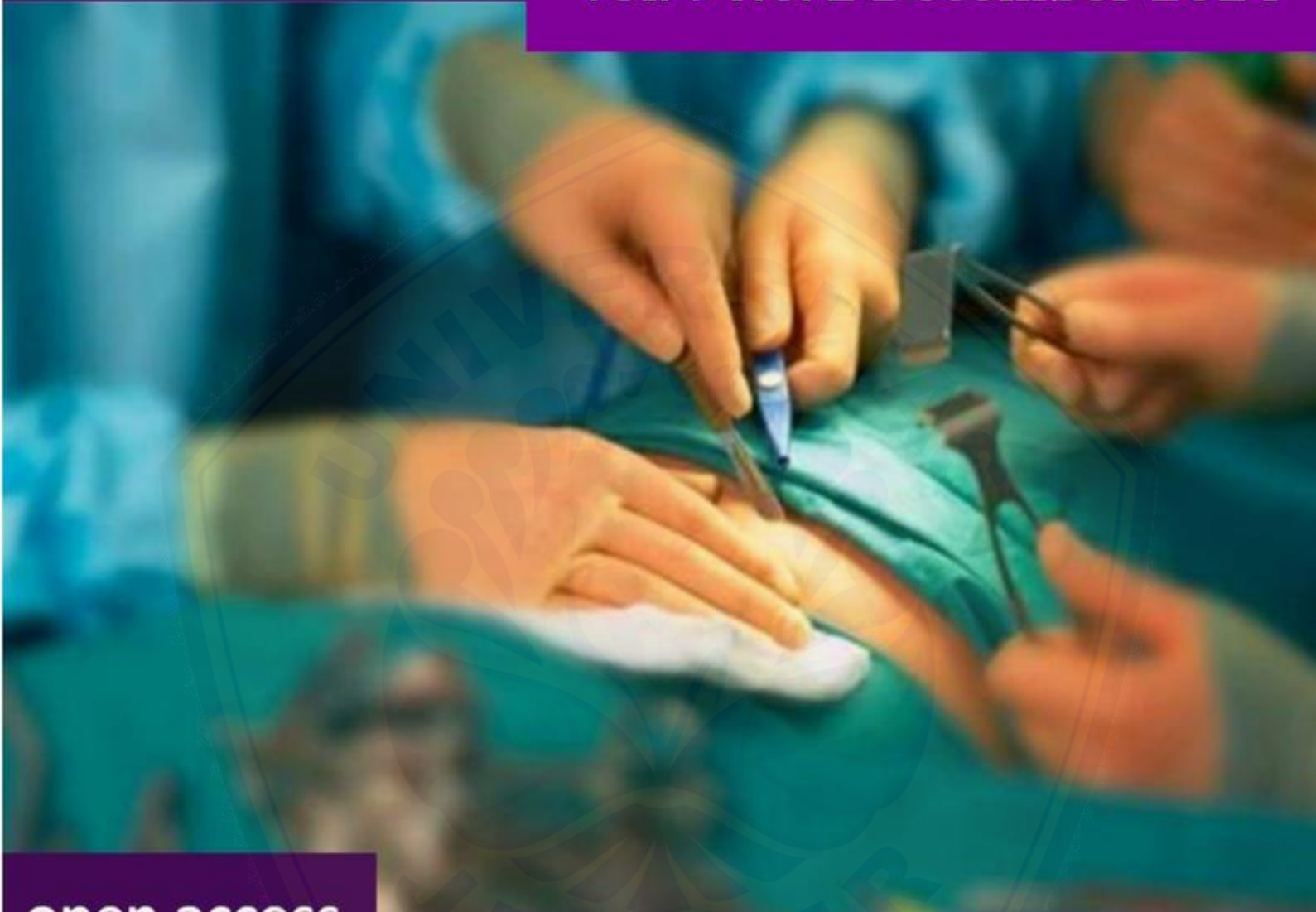

Karya Ilmiah dipublikasikan pada:

Jurnal Rekonstruksi dan Estetik
Vol. 9, No.2, Desember 2024
eISSN: 2774-6062



Vol. 9 No. 2 December 2024



open access

Jurnal Rekonstruksi dan Estetik

<http://e-journal.unair.ac.id/JRE>

Plastic Reconstructive and Aesthetic Surgery Department
Faculty of Medicine, Universitas Airlangga - Dr. Soetomo General Academic Hospital
Indonesia



EDITORIAL TEAM

Editor-in-Chief

Dr. Lynda Hariani, dr., Sp.BP-RE(K)

Associate Editor

Prof. Dr. Iswinarno Doso Saputro, dr.,
Sp.BP-RE (K)

Editorial Board

- Dr. M. Rosadi Seswandhana, Sp.B,
Sp.BP-RE(K)
 - Prof. Dr. dr. David Sontani
Perdanakusuma, Sp.BP-RE(K)
 - Prof. Ron-Ming Baek MD, PhD
- Dr. Liew Boon Seng MD, MS (Neurosurg)
- Dr. Herman Yosef Limpat Wihastyoko,
dr., Sp.BP-RE(K)
- Dr. I Nyoman Putu Riasa, dr., Sp.BP-
RE (K)
- Dr. Indri Lakhsmi Putri, dr., Sp.BP-
RE (KKF)
- Yuanita Safitri Dianti, dr., Sp.BP-RE
(K)
- Hastika Saraswati, dr., Sp.BP-RE (K)
 - Alki Andana, dr., Sp.BP-RE (K)
- dr. Robertus Arian Datusanantyo,
M.P.H., M.Ked.Klin, Sp.BP-RE
- dr. Beta Subakti Nata'atmadja, dr.,
Sp.BP-RE
 - Ira Handriani, dr., Sp.BP-RE
- I Made Suka Adnyana, dr., Sp.BP-RE
 - Dr. Muhammed Bahattin Bingül
 - Dr. Wint Shwe Yee Phyo., M.D,
M.Med.Sc., Ph.D.
 - Pang-Yun Chou, M.D.

Managing Editors

- Yanuar Ari Pratama, dr., Sp.BP-RE
 - Kezia Eveline, dr.,

Assistant Editor

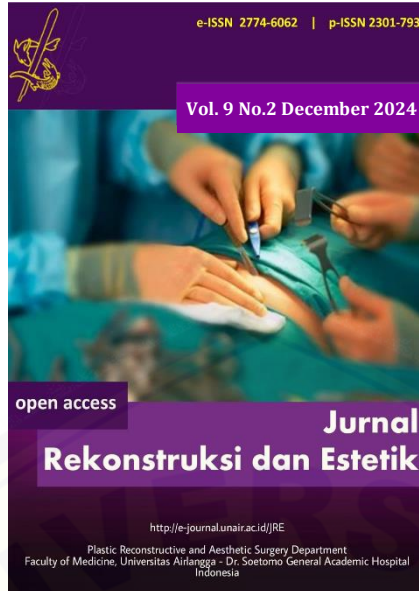Alfiananda Dwi Oktora Nugraheni,
S.Ak

ADDRESS

Plastic Reconstructive and Aesthetic
Surgery Department
Faculty of Medicine, Universitas Airlangga
- Dr. Soetomo General Academic Hospital
Jl. Mayjend Prof. Dr. Moestopo, No. 6-8,
Surabaya, 60285. Indonesia

CONTACT INFO

Phone: (031) 5020091 ext 1314
Email: jre@journal.unair.ac.id



VOL.9 NO.2, DECEMBER 2024

Jurnal Rekonstruksi dan Estetik is a scientific peer-reviewed medical journal which is relevant to doctor and other health-related professions published by the Faculty of Medicine, Universitas Airlangga, Surabaya, Indonesia. Jurnal Rekonstruksi dan Estetik is published twice a year, every **June and December**. Jurnal Rekonstruksi dan Estetik focuses in publishing **case report, review article, systematic review, literature review, meta-analysis and original articles** on the latest medical sciences.

FOCUS AND SCOPE

Burn and Wound, Hand Surgery, Microsurgery, Oncoplastic, Craniofacial, External Genitalia Reconstruction, and Aesthetics.

TABLE OF CONTENT

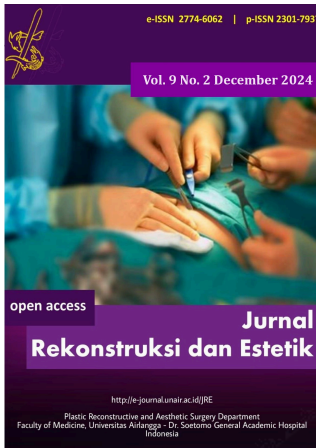CASE REPORT

- | | |
|---|---------|
| • A COMBINATION TECHNIQUE OF AUTOLOGOUS AUGMENTATION AND BREAST LIFTING IN HYPOPLASTIC-THIRD GRADE PTOTIC BREAST: A CASE REPORT | 78-90 |
| • IMPLEMENTATION OF AN OCCLUSAL WAFER IN SEVERE MANDIBULAR FRACTURE CASES WITH POST-ORIF MALOCCLUSION: A CASE SERIES | 91-99 |
| • COMPLETE UNILATERAL CLEFT LIP SURGERY USING MODIFIED ROTATION-ADVANCEMENT FLAP TO ENHANCE AESTHETIC APPEARANCE IN RSPAL DR. RAMELAN HOSPITAL: A CASE SERIES | 100-110 |
| • A COMBINATION OF CHEEK FLAP, CARTILAGE INSERTION, AND FAT TRANSFER ON POST-TRAUMA LOWER EYELID ECTROPION RECONSTRUCTION | 111-119 |
| • EARLY CLEFT LIP REPAIR: A LONG TERM FOLLOW-UP | 120-131 |

ORIGINAL ARTICLES

- | | |
|--|---------|
| • HELMET USE COMPLIANCE SURVEY FOR CRANIOFACIAL TRAUMA PREVENTION AMONG MOTORCYCLISTS IN JAYAPURA CITY RING ROAD | 132-143 |
| • CLINICAL PROFILE AND MANAGEMENT OF HYPERTROPHIC SCARS AT DR. SOETOMO GENERAL ACADEMIC HOSPITAL SURABAYA, INDONESIA | 144-157 |

Vol. 9 No. 2 (2024): Jurnal Rekonstruksi dan Estetik, December 2024



Published: 2024-12-01

Full Issue



FRONT MATTER

Jurnal Rekonstruksi dan Estetik, December 2024

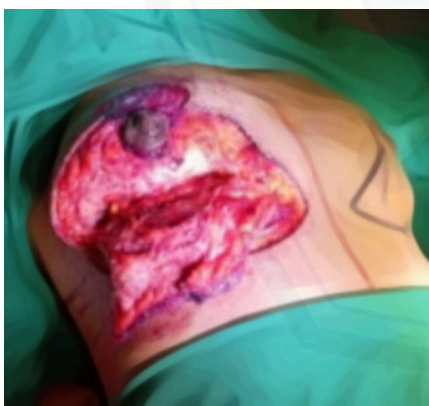JURNAL REKONSTRUKSI DAN ESTETIK

Abstract : 6



pdf : 2

Case Report



A COMBINATION TECHNIQUE OF AUTOLOGOUS AUGMENTATION AND BREAST LIFTING IN HYPOPLASTIC-THIRD GRADE PTOTIC BREAST: A CASE REPORT

Beta Subakti Nataatmadja, Nida' Fahima Amatullah, Loelita Marcelia Lumintang

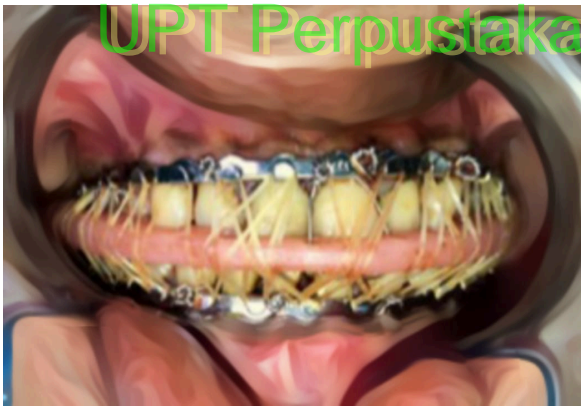
Abstract : 61




78-90


pdf : 23

DOI : 10.20473/jre.v9i2.54614




IMPLEMENTATION OF AN OCCLUSAL WAFER IN SEVERE MANDIBULAR FRACTURE CASES WITH POST-ORIF MALOCCLUSION: A CASE SERIES


 Chintia Amelia Pratiwi, Mirnasari Amirsyah, Teuku Nanda Putra

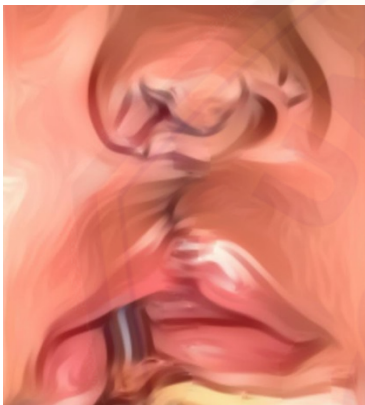
 91-99

 Abstract : 43


 pdf : 12




 DOI : 10.20473/jre.v9i2.54889




COMPLETE UNILATERAL CLEFT LIP SURGERY USING MODIFIED ROTATION-ADVANCEMENT FLAP TO ENHANCE AESTHETIC APPEARANCE IN RSPAL DR. RAMELAN HOSPITAL: A CASE SERIES


 Jessica Novia Hadikhosuma, Bambang Wicaksono, Rionaldo Dhiparedja

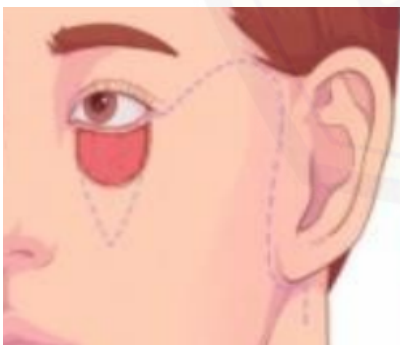 100-110

 Abstract : 64

 pdf : 27




 DOI : 10.20473/jre.v9i2.59067



A COMBINATION OF CHEEK FLAP, CARTILAGE INSERTION, AND FAT TRANSFER ON POST-TRAUMA LOWER EYELID ECTROPION RECONSTRUCTION


 Ulfa Elfiah, Dicky Primadika Aprinova

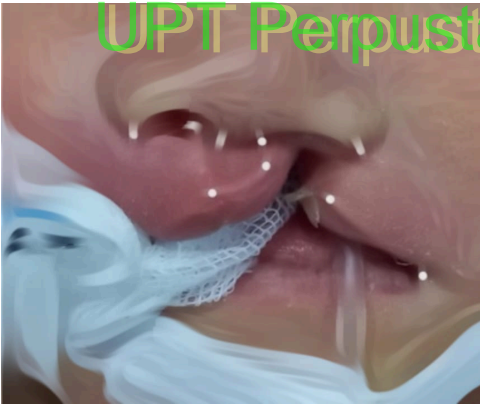
 111-119

 Abstract : 60

 pdf : 19



 DOI : 10.20473/jre.v9i2.59646



EARLY CLEFT LIP REPAIR: A LONG TERM FOLLOW-UP

Yefta Moenadjat

120-131

Abstract : 44

pdf : 15

pdf

DOI : 10.20473/jre.v9i2.60219

Original Article



HELMET USE COMPLIANCE SURVEY FOR CRANIOFACIAL TRAUMA PREVENTION AMONG MOTORCYCLISTS IN JAYAPURA CITY RING ROAD

Hendrikus Masang Ban Bolly, Trajanus Laurens Yembise

132-143

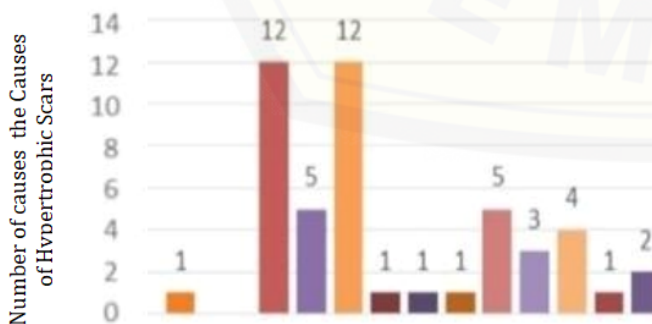
Abstract : 44

pdf : 15

pdf

DOI : 10.20473/jre.v9i2.64397

OUTPATIENTS



CLINICAL PROFILE AND MANAGEMENT OF HYPERTROPHIC SCARS AT DR. SOETOMO GENERAL ACADEMIC HOSPITAL SURABAYA, INDONESIA

Arda Rahmanisa Perdanakusuma, *Iswinarno Doso Saputro*, Evy Evrianti

144-157

Abstract : 46

pdf : 20

pdf

DOI : 10.20473/jre.v9i2.65031

A COMBINATION OF CHEEK FLAP, CARTILAGE INSERTION, AND FAT TRANSFER ON POST-TRAUMA LOWER EYELID ECTROPION RECONSTRUCTION

Ulfa Elfiah^{a*}, Dicky Primadika Aprinova^b

^aPlastic Reconstructive and Aesthetic Surgeon, Dr. Soebandi General Hospital, Jember, Indonesia

^bClinical Student, Dr. Soebandi General Hospital, Jember, Indonesia

ARTICLE INFO

Keywords: Plastic surgery, ectropion reconstruction, ectropion repair, ectropion, quality healthcare

*Corresponding author:

Ulfa Elfiah

Email address:

Ulfa.fk@unej.ac.id

History:

Received: July 24, 2024

Revised: September 2, 2024

Accepted: October 31, 2024

Published: December 1, 2024

JRE : Jurnal Rekonstruksi dan Estetik

e-ISSN:2774-6062; p-ISSN: 2301-7937

DOI:10.20473/jre.v9i2.59646

Open access :

Creative Commons Attribution-ShareAlike 4.0 International License (CC-BY-SA)

Available at:

<https://e-journal.unair.ac.id/JRE/>

How to cite: Elfiah U & Aprinova DP. COMBINATION OF CHEEKFLAP, CARTILAGE INSERTION, AND FAT TRANSFER ON POST TRAUMA LOWER EYELID ECTROPION RECONSTRUCTION. Jurnal Rekonstruksi dan Estetik .2024; 9(2):111-119.

ABSTRACT

Introduction:Ectropion correction surgery is a procedure designed to restore the anterior lamella to its anatomical position. This study aims to propose a combination of cheek flap and fat transfer as a method for post-traumatic ectropion reconstruction surgery.

Case Illustration:A 10-year-old girl presented with ectropion caused by scar formation and volume loss in the infraorbital region following a traumatic incident seven years prior. The procedures performed in this case included a Mustarde rotational cheek flap to reconstruct the scar tissue in the infraorbital region that led to the ectropion, pure ear cartilage insertion to repair the damaged tarsal plate or tarsus, and fat transfer to address the volume loss in the infraorbital area. The donor fat was harvested from the inguinal region

Discussion: The rationale for using the Mustarde rotational cheek flap, cartilage insertion, and fat transfer was based on the wide donor area, particularly in cases where the vertical dimension exceeds the horizontal dimension. This approach is believed to yield better outcomes compared to other methods, such as skin grafts. In this case, fat transfer was employed to restore the volume lost beneath the scar tissue following trauma. This combination technique is thought to be more durable and to provide superior results compared to alternative methods, while also being economically advantageous.

Conclusion: The combination of the Mustarde rotational cheek flap, cartilage insertion, and fat transfer is believed to improve the outcomes of the reconstruction procedure following scar tissue release and correction of volume loss beneath the scar.

Highlights:

1. This study introduces an innovative approach for post-traumatic ectropion reconstruction in children by combining Mustarde rotational cheek flap, cartilage insertion, and fat transfer.
2. This method effectively addresses the challenges of cicatricial ectropion caused by injuries or burns, leading to improved, durable, and cost-effective outcomes in restoring eyelid function and volume.



INTRODUCTION

Ectropion is a condition characterized by the outward rotation of the eyelid, often affecting the lower eyelid unilaterally or bilaterally.^{1,2} This outward rotation can expose the inferior cornea, leading to a foreign body sensation, superficial punctate keratopathy, corneal erosion, and even corneal ulceration.^{3,4} When ectropion is caused by scarring from chemical burns, trauma, or surgery, it is referred to as cicatricial ectropion, which results in mechanical shortening of the anterior lamella and downward pulling of the eyelid.⁵

Among the various forms of ectropion, involutional ectropion is the most common acquired form, with an incidence that increases with age due to involutional factors such as horizontal weakness and vertical instability of the eyelids. Paralytic ectropion occurs due to weakness of the seventh cranial nerve (facial nerve), which may result from a stroke, tumor, or surgical complications. Cicatricial ectropion can occur across various age groups and results from chemical burns or scarring due to trauma or surgery. In cicatricial ectropion, there is mechanical shortening of the anterior lamella of the eyelid, causing the eyelid to be pulled downwards. Mechanical ectropion is a type that is rarely encountered and is due to specific anatomical causes, such as dermatochalasis, edema, chalazion, orbital fat, or eyelid tumors.³

The implications of ectropion are significant, particularly because the lower eyelids are highly susceptible to malposition. Even small scars or minor irregularities can lead to patient dissatisfaction. Consequently, ectropion, lagophthalmos, and retraction often arise as unintended outcomes of attempts to repair or rejuvenate the periocular area, which can also pose serious risks to the eyes. Therefore, the ability to prevent these issues and address them when they occur is crucial for any facial surgeon.⁶

Eyelid reconstruction poses significant challenges in plastic surgery due to the need to address aesthetic, functional, and

anatomical considerations.⁷ The primary goal of ectropion surgery is to restore the normal length of the anterior lamella. Various methods exist, including composite flaps, skin grafts, mucosal membrane grafts, and fat transfer.⁸ However, there is currently no standard, widely accepted algorithm for ectropion reconstruction surgery.⁷

This case report presents a 10-year-old girl who sought treatment for a concave and downward-pulled infraorbital region following a traumatic incident seven years earlier. Physical examination revealed cicatricial ectropion and volume loss in the right lower eyelid and infraorbital region. The purpose of this study is to propose an innovative combination of cheek flap, cartilage insertion, and fat transfer for the reconstruction of post-traumatic ectropion, presenting a novel approach compared to traditional methods.

CASE ILLUSTRATION

The patient was a 10-year-old girl who visited the plastic surgery clinic with her family because her infraorbital region appeared depressed and pulled downward following a traumatic incident. When she was 3 years old, she was struck in the right eye by a swinging swing. In 2023, reconstruction surgery was planned for her but was rescheduled due to her general condition, which included existing comorbidities and inadequate blood supply prior to the surgery.

During the physical examination in the clinic, she was found to be in good general condition, fully conscious, and with stable vital signs. A neurological examination revealed no abnormalities in the facial nerve. Eye movement was unrestricted, indicating no issues with the Oculomotor (III), Trochlear (IV), or Abducens (VI) nerves. The light and corneal reflexes in both eyes were also normal, suggesting no abnormalities in the Optical (II), Oculomotor (III), Trigeminal (V), or Facial (VII) nerves.

Upon examination, ectropion was observed on the right lower eyelid, with depression noted in the right infraorbital



region extending from the lateral canthus to the pre-auricular area (Figure 1). Palpation revealed that the skin around the eyelid was adhered to the bone, extending two fingers below the eye. *Punctum lacrimalis* was intact.

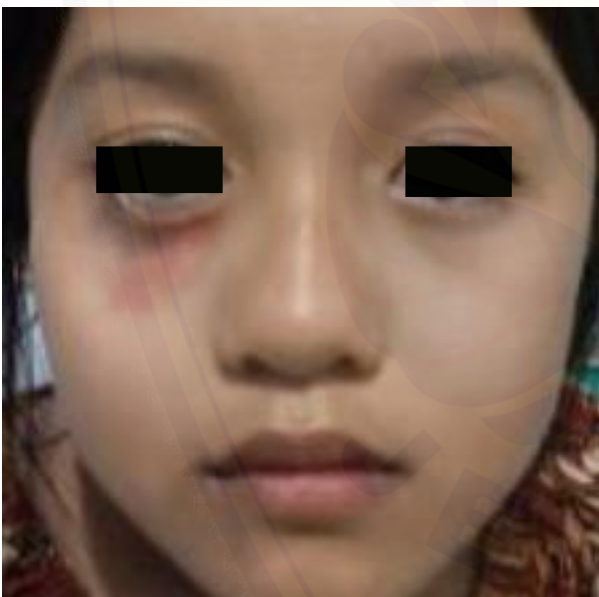
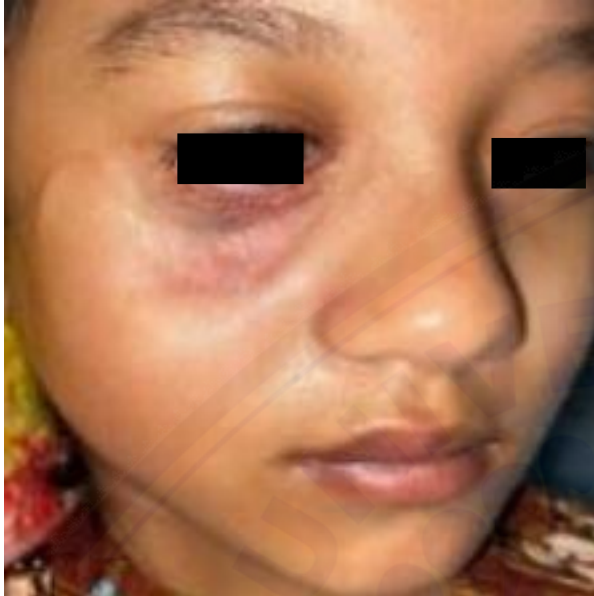
Figure 1. Ectropion on Right Lower Eyelid Before the Procedure

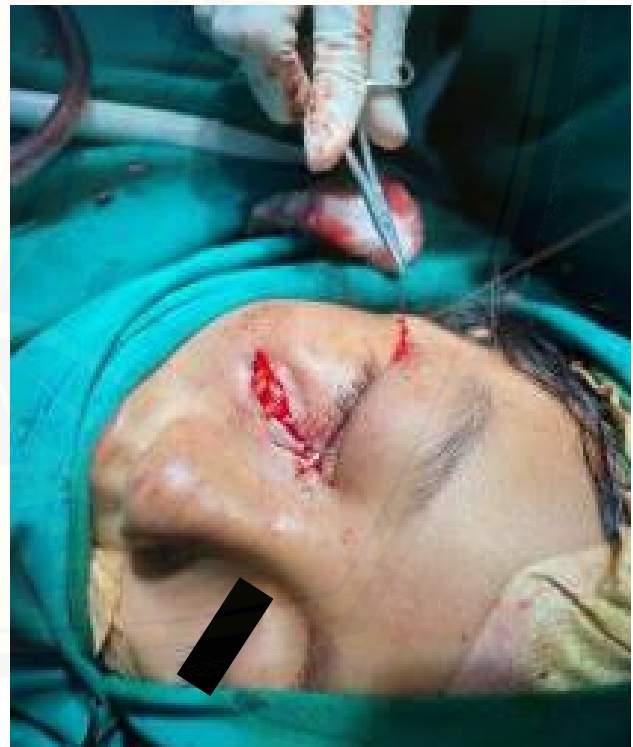A Contrast Head Computed Tomography (CHCT) scan was performed on September 26th, 2023, which revealed thinning of the buccal soft tissue in the infraorbital region due to soft tissue fibrosis. Based on the physical examination and supporting tests,

the patient was diagnosed with cicatricial ectropion of the right lower eyelid, accompanied by volume loss in the infraorbital region.

Surgery Procedures

Before the surgery, the participant and her family provided informed consent for the procedures and this case report, following a thorough explanation by the author, who also served as the surgeon. The consent was given both verbally and in written form by her guardian.

The surgery was performed under general anesthesia, with the patient positioned supine. The surgical area was disinfected using povidone iodine. An incision was made along the scar in the infraorbital region (middle malar), extending through the anterior lamella of the right lower eyelid and terminating in the pre-auricular region (Figure 2).



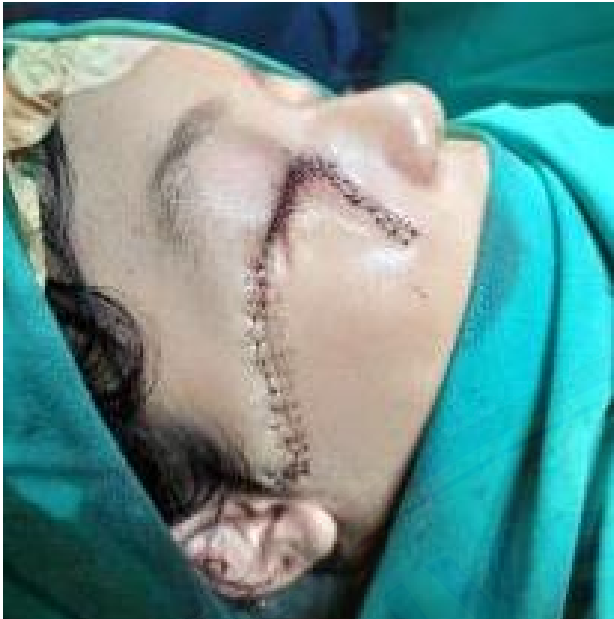

Figure 2. Surgical Incision in the Infraorbital Region During and After the Surgery

The incision was made according to the cheek flap design around the lesion. During the surgery, it was found that there was depression of the inferior rim of the orbit, partial damage to the inferior tarsal plate/tarsus, and partial loss of the orbicularis oculi muscle and infraorbital fat pads. After making the incision, the surgeon released the scar tissue and inserted a pure cartilage to replace the damaged tarsal plate/tarsus. The donor cartilage was taken from the helix of the right ear. The Mustarde method was then used to perform the cheek flap procedure, covering the defect in the subciliary area. Dermofat graft transfer was utilized to fill and increase the volume of the defect around the medial canthus and nasal flank to reduce tension on the flap. The donor fat was harvested from the right inguinal region. In order to account for anticipated tissue resorption, about 120% of the intended amount of the dermofat graft was harvested. Our surgical expertise indicated that harvesting up to 6×4 cm was feasible. The incision site was closed after the carefully planned dermofat graft was placed as needed to accommodate the dead space at the deformity site. Lastly, a fixation suture was used to complete the treatment, taking

into account the patient's asymmetry and form.⁸

Postoperative Assessment

During the surgery, a stent was placed to bridge and close the gap between the superior and inferior eyelids. The stent was also used to secure the position of the defect in its anatomical location. After the surgery, closed wound care was applied for three consecutive days (Figure 3). The wound was cleaned with normal saline, and gentamicin ointment was applied to keep the surgical wound moist and covered with dressing. After seven days, the dressing was removed for evaluation, and the stitches were taken out periodically (Figure 4).

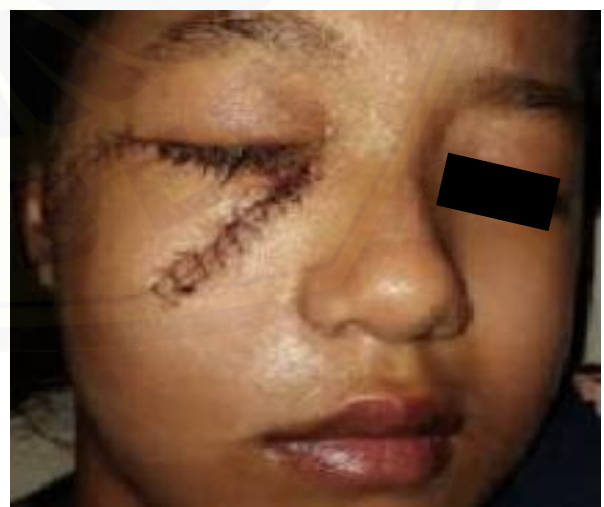
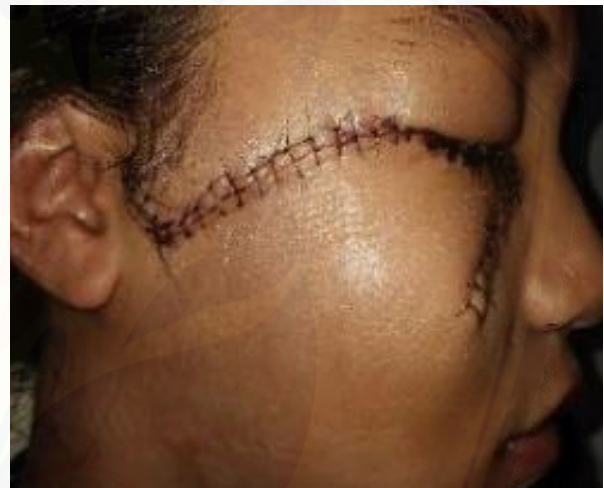
Figure 3. Closed Wound Care on the Last Day of Admission and Third Day After the Procedure

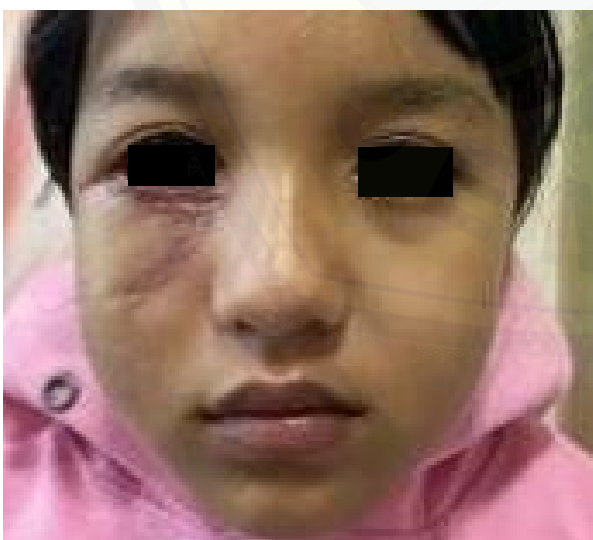
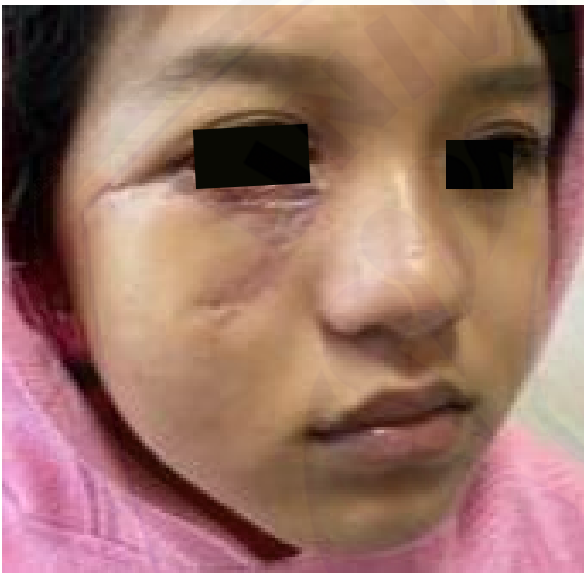
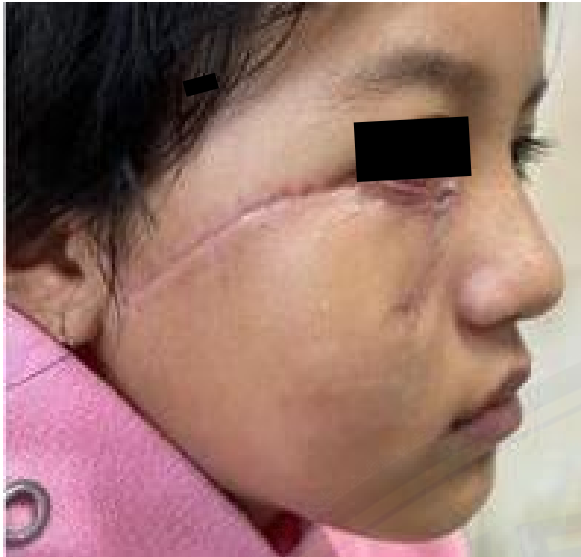Figure 4. Dressing Removal and Stitch Evaluation on the Seventh Day After the Procedure

A follow-up examination was scheduled to evaluate the ectropion. The patient and her family were instructed to massage the infraorbital area to loosen the scar formation and prevent the pulling of the scar tissue. The patient was also encouraged to exercise her eyes by opening and closing them with maximum effort. If the patient was found asleep with her eyes open, it was advised to close them using adhesive tape. Follow-up examinations were to be conducted every three months (Figure 5).

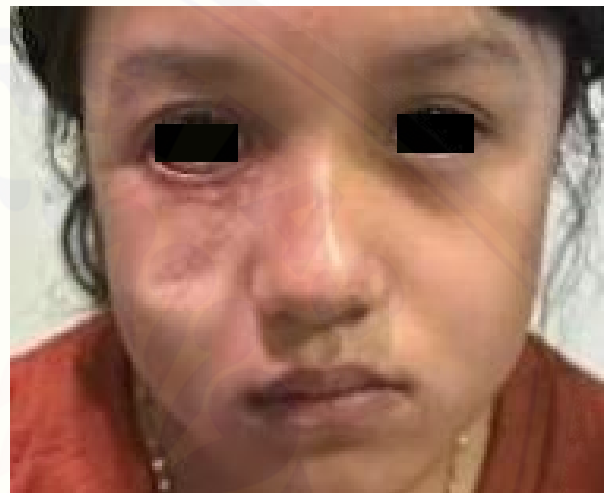


Figure 5. Follow-Up Examination and Postoperative Care Several Months After the Procedure

DISCUSSION

Ectropion is a condition characterized by the outward rotation of the eyelid, often affecting the lower eyelid, which can lead to irritation, tearing, and cosmetic concerns.^{9,10} This condition can be categorized into congenital types, such as congenital ectropion and congenital upper eyelid eversion, and acquired types, including involutional, cicatricial, paralytic, or mechanical.¹⁰ Cicatricial ectropion, specifically, arises from the formation of scar tissue following eyelid injuries or burns, causing mechanical shortening of the anterior lamella and resulting in the eyelid being pulled downwards.¹¹ Treatment for cicatricial ectropion typically involves surgical intervention aimed at releasing scar tissue



and lengthening the anterior lamella, with or without horizontal shortening, to restore proper eyelid function and appearance.^{3,4}

Cicatricial ectropion of the lower eyelid can be challenging to treat, with surgical interventions depending on the underlying causes, eyelid mechanics (horizontal or vertical laxity), external position, and severity of the condition. Techniques such as lateral tarsal strip, canthopexy, or medial spindle incision are employed based on the eyelid's location and laxity. If intractable laxity occurs with loss of supportive tissue, more extensive surgical procedures, including transplantation of auricular cartilage and fascia lata, may be necessary.¹² However, postoperative complications, including tenting, cosmetic dissatisfaction, and medial inferior ectropion, can arise. A common issue with intractable lower eyelid ectropion is lagophthalmos, resulting from impaired tear conduction due to the separation of the lower lacrimal punctum from the lacrimal lake.^{13,14} This is because other reconstructive procedures typically only address horizontal traction, without accounting for the spherical structure of the eye.¹⁵

Treatment for cicatricial ectropion typically involves a combination of techniques aimed at lengthening the skin surface and resecting the subcutaneous cicatricial tissue to restore normal anatomical function and appearance.⁵ One of the most effective approaches in reconstructing cicatricial ectropion is the use of local random flaps, which have been shown to yield better outcomes compared to the skin graft method.⁹ Unlike skin grafts, flap methods offer superior advantages in terms of color match, texture, and blood flow, contributing to more natural and aesthetically pleasing results.

In this case, the Mustarde cheek rotational flap technique was used after releasing the cicatricial tissue. This method helped restore the lost tissue and correct the ectropion. By using tissue from the adjacent cheek, the procedure aimed to improve both the appearance and function of the affected area, ensuring better healing and a more

natural result.⁹

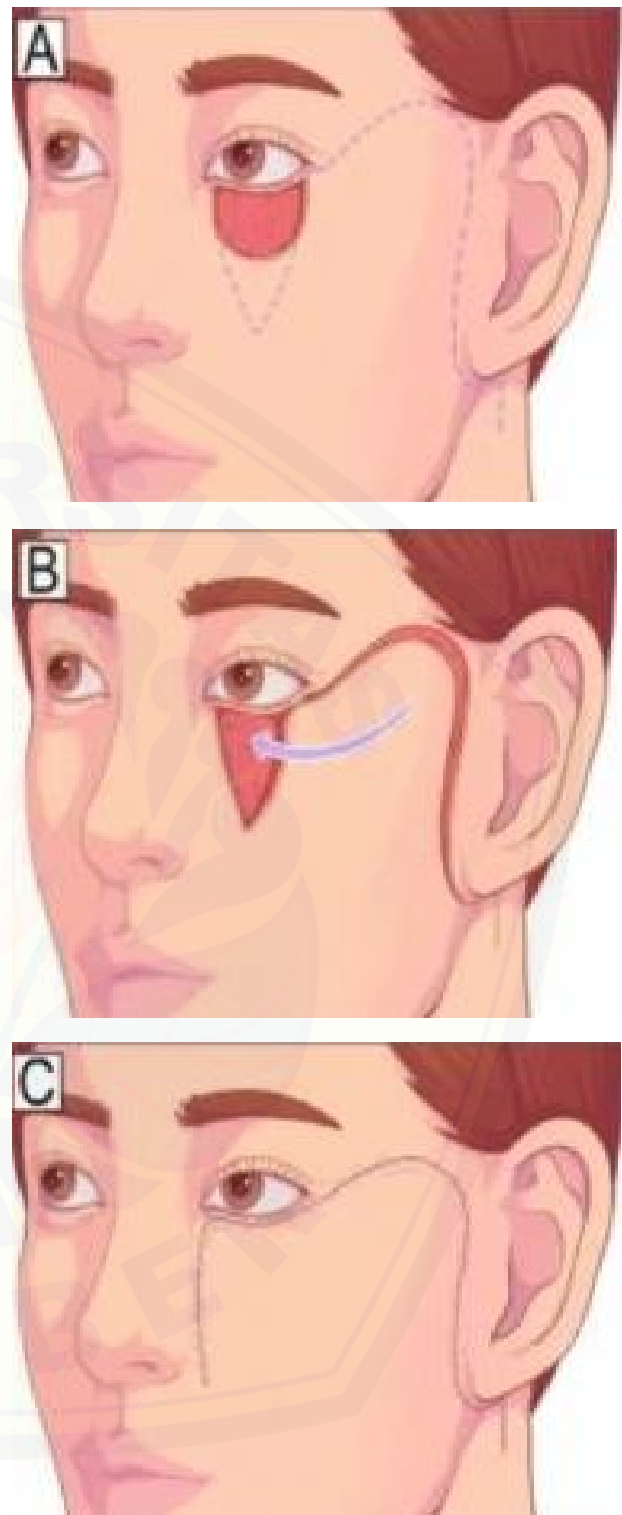


Figure 6. Mustarde Rotational Cheek Flap Procedure

The surgery was performed under general anesthesia with the patient in a supine position, and the surgical area was



disinfected. An incision was made along the scar in the infraorbital region, extending through the lower eyelid to the pre-auricular area. During the procedure, issues such as depression of the inferior orbital rim and partial damage to the tarsal plate were noted. A cartilage flap from the right ear was inserted to replace the damaged tarsal plate, and a Mustarde cheek flap was used to cover the defect. Fat transfer from the right inguinal region was also performed to enhance volume and reduce tension on the flap.¹⁶ Postoperatively, a stent was placed to secure the eyelids, and wound care was conducted for three days. Follow-up instructions included massaging the area to prevent scar formation and regular eye exercises, with examinations scheduled every three months to monitor the ectropion.

The Mustarde cheek rotational flap is one of the flap methods used in ectropion reconstruction, utilizing flaps from the lateral cheek tissue and preauricular area. This method is the treatment of choice for deep vertical defects involving the anterior lamella of the lower eyelid, especially when the vertical aspect of the defect is larger than the horizontal aspect. The advantage of this technique is that it can be applied to large donor areas with good vascularization.⁹ Research conducted by Kiran et al. (2022) showed that the flap method yields more optimal results than grafting in ectropion correction.⁷ Observations in the group that underwent reconstruction using the graft method indicated a recurrence of ectropion, while no recurrence was found in the group using the flap method.⁸

Despite these advantages, this technique has several drawbacks, including the use of a relatively thick flap from the cheek area, which may not be ideal for the eyelid. Additionally, this procedure has the potential to cause damage to the facial nerve (N. VII).⁹

The auricular cartilage insertion procedure performed during surgery aims to replace part of the damaged inferior tarsus. Auricular cartilage is known for its ability to mimic the function of the tarsus due to its

thin, soft, and malleable nature, allowing it to adapt to the curvature of the eyeball. Cartilage insertion is also an easy procedure to perform with a high success rate, as cartilage can survive on the regional blood supply.¹⁷ Research conducted by Watanabe et al. (2015) demonstrated that using auricular cartilage in ectropion reconstruction successfully maintained normal eyelid mobility without causing fixation of the lower eyelid.¹⁸ All study patients showed good anatomical and functional results after surgery, with no complications or need for reoperation.

The use of fat transfer is recommended as a technique for increasing soft tissue volume and improving contours in the facial area.¹⁹ In this case, the fat transfer method aims to restore volume in the flap area that was lost after the patient experienced trauma and underwent reconstruction procedures. Fat transfer has several advantages, including longer-lasting results compared to other methods, such as hyaluronic acid gel.⁸ However, it also carries risks of long-term instability due to fat tissue resorption and has a higher susceptibility to infection. While there are many donor area options, the quantity of available fat donors can be quite limited.⁵

In this case, the fat donor was taken from the right inguinal region. This choice was based on the recommendation that, in young patients with low abdominal circumference, fat should be harvested from lower body areas, such as the buttocks and upper thighs.¹⁹ Research by Choi et al. (2020) shows that using fat from the inguinal region is an effective, simple, and affordable surgical option for facial deformities with cicatricial tissue.⁵

The combination of the cheek flap and fat transfer methods is expected to yield optimal repair results after scar removal, restoring eyelid function to near normal and improving volume in areas experiencing loss.

This research has been ethically approved by the ethics committee of the Department of Education and Research at Dr.

Soebandi General Hospital . Patients in this study have consented to all forms of publication, including clinical photos, procedural history, and evaluations of the results. A limitation of this study is the short postoperative observation period, which restricts the ability to compare the progress of the repair process and the success of cicatricial tissue reconstruction and volume improvement. Therefore, longer-term observation is necessary to evaluate the results of this intervention. This study provides novelty by involving a combination of several methods for ectropion reconstruction.

CONCLUSION

Cicatricial ectropion is the outward rotation of the eyelid caused by injury or burns to the eye. The combination of the Mustarde cheek rotational flap, cartilage insertion, and fat transfer is believed to yield better outcomes in the reconstruction procedure following scar tissue release and correction of volume loss beneath the scar.

ACKNOWLEDGMENTS

The authors express their gratitude to the Plastic Reconstructive and Aesthetic Surgeon Department at Dr. Soebandi General Hospital, Jember, Indonesia for their valuable support. The authors also extend their appreciation to the patient and her guardian for granting permission to compile this study.

CONFLICT OF INTEREST

This study does not involve any conflicts of interest.

FUNDING DISCLOSURE

This research was not funded by any party.

AUTHOR CONTRIBUTION

AE contributed to the planning, data collection, analysis, writing, and approval of

the paper for publication. DPA oversaw the research design, coordinated data collection and analysis, and led the writing and editing process for publication.

REFERENCES

1. Hakim F and Phelps PO. Entropion and ectropion. *Disease-a-Month*. 2020; 66(10):101039. DOI:10.1016/j.disamonth.2020.101039
2. Sidana S and Kadam S. Cicatricial ectropion of lower eyelid: a report of two cases. *Journal of cutaneous and aesthetic surgery*. 2021; 14(2):233-237. DOI: 10.4103/JCAS.JCAS_133_19
3. Skorin L and Rebecca L Ectropion: Classification, Diagnosis, and Management. *Consultant*. 2018; 58(6): e180. Available at <https://www.consultant360.com/article/s/ectropion-classification-diagnosis-and-management>
4. Skorin L, Nate Lighthizer, Selina McGee, Richard Castillo, and Karl Stonecipher. *The Ophthalmic Office Procedures Handbook*. Philadelphia. *Lippincott Williams and Wilkins*; 2023
5. Choi MH, He WJ, Son KM, Choi WY, and Cheon JS. The efficacy of dermofat grafts from the groin for correction of acquired facial deformities. *Archives of Craniofacial Surgery*, 2020; 21(2):92. DOI: 10.7181/acfs.2020.00038
6. Tao JP. *Plastic Surgery of the Lower Eyelids*. Cham: Springer;2023. DOI:10.1007/978-3-031-36175-3
7. Kiran S, Khan FAA, Ali H, Kumar S, Sami W, and Khursheed RM. Surgical Correction of Ectropion: Comparison Between Full Thickness Skin Grafts and Local Flaps. *Pakistan Armed Forces Medical Journal*, 2022; 72(3):961-965. DOI: 10.51253/pafmj.v72i3.5348
8. Choi MH, He WJ, Son KM, Choi WY, and Cheon JS. The efficacy of dermofat grafts from the groin for correction of acquired facial deformities. *Arch Craniofac Surg*. 2020 Apr;21(2):92-98. doi: 10.7181/acfs.2020.00038. Epub 2020 Apr



20. PMID: 32380808; PMCID: PMC7206454.
9. Harceaga OI, Nicoara SD, Muntean V, Grigorescu D, and Muntean MV. Fat transfer for cicatricial ectropion in lamellar ichthyosis. *European Journal of Plastic Surgery*, 2016; 39: 57-60. DOI:10.1007/s00238-015-1167-1
10. Yan Y, Fu R, Ji Q, Liu C, Yang J, Yin X, et al. Surgical strategies for eyelid defect reconstruction: a review on principles and techniques. *Ophthalmology and Therapy*, 2022; 11(4): 1383-1408. DOI:10.1007/s40123-022-00533-8
11. Hötte GJ, de Keizer ROB, Sigurðsson H, and Paridaens D. Ectropion. In: Quaranta Leoni, F.M., Verity, D.H., Paridaens, D. (eds) *Oculoplastic, Lacrimal and Orbital Surgery*. Springer, Cham. 2024. DOI:10.1007/978-3-031-39634-2_9
12. Goel R. *Manual of Oculoplasty*. New Delhi: Jaypee Brothers Medical Publishers; 2019:352. DOI:10.5005/jp/books/18237
13. Lin P, Kitaguchi Y, Mupas-Uy J, Sabundayo MS, Takahashi Y, and Kakizaki H. Involutional lower eyelid entropion: causative factors and therapeutic management. *Int Ophthalmol*. 2019; 39(8): 1895-1907. DOI: 10.1007/s10792-018-1004-1
14. Hocaoglu E, Özden BC, Aydin H. Lower eyelid reconstruction in a paediatric face: a one-stage aesthetic approach using the versatile temporoparietal fascia flap. *J Plast Reconstr Aesthet Surg*. 2012;65(9):e246-9. DOI: 10.1016/j.bjps.2012.02.025
15. Ko MJ, Erickson BP, Blessing NW, and David TT. The flip-back myocutaneous advancement flap for periocular reconstruction. *Ophthalmic Plast Reconstr Surg*. 2019;35(6):569-573. DOI: 10.1097/IOP.0000000000001377
16. Takaya KMD, Sakai SMD, and Kishi KMD. Treatment of Cicatricial Lower Eyelid Ectropion with Suture of Horner Muscle Combined with Fascia Transplantation. *Plastic & Reconstructive Surgery-Global Open*. 2024; 12(3): e5675. DOI: 10.1097/GOX.0000000000005675
17. de Leó F, and Carrillo LFM. Using Mustardé Flap for Reconstruction of a Traumatic Facial Injury: Case Report. *Modern Plastic Surgery*, 2024; 14(4):51-56. DOI: 10.4236/mps.2024.144006
18. Ochiai H, Yagi N, Oka A, Hirata E, Yabuki H, and Fujii M. Composite Auricular Chondrocutaneous Graft Is Useful For Lower Eyelid Reconstruction after Surgery for Cancer of the Maxilla. *Global Surgery*. 2016;2(4). DOI: 10.15761/GOS.1000144
19. Watanabe A, Katori N, Selva D, Hayashi K, and Kinoshita S. Modified auricular cartilage sling for paralytic ectropion. *Journal of plastic, reconstructive & aesthetic surgery*, 2015; 68(7): 902-906. DOI: 10.1016/j.bjps.2015.03.019
20. Xie Y, Huang RL, Wang W, Cheng C, and Li Q. Fat grafting for facial contouring (temporal region and midface). *Clinics in plastic surgery*, 2020; 47(1):81-89. DOI: 10.1016/j.cps.2019.08.008



JPT Perpustakaan Universitas Jember
JURNAL REKONSTRUKSI DAN ESTETIK

e-ISSN: 2774-6062 p-ISSN: 2301-7937

**DEPARTEMEN BEDAH PLASTIK REKONSTRUKSI DAN ESTETIK
FAKULTAS KEDOKTERAN UNIVERSITAS AIRLANGGA**

Jl. Mayjen. Prof. Dr. Moestopo 6-8 Surabaya

Telp. 1314/ 5020091 Fax. 5046391 Email : bedahplastiksurabaya@yahoo.com

Dec 2nd 2024

Dear corresponding authors

Ulfa Elfiah,

Plastic Reconstructive and Aesthetic Surgeon,

Dr. Soebandi General Hospital, Jember, Indonesia

We are pleased to inform that your paper:

“ A COMBINATION OF CHEEK FLAP, CARTILAGE INSERTION, AND
FAT TRANSFER ON POST-TRAUMA LOWER EYELID ECTROPION
RECONSTRUCTION ”

Co-author(s): Dicky Primadika Aprinova

Is accepted for publication in 2024

Thank you for your submission to our journal.



Dr. Lynda Hariani, dr., Sp. BP-RE(K)
Editor-in-Chief