


MAKALAH ILMIAH

Exploring Melanin Expression through Immunohistochemistry in Skin Grafts after Robusta coffee BP-42 extract Gel Administration: A Novel Approach to Understanding Pigmentation and Regeneration"

dr. Ulfa Elfiah, M.Kes., Sp.BP-RE., Subsp.L.B.L.(K)
NIP.197607192001122001

- Tenaga Pengajar
Fakultas Kedokteran Universitas Jember

KEMENTERIAN PENDIDIKAN, KEBUDAYAAN, RISET
DAN TEKNOLOGI UNIVERSITAS JEMBER



Makalah Ilmiah disampaikan pada:
*The 26th Annual Scientific Meeting of the
Indonesian Association of Plastic
Reconstructive and Aesthetic Surgeons
(InaPRAS)*
*Boosting Scientific Works Through
Collaborative Spirit*
23-25 Agustus 2023



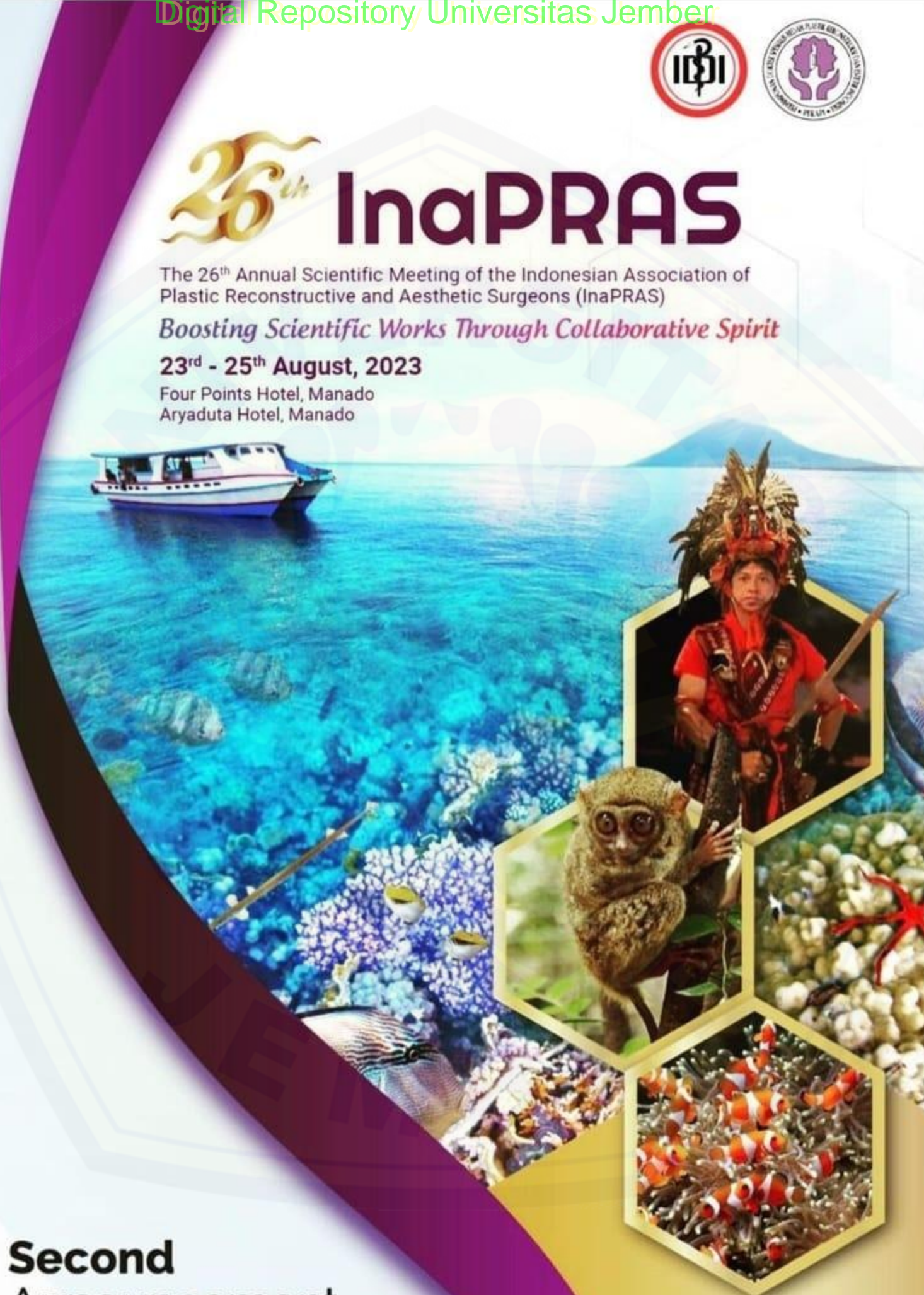
26th InaPRAS

The 26th Annual Scientific Meeting of the Indonesian Association of Plastic Reconstructive and Aesthetic Surgeons (InaPRAS)

Boosting Scientific Works Through Collaborative Spirit

23rd - 25th August, 2023

Four Points Hotel, Manado
Aryaduta Hotel, Manado



**Second
Announcement**



The 26th Annual Scientific Meeting of the Indonesian Association of Plastic Reconstructive and Aesthetic Surgeons (InaPRAS)
Boosting Scientific Works Through Collaborative Spirit
 23rd - 25th August, 2023
 Four Points Hotel, Manado
 Aryaduta Hotel, Manado



ORAL PRESENTATION 3

DATE : Thu, 24th August 2023

TIME : 16.00 - 16.10 WITA

ROOM : Orchid-2

NO	CODE	TIME	NAME	CITY	PRESENTATION TITLE	INSTITUTION
1	OP 020	16.00 - 16.10	Anak Agung Ngurah Andri Ginesthira	Bali	The Effectiveness of Binahong Leaf Extract Gel (Anredera Cordifolia (Ten) Steenis) for Mid-Dermal Burn in Wistar Rats	Plastic Reconstructive and Aesthetic Surgery, Udayana University
2	OP 007	16.10 - 16.20	Meily Anggreini	Surakarta	The Comparison of The Effectiveness of Density in Bone Healing Process Using The Granules Type of Synthetic Bone Graft Substitute Versus Without Using The Granules Type of Synthetic Bone Graft Substitute in Maxillary Fracture at Dr. Moewardi General Hospital : An Experimental Study	Surakarta Resident of General Surgery Specialist Program, Medical Faculty of Sebelas Maret University, Surakarta, Central Java, Indonesia
3	OP 008	16.20 - 16.30	Emil Muzammil	Aceh	The Effect of Aqueous Extract Kirinyu (Chromolaena Odorata (L) R.M.King & H.Rob.) Leaf on Phase 2 Collagen Density Wound Healing in Mice (Mus Musculus)	Medical Faculty of Syiah Kuala
4	OP 009	16.30 - 16.40	Marina Tandarto	Samarinda	Burn Wound Healing Comparison in Mus Musculus Mice Using Feracrylum 1%, Tulle, and Silver Sulfadiazine During Proliferation Phase	Faculty of Medicine, Mulawarman University, Samarinda, Indonesia
5	OP 011	16.40 - 16.50	Nurmalia Fitria Ningrum	Bali	Effect of Propanolol and Metformin Administration on Wound Healing with Acceleration of Epithelialization and Increase of Angiogenesis in Burns Wounds of Male Wistar Rats	Udayana University
6	OP 016	16.50 - 17.00	Ulfah Elfiah	Jember	Exploring Melanin Expression Through Immunohistochemistry in Skin Grafts After Robusta Coffee BP-42 Extract Gel Administration: A Novel Approach to Understanding Pigmentation and Regeneration	Faculty of Medicine, Jember University
7	OP 022	16.50 - 17.00	Tomie H Soekamto	Makassar	The Combination of Stromal Vascular Fraction Cells and Platelet-rich Plasma Increases Fibroblast Growth Factor 2 and Insulin-like Growth Factor 1 in Full Thickness Burn Injury	RSUP dr Wahidin Sudirohusodo Makassar

Exploring Melanin Expression through Immunohistochemistry in Skin Grafts after Robusta coffee BP-42 extract Gel Administration: A Novel Approach to Understanding Pigmentation and Regeneration"

ABSTRACT:

This study examines the efficacy of kojic acid and Robusta BP-42 coffee bean extract in reducing skin hyperpigmentation in rats with skin grafts. Kojic acid is a commonly used compound for pigmentation reduction; however, it can cause adverse effects like skin irritation, redness, and itching in some patients. Robusta BP-42 is a superior variety of robusta coffee found in Indonesia, specifically provided by the Indonesian Coffee and Cocoa Research Institute in Jember Regency, East Java. BP-42 coffee beans are distinguished by their exceptional quality and sensory attributes compared to other strains. The experiment involved three groups of rats with grafted skin: one group was treated with a 2% kojic acid gel (positive control), another with a 5% robusta BP-42 coffee extract gel, and the third with a placebo gel (negative control). The grafted skin was observed and photographed on days 0, 4, 7, 11, 18, and 21, with skin pigmentation measurements conducted using Image J software. Histological analysis was performed on days 7, 14, and 21 for all treatment groups. These preparations were stained immunohistochemically with anti-tyrosinase antibody (T311). The results of the immunohistochemical examination in the negative control group showed the presence of melanocyte cell anti-tyrosinase antibody expression that was immunopositive on days 7, 14, and 21. Meanwhile, the positive control and treatment groups showed the same results, decreasing melanocyte cell anti-tyrosinase antibody expression from immunopositive to immunonegative starting on day 14. This research proves that the gel of robusta coffee extract administration decreases melanin production in skin graft wound healing. So robusta coffee extract gel can be an alternative to prevent the process of increasing pigmentation after skin grafting.

KEYWORDS: Coffee, hyperpigmentation, robusta, tyrosinase, skin graft, melanin

1. Introduction

One of the best methods to cure wounds is the skin graft, although it has drawbacks like hyperpigmentation. Hyperpigmentation occurs due to :

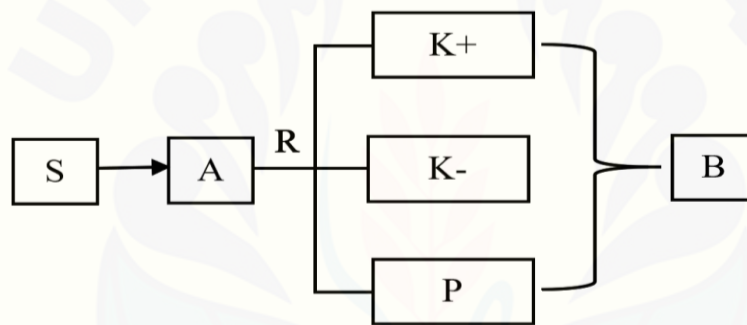
- the DOPA reaction and melanin enzymes such as Tyrosinase, Tyrosinase-Related Protein (TYRP1), and DOPA-chrome Tautomerase (TYRP2)
- The overexpression of these enzymes can last for four weeks after the skin graft.
- The contraction process of the skin graft causes melanin accumulation and aggravates the degree of pigmentation.
- Melanosomes in the skin grafted become more prominent, more pigmented, and resistant to lysosomes, leading to more severe pigmentation
- Numerous medical interventions have been identified to address the concern of hyperpigmentation like hydroquinone and kojic acid

- Nevertheless, hydroquinone and kojic Acid has the potential to cause localized skin irritation, itching, redness
- Hydroquinone is leading to a phenomenon known as post inflammatory hyperpigmentation, which could worsen the overall skin pigmentation condition.

2. Material and Method

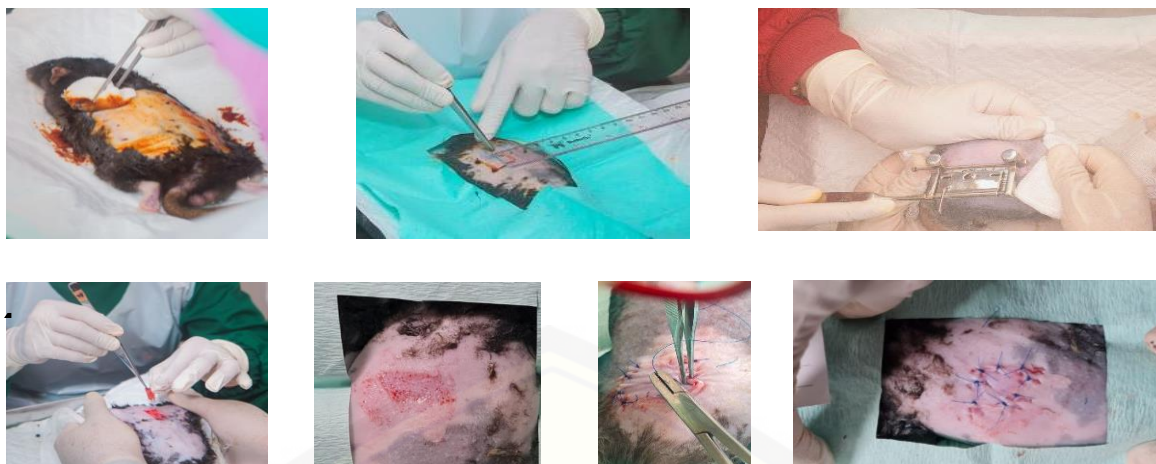
The experiment involved three groups of long Evans Rats with grafted skin: one group was treated with:

1. a 2% kojic acid gel (positive control),
2. a 5% robusta BP-42 coffee extract gel,
3. the third with a placebo gel (negative control).



The grafted skin was observed and photographed on days 0, 4, 7, 11, 18, and 21, with skin pigmentation measurements conducted using Image J software and Histological analysis was performed on days 7, 14, and 21 for all treatment groups. These preparations were stained immunohistochemically with anti-tyrosinase antibody (T311).

- Disinfection of rat backs
- Make a graft size
- Graft retrieval with a humby knife
- Acquired graft
- Donor wounds
- Graft suturing on the original donor
- Skin graft on donor wounds ready for treatment



3. Results

The results of immunohistochemical examination in the negative control group showed the expression of immunopositive melanocyte cell tyrosinase antibodies on days 7, 14 and 21. While in the negative control group and treatment showed the same results where there was a decrease in the expression of melanocyte cell tyrosinase antibodies from immunopositive to immunonegative starting on day 14. This suggests that the administration of robusta coffee extract gel has an effect on decreasing melanin production on skin graft wound healing. So that robusta coffee extract gel can be an alternative to prevent the process of increasing pigmentation after skin graft.

4. Discussion

The results show that robusta coffee extract BP-42 has an excellent clinical appearance and is similar to kojic acid as a positive control Robusta coffee BP-42 has similar effectiveness to kojic acid because it has a variety of active compounds that support tyrosinase inhibition : hydroquinone, free fatty acid, trigonelline, chlorogenic acid and caffeine. Chlorogenic acid could inhibit melanogenesis by binding to the active side of the tyrosinase enzyme.

In silico research shows that the mechanism of tyrosinase inhibition by caffeine occurs due to the formation of a stable protein-ligand complex called the enzyme-caffeine complex. The presence of this complex causes inhibition of enzymatic reactions so that the melanogenesis process cannot enter the next stage. The presence of hydroquinone in Robusta coffee extract BP 42 strengthens the reason that it can be used as a natural depigmentation agent.

Trigonelline is an appropriate compound for reducing inflammation due to the activity of hydroquinone. The decrease in the inflammatory process will reduce the stimulation of the mechanism of pigmentation formation after wound healing.

5. Conclusion

Robusta BP-42 coffee extract from the Jember district has bioactive compounds related to skin graft pigmentation and is proven to have an antityrosinase effect. It results in pigmentation changes in clinical appearance and histologically in skin graft wounds. So robusta coffee extract gel can be an alternative to prevent the process of increasing pigmentation after skin grafting.



BIBLIOGRAPHY

- Wahyuni DK, Ansori ANM, Vidiyanti F. GC-MS analysis of phytocomponents in methanolic extracts of leaf-derived callus of *Justicia gendarussa* Burm.f. *Biosci Res* 2017; 14: 668–677.
- Yudantara IMA, Cahyani NKN, Saputra MAW, et al. Chlorogenic acid and kojic acid as anti-hyperpigmentation: in silico study. *Pharm Reports* 2022; 1: 23.
- Eun Lee K, Bharadwaj S, Yadava U, et al. Evaluation of caffeine as inhibitor against collagenase, elastase and tyrosinase using in silico and in vitro approach. *J Enzyme Inhib Med Chem* 2019; 34: 927–936.
- Hossain MR, Ansary TM, Komine M, et al. Diversified stimuli-induced inflammatory pathways cause skin pigmentation. *Int J Mol Sci*; 22. Epub ahead of print 2021. DOI: 10.3390/ijms22083970.
- Husen SA, Syadzha MF, Setyawan MF, et al. Evaluation of the combination of *sargassum duplicatum*, *sargassum ilicifolium*, *abelmoschus esculentus*, and *garcinia mangostana* extracts for open wound healing in diabetic mice. *Syst Rev Pharm* 2020; 11: 888–892.
- Fu C, Chen J, Lu J, et al. Roles of inflammation factors in melanogenesis (Review). *Mol Med Rep* 2020; 21: 1421–1430

**Exploring Melanin Expression through Immunohistochemistry in
Skin Graft after Robusta coffee BP-42 extract Gel Administration: A
Novel Approach to Understanding Pigmentation and Regeneration''**

Ulfa Elfiah

Fakultas Kedokteran Universitas Jember

2023

INTRODUCTION

- One of the best methods to cure wounds is the skin graft, although it has drawbacks like hyperpigmentation.

- Hyperpigmentation occurs due to :
 - 1.the DOPA reaction and melatonin enzymes such as Tyrosinase, Tyrosinase-Related Protein (TYRP1), and DOPA-chrome Tautomerase (TYRP2)
 2. The overexpression of these enzymes can last for four weeks after the skin graft.
 3. The contraction process of the skin graft causes melanin accumulation and aggravates the degree of pigmentation.
 - 4.Melanosomes in the skin grafted become more prominent, more pigmented, and resistant to lysosomes, leading to more severe pigmentation

INTRODUCTION

- Numerous medical interventions have been identified to address the concern of hyperpigmentation like hydroquinone and kojic acid
- Nevertheless, hydroquinone and kojic Acid has the potential to cause localized skin irritation, itching, redness
- Hydroquinone is leading to a phenomenon known as post inflammatory hyperpigmentation, which could worsen the overall skin pigmentation condition

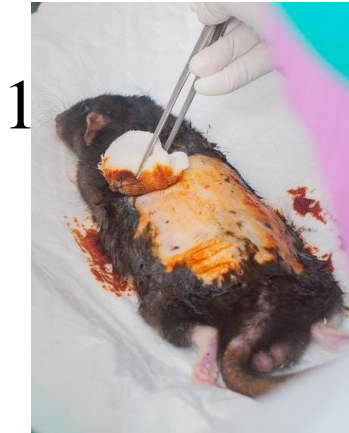
INTRODUCTION

- Our previous study showed that Robusta BP-42 has the excellent potential of an anti-tyrosinase agent.
- Anti-tyrosinase agent included chlorogenic acid, caffeine, trigonelline, palmitic acid, and hydroquinones to improve anti-tyrosinase activity

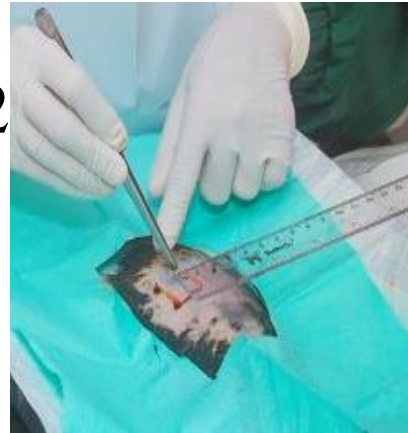

This study examines the efficacy of kojic acid and Robusta BP-42 coffee bean extract in reducing skin hyperpigmentation in rats with skin grafts

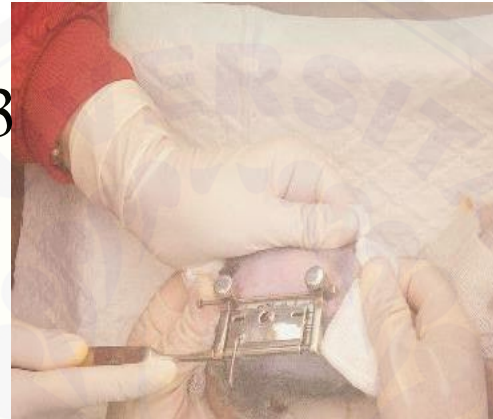Material and Method



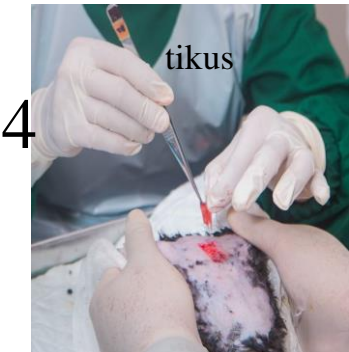1 Desinfeksi punggung



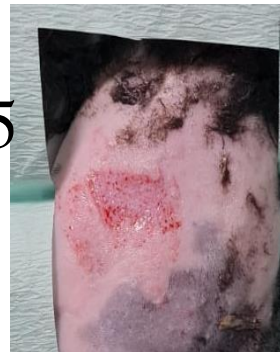2 Membuat ukuran graft



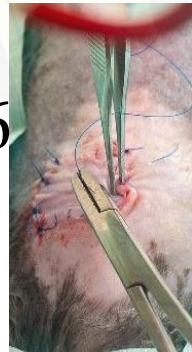3 Pengambilan graft dengan



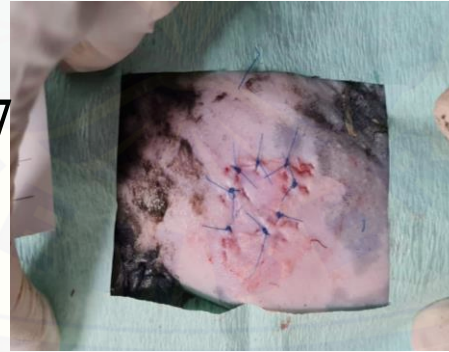
4 Graft yang didapat



5 Luka donor



6 Penjahitan graft pada donor asal



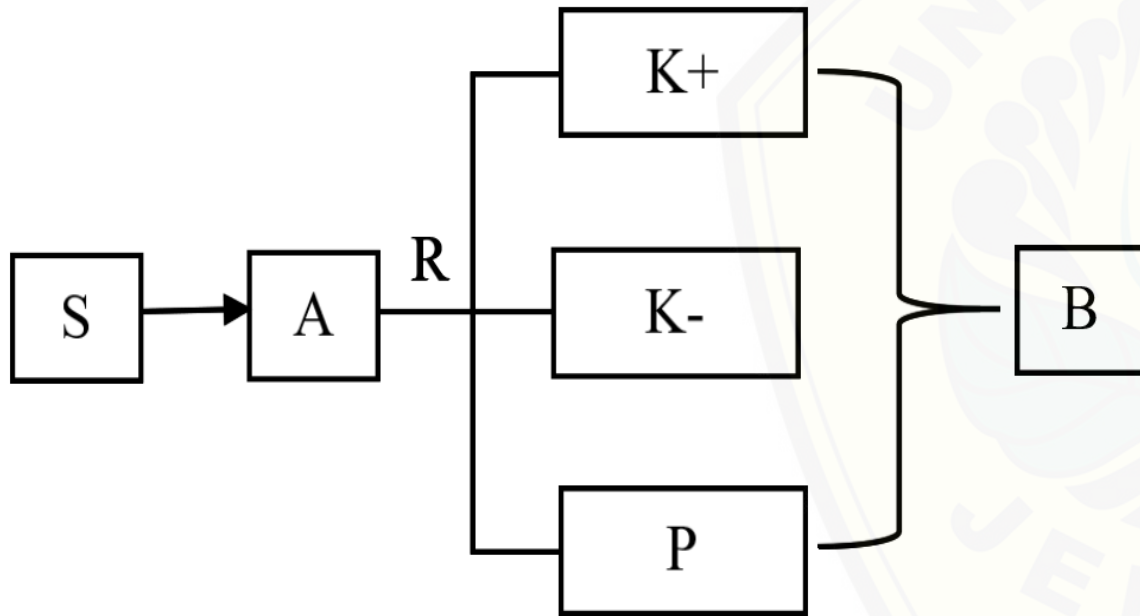
7 Skin graft pada luka donor siap mendapatkan perlakuan



true experimental laboratories with post test only control group design.

Digital Repository Universitas Jember

Material and Method



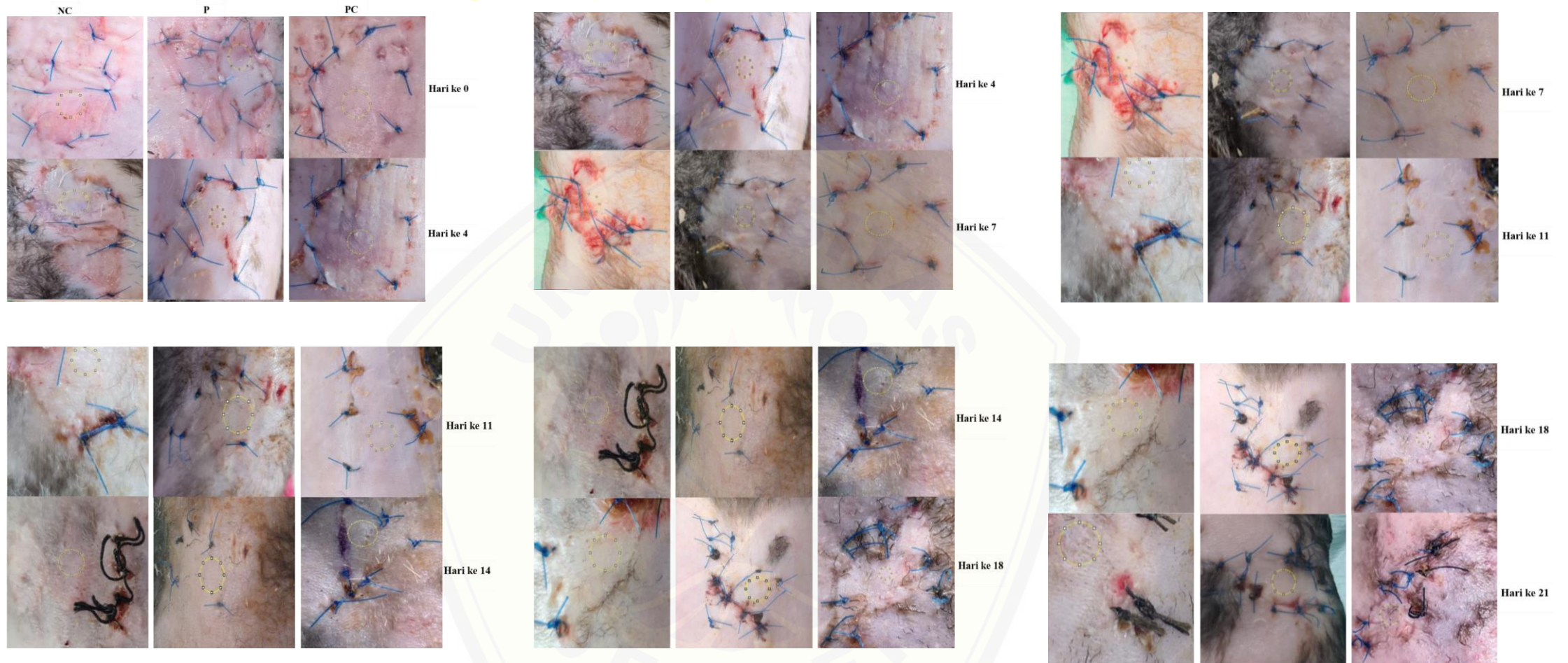
The experiment involved three groups of long Evans Rats with grafted skin: one group was treated with:

1. a 2% kojic acid gel (positive control),
2. a 5% robusta BP-42 coffee extract gel,
3. the third with a placebo gel (negative control).

Material and Method

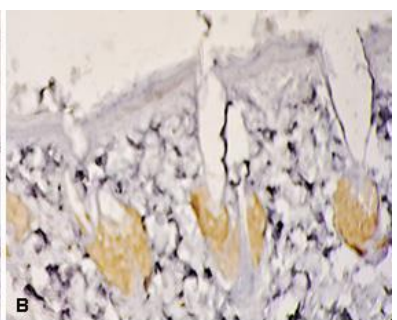

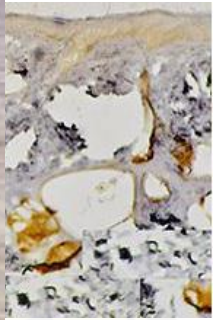

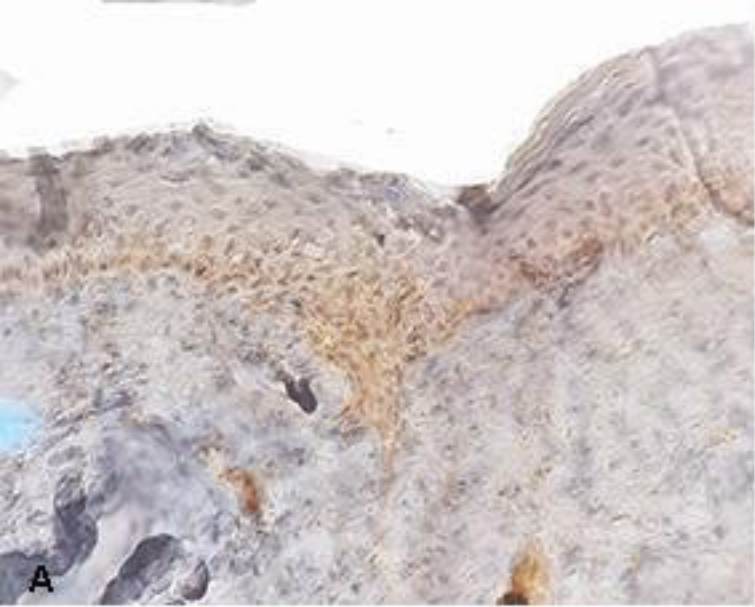
- The grafted skin was observed and photographed on days 0, 4, 7, 11, 18, and 21, with skin pigmentation measurements conducted using Image J software
- Histological analysis was performed on days 7, 14, and 21 for all treatment groups. These preparations were stained immunohistochemically with anti-tyrosinase antibody (T311).

RESULT

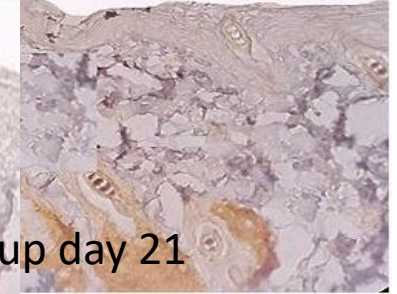

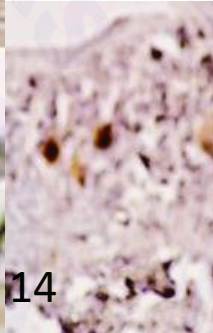
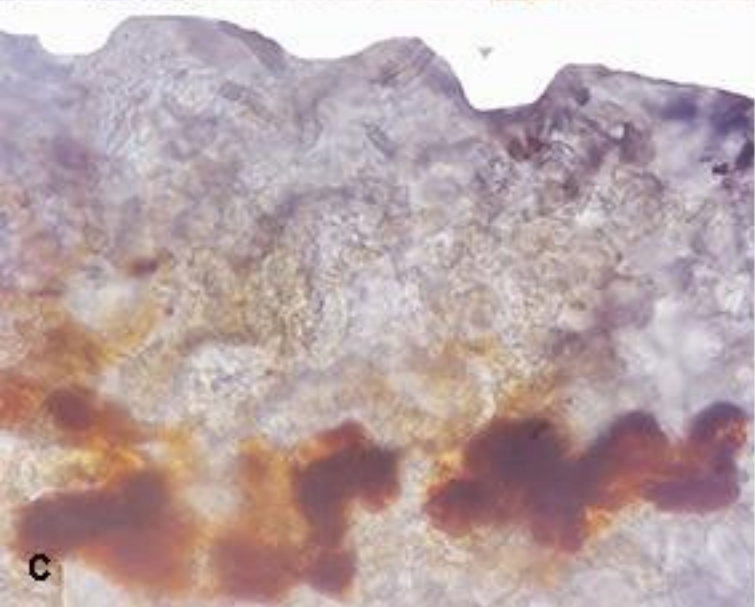


.Analysis color intensity observations based on Image J and two-way repeated measures ANOVA method:
-the comparission between negative control group , positive and treatment group was a significant difference ($p < 0.05$)
-the comparission between positive control group and treatment group was no a significant difference ($p > 0.05$)

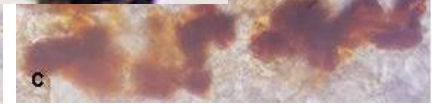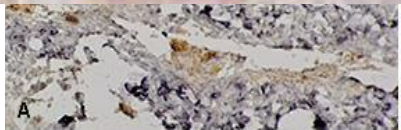
chemical examination



Control day 21

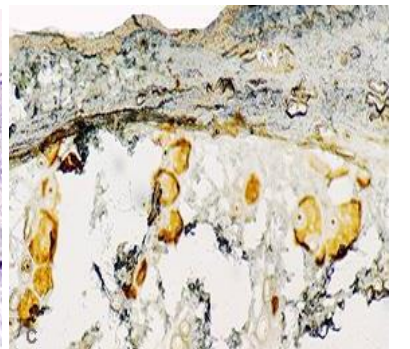
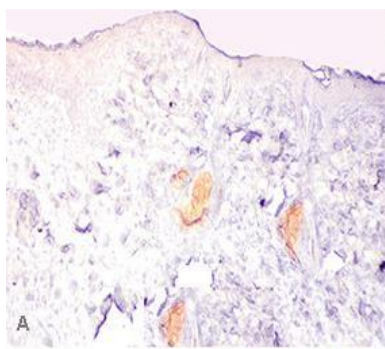


Treatment group day 21



positive group day 7

positive group day 14



positive day 21

The results of the immunohistochemical examination

- The negative control group showed the presence of melanocyte cell anti-tyrosinase antibody expression that was immunopositive on days 7, 14, and 21
- Meanwhile, the positive control and treatment groups showed the same results, decreasing melanocyte cell anti-tyrosinase antibody expression from immunopositive to immunonegative starting on day 14

Discussion

The results show that robusta coffee extract BP-42 has an excellent clinical appearance and is similar to kojic acid as a positive control

Robusta coffee BP-42 has similar effectiveness to kojic acid because it has a variety of active compounds that support tyrosinase inhibition : hydroquinone, free fatty acid, trigonelline, chlorogenic acid and caffeine.

Chlorogenic acid could inhibit melanogenesis by binding to the active side of the tyrosinase enzyme.

Discussion

- In silico research shows that the mechanism of tyrosinase inhibition by caffeine occurs due to the formation of a stable protein-ligand complex called the enzyme-caffeine complex.
- The presence of this complex causes inhibition of enzymatic reactions so that the melanogenesis process cannot enter the next stage.
- The presence of hydroquinone in Robusta coffee extract BP 42 strengthens the reason that it can be used as a natural depigmentation agent

Discussion

- Trigonelline is an appropriate compound for reducing inflammation due to the activity of hydroquinone.
- The decrease in the inflammatory process will reduce the stimulation of the mechanism of pigmentation formation after wound healing.

Conclusion

- Robusta BP-42 coffee extract from the Jember district has bioactive compounds related to skin graft pigmentation and is proven to have an antityrosinase effect.
- It results in pigmentation changes in clinical appearance and histologically in skin graft wounds
- So robusta coffee extract gel can be an alternative to prevent the process of increasing pigmentation after skin grafting.

Thank You





CERTIFICATE

Of Attendance

dr. Ulfa Elfiah, M. Kes., Sp.BP-RE., Subsp.L.B.L(K)

as

PARTICIPANT

The 26th Annual Scientific Meeting of the Indonesian Association of
Plastic Reconstructive and Aesthetic Surgeons (InaPRAS)

Boosting Scientific Works Through Collaborative Spirit

23rd - 25th August, 2023

Four Points Hotel, Manado
Aryaduta Hotel, Manado

Dr. dr. Mendy Hatibie Oley, SpBP-RE(K)
Chairperson of 26th InaPRAS

dr. Najatullah, SpBP-RE(K), MARS
President of InaPRAS



26th InaPRAS

CERTIFICATE

Of Attendance

dr. Ulfa Elfiah, M. Kes., Sp.BP-RE., Subsp.L.B.L(K)

as

PARTICIPANT

WORKSHOP

MASTER COURSE ON FACIAL FAT GRAFTING

The 26th Annual Scientific Meeting of the Indonesian Association of
Plastic Reconstructive and Aesthetic Surgeons (InaPRAS)

23rd August, 2023

Four Points Hotel, Manado

Dr. dr. Mendy Hatibie Oley, SpBP-RE(K)

Chairperson of 26th InaPRAS

dr. Najatullah, SpBP-RE(K), MARS

President of InaPRAS