

MAKALAH ILMIAH

Post Burn Contracture in Pediatric Patient: Surgical Management and Its challenges

dr. Ulfa Elfiah, M.Kes., Sp.BP-RE., Subsp.L.B.L.(K)
NIP.197607192001122001

- Tenaga Pengajar
Fakultas Kedokteran Universitas Jember

KEMENTERIAN PENDIDIKAN, KEBUDAYAAN, RISET DAN
TEKNOLOGI UNIVERSITAS JEMBER



Makalah Ilmiah disampaikan pada:
ASIA PACIFIC BURN ASSOCIATION

www.apburn.org

16 Maret 2023

*A REGIONAL CO-OPERATION TO
IMPROVE BURN CARE SCIENTIFICALLY*



ASIA PACIFIC BURN ASSOCIATION

www.apburn.org

A REGIONAL CO-OPERATION TO IMPROVE
BURN CARE SCIENTIFICALLY

PEDIATRIC BURNS

 [Click Here To Register](#)

16th March, 2023

1:30 PM (IST)

8:00 AM (GMT)

BROUGHT TO YOU BY



Prof Gaoxing LUO

President, APBA
Professor & Director
Institute of Burn Research,
Southwest Hospital,
Chongqing, China



Dr Rajeev B Ahuja

Executive Director &
Founder President, APBA
Senior Consultant & Plastic Surgeon,
Sir Ganga Ram Hospital, New Delhi



Prof Vinita Puri

President Elect &
Honorary Secretary, APBA
Head, Department of Plastic Surgery,
Seth G S Medical College &
KEM Hospital, Mumbai, India



Dr Nyoman Putu Riasa

Honorary Treasurer, APBA
Past President, APBA
Senior Consultant Plastic Surgeon,
Prof. Dr. I.G.N.G. Ngoerah Hospital,
Indonesia

HOST



Prof Vinita Puri

President Elect &
Honorary Secretary, APBA
Head, Department of Plastic Surgery,
Seth G S Medical College &
KEM Hospital, Mumbai, India



Dr. Yvonne Wilson

UK



Dr Nyoman Putu Riasa

Honorary Treasurer, APBA
Past President, APBA
Senior Consultant Plastic Surgeon,
Prof. Dr. I.G.N.G. Ngoerah Hospital,
Indonesia

SPEAKERS



Prof Ramesh Sharma

Director, Department of Plastic
Surgery, Paras Hospital, Panchkula,
Haryana, India



Dr. Yvonne Wilson

UK



Dr. Wen-Teng Yao

Chief of Burn Centre, MacKay
Memorial Hospital, Taipei,
Taiwan



Dr Nyoman Putu Riasa

Honorary Treasurer, APBA
Past President, APBA
Senior Consultant Plastic Surgeon,
Prof. Dr. I.G.N.G. Ngoerah Hospital,
Indonesia



Dr. Nikki Allorto

Specialist Surgeon Pietermaritzburg
Metropolitan Burn Service
University of KwaZulu Natal,
South Africa



Dr Ulfa Elfiah

Division of Plastic Surgery & Burn,
Dr Soebandi Hospital /Jember
University, East Java, Indonesia



Dr Ivette Icaza

Advisor, Sunshine Social
Welfare Foundation (SSWF),
Taiwan

ACADEMIC PROGRAM

Duration : 2 Hours

Introduction to Program Vinita Puri	02 Min.
Opening Remarks Gaoxing Luo, Rajeev B Ahuja	02 Min.
Fluid Resuscitation & Electrolyte Therapy for Pediatric Burn Ramesh Sharma	15 Min.
Management of Burn Edema in Pediatric Burn Yvonne Wilson	15 Min.
Hypermetabolism in Pediatric Burn: Pathophysiology & Management Wen-Teng Yao	15 Min.
Pediatric Burn Wound: Dressing Choices & Surgical Burn Wound Management Nyoman Putu Riasa	15 Min.
Sepsis in Pediatric Burn: Prevention, Diagnosis & Antibiotic Therapy Nikki Allorto	15 Min.
Post Burn Contracture in Pediatric Patient: Surgical Management & its Challenges Ulfa Elfiah	15 Min.
Rehabilitation & Therapy in Pediatric Burn Ivette Icaza	15 Min.
Q & A and Panel Discussion Moderators: Yvonne Wilson, Nyoman Putu Riasa	10 Min.
Concluding Remarks Vinita Puri	01 Min.

Introduction

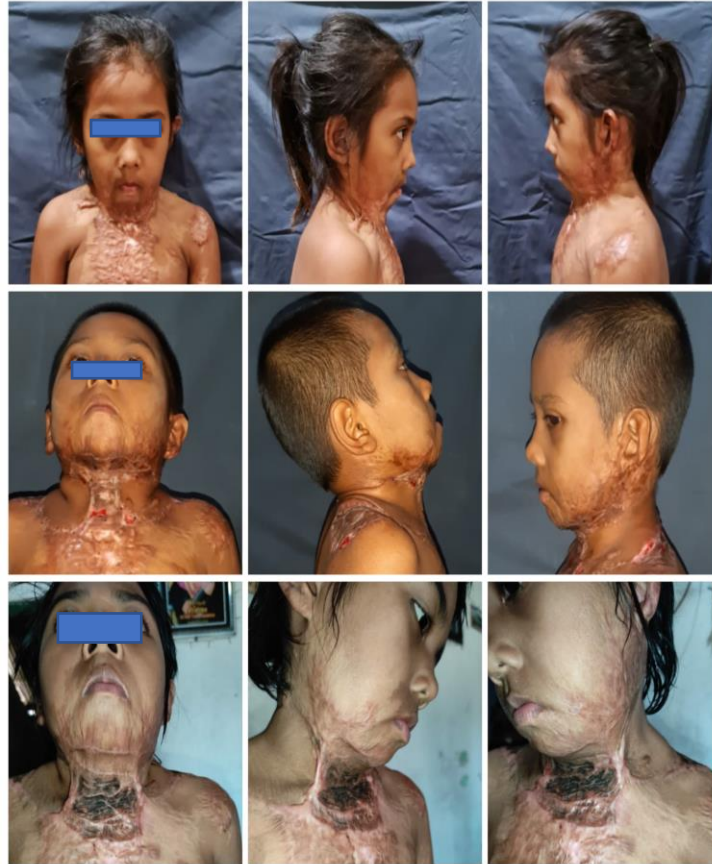- Post-burn contracture is a common complication in pediatric patients who have suffered from burn injuries. It occurs when scar tissue forms and tightens around joints, restricting movement and causing deformities. The prevalence of burn contractures in the pediatric population has previously been reported at 23%. Predictors of the number of contractures included total age, length of stay, length of ICU stay, presence of amputation, TBSA burned, and TBSA grafted.
- However, the management of post-burn contracture in pediatric patients presents several challenges. Firstly, pediatric patients have delicate skin and soft tissue structures, which require careful handling during surgery. Secondly, there is a risk of recurrent contracture, particularly if the underlying cause of the contracture is not properly addressed. Thirdly, children may require multiple surgeries over time as they grow and their bodies change.

Case Presentation 1

A ten-year-old girl with severe post-burn neck contracture with scarring of the anterior neck and anterior chest wall. The cervicomenal angle is extremely narrow, no neck movements and bowed down head found. The contracture is released and covered with a bilateral occipito shoulder flap. Why we use the bilateral occipito shoulder flap, the purpose is to maximize the range of movement and decrease rigidity, because we think that this is the best procedure to achieve those purposes. A split-thickness skin graft is applied to the submental defect, donor site, and the anterior chest wall.

The challenging airway management in this patient is the main intraoperative problem, because of the extreme neck rigidity. Orotracheal intubation required a fiberoptic laryngoscope as the gold standard. The postoperative difficulty is the patient's refusal to participate in routine care due to pain, fear, and discomfort.

Further challenge six months later. We can see from the pictures that the scar reappears and occurs on the anterior part of the neck, resulting in not optimal movement. In this picture we can see where the scar is occurring around the neck area and cause the patient to have an inability to move her neck and form a bad posture. The parents decide to stop the procedures because they think that this has been enough and better than before.



Case Presentation 2

A five-year-old child had a history of burns due to contact with hot water. Six months later, both of patient's legs and toes cannot be straightened, and the movement is limited. The contracture release was carried out in 2 stages and covered with skin graft. The total treatment procedures take one and half month, that resulting on improvement of the Range of motion on both legs. What is the challenge in this case? Scars around joints were extensive and thick, few donors were available, and the bleeding had to be tightly controlled during the intraoperative period. Patients and their parents had to deal with postoperative difficulties. Children frequently scream because they are in pain, afraid, or uncomfortable condition. Actually for this patient, should be referred to the rehabilitation center twice a week for a better result. But, The parent refuses to cooperate, because they feel bad to witness their child screaming and in pain as a result of the wound care and physical therapy procedures

Discussion

In Pediatric, Post burn contracture can have a significant impact on their physical and emotional development. Surgical management is often necessary to address post-burn contracture in pediatric patients.

The management procedures are actually varied, but we must consider for the appropriate treatment regarding to the severity of the contracture. On Post burn contracture of the neck, flap procedure shows more benefit instead of skin graft. In the case where the skin graft must be perform then we should consider for the nonvisible area of the neck (e.g. Submental area)

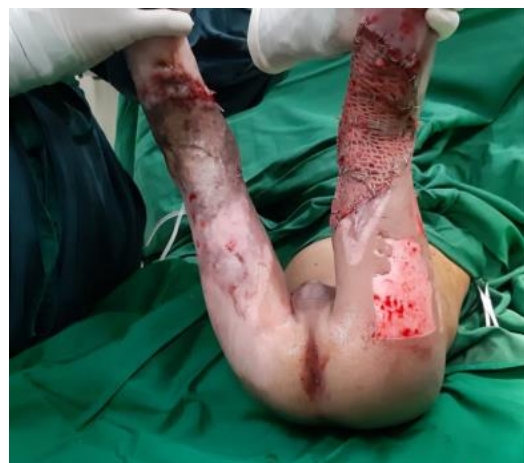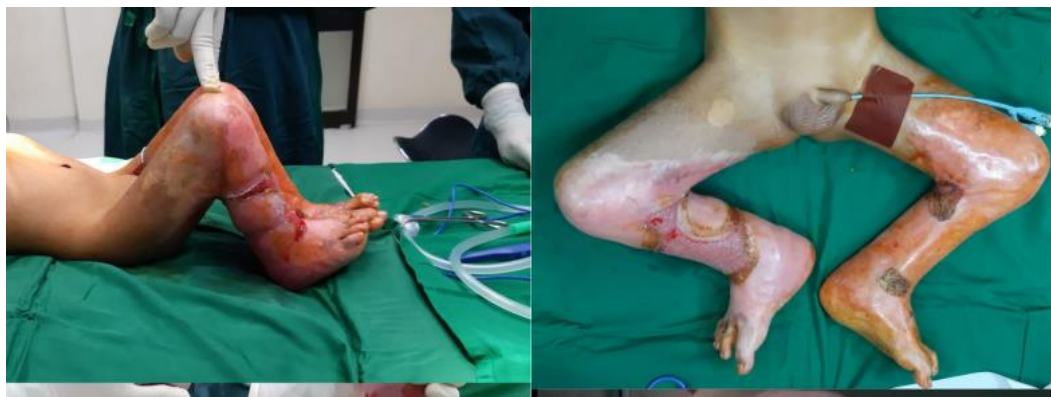In the post burn contraction of knee joint is better to perform flap procedure for the management, regarding to the study of which shows that medial and lateral flap in comparison to split skin grafting gave a better outcome in severe post burn contractive of knee joint.

But in some case skin graft could be the choice for the management . like in the case where the amount of skin donor is not enough for the flap procedure, beside that skin graft also more simple and easier to perform.

However, there are several challenges associated with this approach i.e:

- First, the timing of surgery is critical
- Second, the need for repeated surgeries, and scar management. This can be emotionally and physically taxing for both the child and their caregivers.
- lastly, Rehabilitation and physical therapy are also critical to achieve optimal outcomes.

Another challenge is managing pain and discomfort in pediatric patients during and after surgery. Children may experience anxiety, fear, and discomfort during surgical procedures, which can be mitigated through proper anesthesia and proper pain management techniques



Conclusion

- post-burn contracture in pediatric patients can be challenging to manage surgically due to various factors, including the child's growth, anxiety, and the risk of contracture recurrence.
- A multidisciplinary approach involving the team of specialists is critical for the success of surgical interventions

Thank you for taking the time to listen to my presentation. I hope that the information I shared will be useful for you. It's my pleasure to present this to you today and I appreciate the opportunity for share my knowledge with you

Refferences

- Jerome T, Sabtharishi V, SK T (January 25, 2021) Supraclavicular Flap for Severe Post-burn Neck Contracture in Children. *Cureus* 13(1): e12910. doi:10.7759/cureus.12910
- Poresh Boruah. Reconstruction of Post Burn Contracture Knee: Evaluation of Outcome of Releasing Procedures", *International Journal of Science & Engineering Development Research* (www.ijedr.org), ISSN:2455-2631, Vol.5, Issue 9, page no.127 - 134, September-2020, Available :<http://www.ijedr.org/papers/IJEDR2009019.pdf>
- Sharma, A., & Sharma, M. K. (2021). Post Burn Contracture Neck- An Anaesthetic Challenge. *Asian Journal of Medical Research*, 10(4), 9-12. Retrieved from <https://ajournals.com/index.php/ajmr/article/view/2090>
- Yelvington M, Godleski M, Lee AF, Goverman J, Parry I, Herndon DN, Suman OE, Kowalske K, Holavanahalli R, Gibran NS, Esselman PC, Ryan CM, Schneider JC. Contracture Severity at Hospital Discharge in Children: A Burn Model System Database Study. *J Burn Care Res*. 2021 May 7;42(3):425-433. doi: 10.1093/jbcr/iraa169. PMID: 33247583; PMCID: PMC8344380.



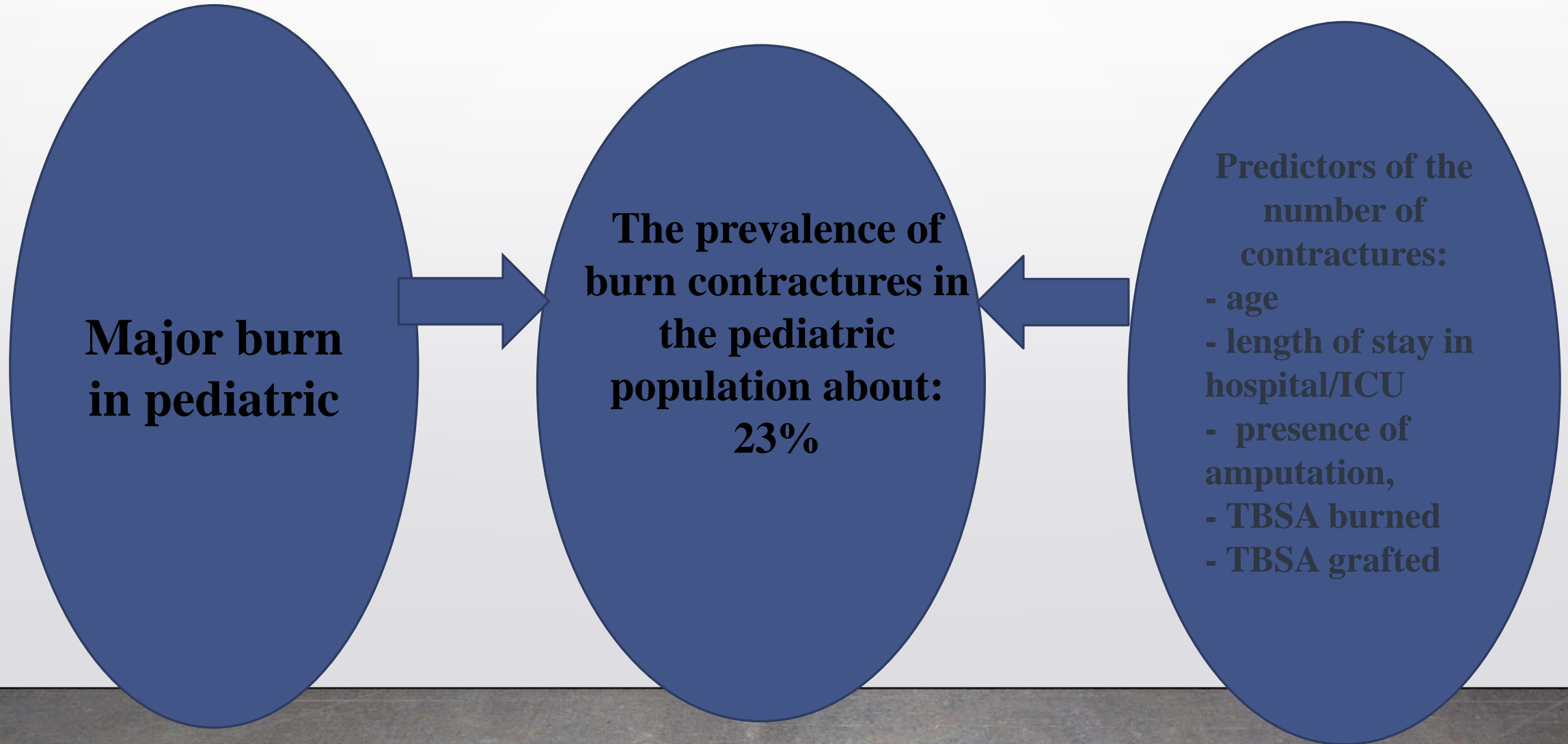Post Burn Contracture in Pediatric Patient: Surgical Management and Its challenges

Ulfa Elfiah

Faculty of Medicine, University of Jember, Indonesia

2023

Introduction



The management of post-burn contracture in pediatric patients presents several challenges



1. Pediatric patients have delicate skin and soft tissue structures, which require careful handling during surgery.

2. There is a risk of recurrent contracture, particularly if the underlying cause of the contracture is not addressed.

3. Children may require multiple surgeries over time as they grow and their bodies change.



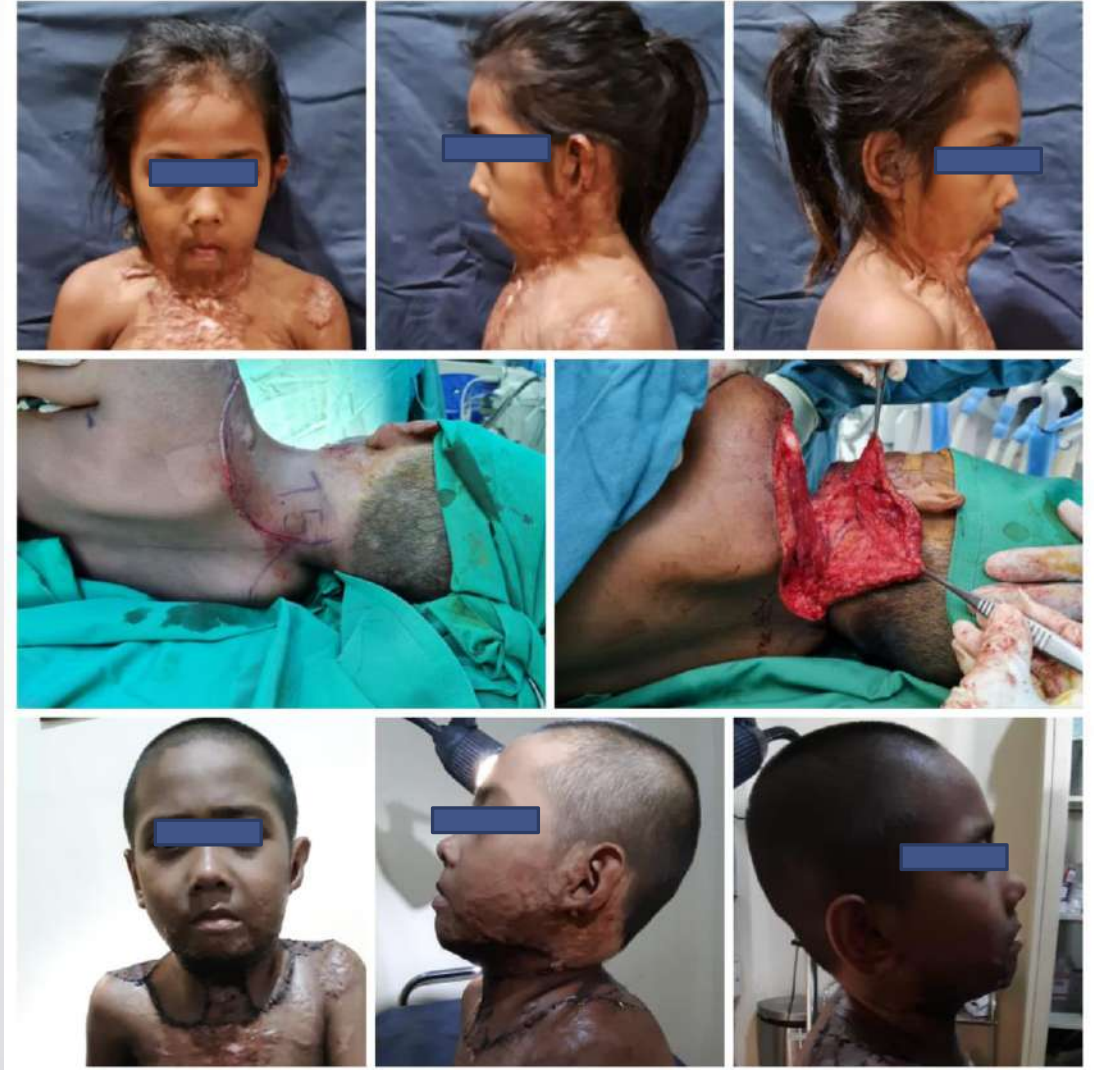Case Presentation

A ten-year-old girl with severe post-burn neck contracture with scarring of the anterior neck and anterior chest wall.

The cervicomental angle is extremely narrow , no neck movements and Bowed down head.

The contracture is released and covered with bilateral a occipito shoulder flap.

A split-thickness skin graft is applied to the submental defect, donor site, and the anterior chest wall.

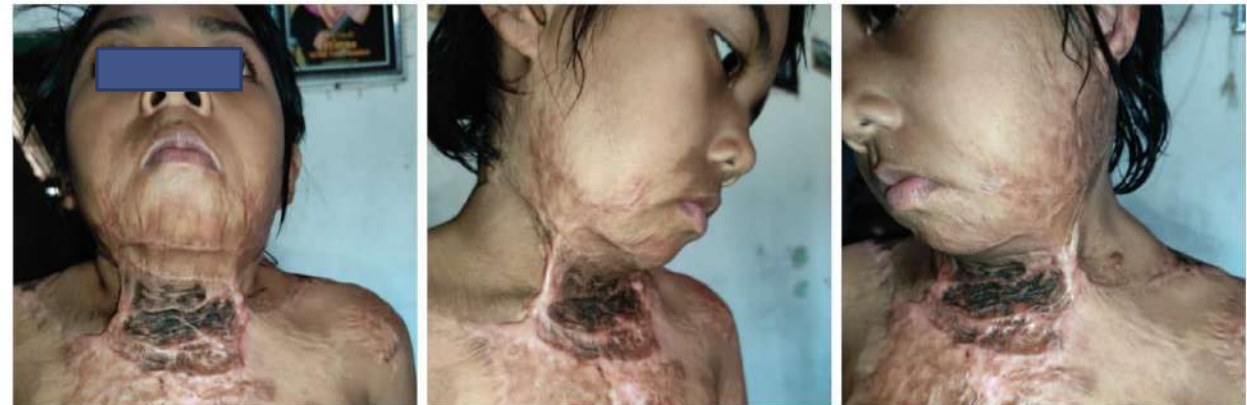
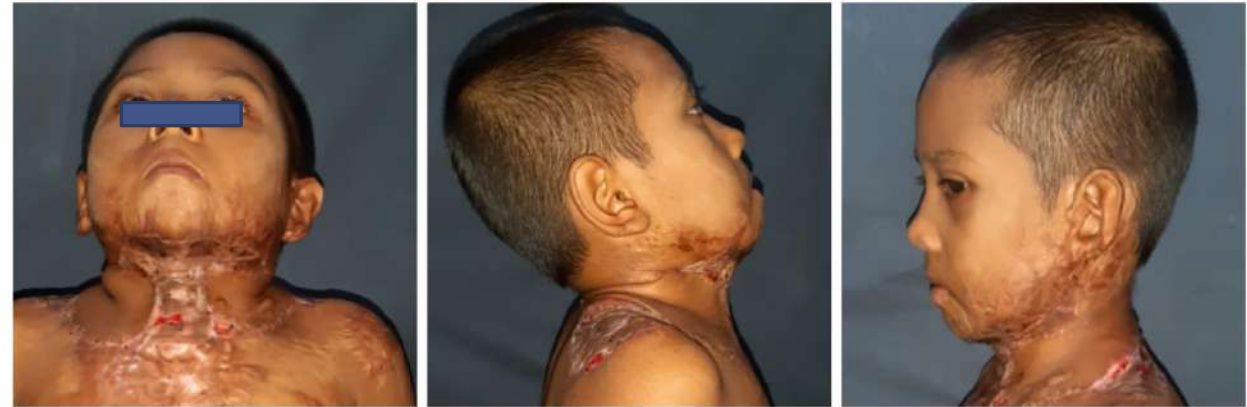
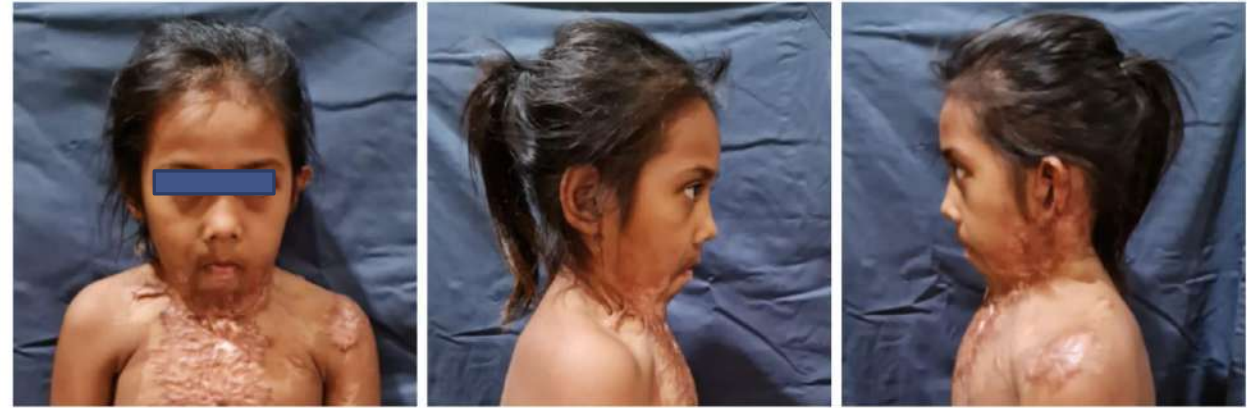One week after operation

The challenging airway management in this patient is the main intraoperative problem.

The postoperative difficulty is the patient's refusal to participate in routine care due to pain, fear, and discomfort.

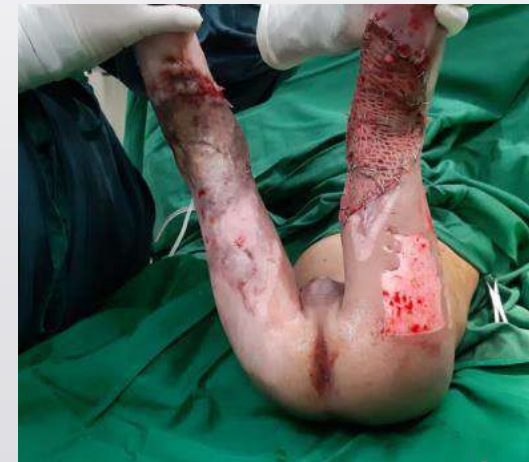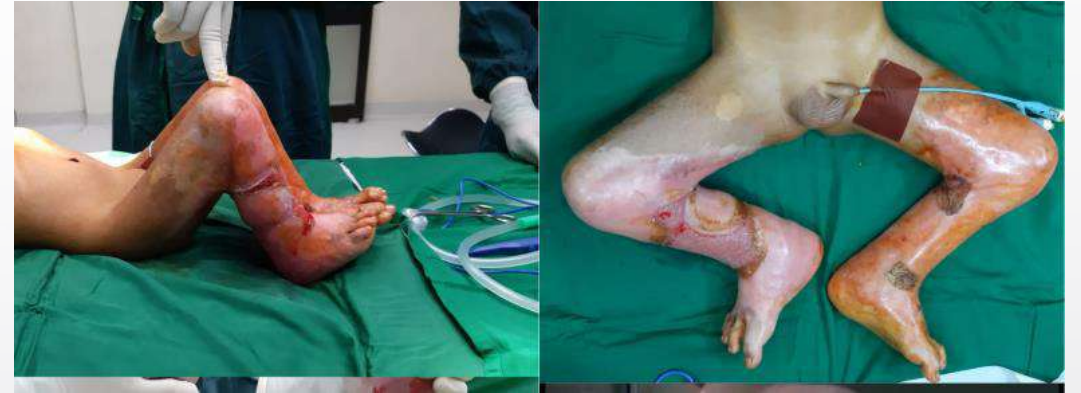Further challenges the scar reappears, so that movement function is not optimal



A five-year-old child had a history of burns due to contact with hot water

Six months later, the patient's right and left legs and toes cannot be straightened, and the movement is limited

The contracture release was carried out in 2 stages and covered with skin graft.



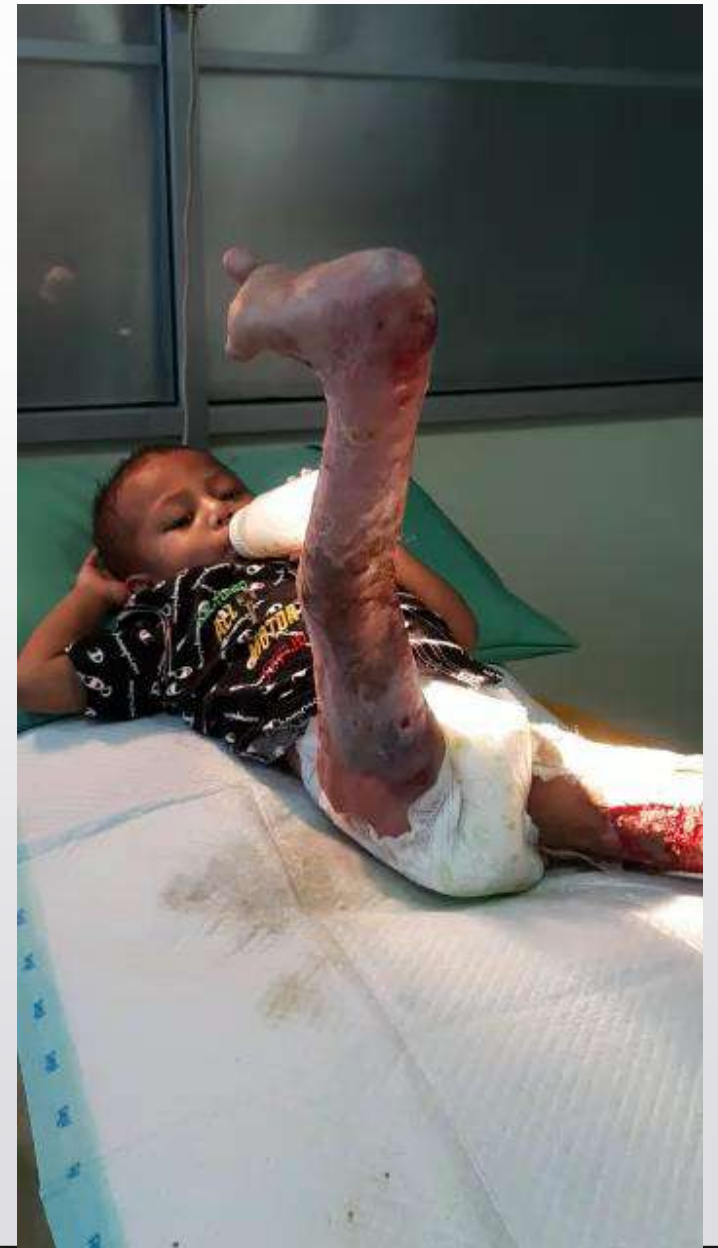Challenge ?

Scars around joints were extensive and thick, few donors were available, and the bleeding had to be tightly controlled during the intraoperative period

Patients and their parents had to deal with postoperative difficulties.

Children frequently scream because they are in pain, afraid, or uncomfortable.

a parent refuses to cooperate, they must witness their child screaming and in pain as a result of the wound care and physical therapy procedures





DISCUSSION

- **In Pediatric, Post burn contracture can have a significant impact on their physical and emotional development**
- **Surgical management is often necessary to address post-burn contracture in pediatric patients. However, there are several challenges associated with this approach i.e:**
 - **Firstly, the timing of surgery is critical**
 - **Secondly, the need for repeated surgeries, and scar management. This can be emotionally and physically taxing for both the child and their caregivers.**
 - **Finally, Rehabilitation and physical therapy are also critical to achieve optimal outcomes.**



DISCUSSION

- **Another challenge is managing pain and discomfort in pediatric patients during and after surgery.**
- **Children may experience anxiety, fear, and discomfort during surgical procedures, which can be mitigated through proper anesthesia and pain management techniques**



CONCLUSION

- **post-burn contracture in pediatric patients can be challenging to manage surgically due to various factors, including the child's growth, anxiety, and the risk of contracture recurrence.**
- **A multidisciplinary approach involving a team of specialists is critical for the success of surgical interventions**




REFRENCES

- Jerome T, Sabtharishi V, SK T (January 25, 2021) Supraclavicular Flap for Severe Post-burn Neck Contracture in Children. *Cureus* 13(1): e12910. doi:10.7759/cureus.12910
- Poresh Boruah. Reconstruction of Post Burn Contracture Knee: Evaluation of Outcome of Releasing Procedures", *International Journal of Science & Engineering Development Research* (www.ijsdr.org), ISSN:2455-2631, Vol.5, Issue 9, page no.127 - 134, September-2020, Available :<http://www.ijsdr.org/papers/IJSDR2009019.pdf>
- Sharma, A., & Sharma, M. K. (2021). Post Burn Contracture Neck- An Anaesthetic Challenge. *Asian Journal of Medical Research*, 10(4), 9-12. Retrieved from <https://ajjournals.com/index.php/ajmr/article/view/2090>
- Yelvington M, Godleski M, Lee AF, Goverman J, Parry I, Herndon DN, Suman OE, Kowalske K, Holavanahalli R, Gibran NS, Esselman PC, Ryan CM, Schneider JC. Contracture Severity at Hospital Discharge in Children: A Burn Model System Database Study. *J Burn Care Res.* 2021 May 7;42(3):425-433. doi: 10.1093/jbcr/iraa169. PMID: 33247583; PMCID: PMC8344380.



THANK YOU



- Search
- All Mailboxes
- Favorites
- Smart Mailboxes
- Di Mac Saya
- Trash
- Recovered Messag...
- elfiah2018@gmail.com
 - Penting 2
 - Inbox 9
 - Drafts 1
 - Sent
 - Junk
 - Trash
 - Archive 9
- iCloud
- Yahoo!
 - Inbox 131
 - Drafts 109
 - Sent 2
 - Junk 20
 - Trash 8
 - Archive 22
 - Boxbe Waitin... 182
 - ARTIKEL 5
 - BEIJING
 - bioetik
 - BLU 4
 - campuran 10

Zoom Inbox - Yahoo! 16/03/23
APBA Webinar Confirmation
Hello Ulfa Elfiah, Thank you for registering for APBA Webinar. You...

Shivam Verma Inbox... 16/03/23
Virtual Background & Faculty J...
Dear Esteemed Faculty, Please find the below Faculty Joining Link for y...

Shivam Verma Inbox... 15/03/23
Faculty Joining Link - APBA Webi...
Dear Esteemed Faculty, Please find the below Faculty Joining Link for y...

Shivam, Asia... Inb... 15/03/23
Faculty Joining Link - APBA...
Ma'am its already 2:30PM in the link In case of any query please let me...

Asia Pacific B... Inb... 15/03/23
Upcoming APBA Symposi...
Dear Dr. Ulfa, We continue to await your presentation. I would apprecia...

ABIS Secretary Inbo... 15/03/23
Welcome to Attend the 14th Asian...
Dear Participants of Asia Pacific Burn Congress (APBC) 2019, We...

drsharmark@... Inb... 19/02/23
APBA Symposium on 16th Ma...
Thanks for your email The recording will be mailed as desired Regards...

riasanyoman... Inb... 12/03/22
Free Webinars are back:...
Sent from my iPhone Begin forwarded message: From: Nyoman...

Asia Pacific B... Inb... 19/03/21
APBA Symposium Certificate o...
Thank you for your interest in the APBA symposium which was condu...

Asia Pacific B... Inb... 10/03/21
Link for APBA Symposium on 11th...
Thank you for registering for the APBA symposium on Controversies...

Asia Pacific B... Inb... 03/03/21
APBA Symposium March 2021...



Asia Pacific Burn Association
Re: Upcoming APBA Symposium on 16th March, 2.30 PM IST
To: Ulfa Elfiah, Cc: Rajeev Ahuja & 2 more

14 March 2023 14.00

[Details](#)

Dear Dr Ulfa Elfiah,
I hope all is well
We await your presentation for Thursday's APBA Symposium.
Kind regards,
Vinita Puri

Prof. Vinita Puri
Head, Department of Plastic Surgery and Burns,
Seth G S Medical College and KEM Hospital, Mumbai. India

President Elect and Honorary Secretary, APBA (Asia Pacific Burn Association)
www.apburn.org

Past President - National Academy of Burns, India
www.thenabi.org

[See More from Asia Pacific Burn Association](#)



Asia Pacific Burn Association
Re: Upcoming APBA Symposium on 16th March, 2.30 PM IST
To: Ulfa Elfiah, Cc: Rajeev Ahuja & 2 more

15 March 2023 17.22

[Details](#)

Dear Dr. Ulfa,
We continue to await your presentation. I would appreciate it if you could reply to the email as it would assure us that you would send the presentation, attend the meeting and be there to take the questions.
Kindly email to me and to Shivam. If you are sending by drive please make sure that you enable permissions for both these email addresses
Shivam@conferencesinternational.in and secretaryapba@gmail.com

Thanks

Prof. Vinita Puri
Head, Department of Plastic Surgery and Burns,
Seth G S Medical College and KEM Hospital, Mumbai. India

President Elect and Honorary Secretary, APBA (Asia Pacific Burn Association)
www.apburn.org

Past President - National Academy of Burns, India
www.thenabi.org

[See More from Asia Pacific Burn Association](#)

Searching "Inbox - Y..."

Found 20 results



Move to...

APBA

Search

All Mailboxes

Favorites

Smart Mailboxes

Di Mac Saya

Trash

Recovered Messag...

elfiah2018@gmail.com

Penting 2

Inbox 9

Drafts 1

Sent

Junk

Trash

Archive 9

iCloud

Yahoo!

Inbox 131

Drafts 109

Sent 2

Junk 20

Trash 8

Archive 22

-Boxbe Waitin... 182

ARTIKEL 5

BEIJING

Zoom Inbox - Yahoo! 16/03/23
APBA Webinar Confirmation
Hello Ulfa Elfiah, Thank you for registering for APBA Webinar. You...

Shivam Verma Inbox... 16/03/23
Virtual Background & Faculty J...
Dear Esteemed Faculty, Please find the below Faculty Joining Link for y...

Shivam Verma Inbox... 15/03/23
Faculty Joining Link - APBA Webi...
Dear Esteemed Faculty, Please find the below Faculty Joining Link for y...

Shivam, Asia... Inb... 15/03/23
Faculty Joining Link - APBA... 5
Ma'am its already 2:30PM in the link
In case of any query please let me...

Asia Pacific B... Inb... 15/03/23
Upcoming APBA Symposi... 4
Dear Dr. Ulfa, We continue to await your presentation. I would apprecia...

ABIS Secretary Inbo... 15/03/23
Welcome to Attend the 14th Asian...
Dear Participants of Asia Pacific Burn Congress (APBC) 2019, We...

drsharmark@... Inb... 19/02/23
APBA Symposium on 16th Ma... 2
Thanks for your email The recording will be mailed as desired Regards...

riasanyoman... Inb... 12/03/22
Free Webinars are back:... 2
Sent from my iPhone Begin forwarded message: From: Nyoman...

Asia Pacific B... Inb... 19/03/21
APBA Symposium Certificate o...
Thank you for your interest in the APBA symposium which was condu...

Asia Pacific B... Inb... 10/03/21
Link for APBA Symposium on 11th...

Zoom
APBA Webinar Confirmation
To: Ulfa Elfiah,
Reply-To: sumeet@conferencesinternational.in

Inbox - Yahoo! 16 March 2023 15.48



Hello Ulfa Elfiah,

Thank you for registering for APBA Webinar. You can find information about this meeting below.

APBA Webinar

Date & Time Mar 16, 2023 02:30 PM India

Meeting ID 828 2349 4814

Passcode 214221

[Add to Calendar\(.ics\)](#) | [Add to Google Calendar](#) | [Add to Yahoo Calendar](#)

You can cancel your registration at any time.

Please submit any questions to: sumeet@conferencesinternational.in.

WAYS TO JOIN ZOOM



Copyright ©2023 Zoom Video Communications, Inc. All rights reserved.

