

DENTA JURNAL

KEDOKTERAN GIGI



P-ISSN: 1907-5987

E-ISSN: 2615-1790

VOLUME 14 NO.2 AGUSTUS 2020



SUSUNAN REDAKSI

Editor in Chief

Widyasri Prananingrum

Executive Editor

Noengki Prameswari

Duty Editor

Agni Febrina Pargaputri, Dian Damaiyanti, Fitria Rahmitasari,
Widyastuti, Arya Barahmanta, Meinar Nur Ashrin,
Anne Agustina Suwargiani, Anis Irmawati, Nunuk Purwanti

Editorial Staff and Administrator

Carissa Endianasari, Fitri Puji Rahayu

Peer Review

Udijanto Tedjosasongko, Son mee kyoung, Eha Renwi Astuti,
Syamsulina Revianti, Rima Parwatisari, Arifzan Razak, Sarianoferni,
Dian Mulawarmanti, Mei Syafriadi, Soetjipto

Jurnal Kedokteran Gigi diterbitkan setiap bulan Februari dan Agustus oleh
Fakultas Kedokteran Gigi Universitas Hang Tuah.

ALAMAT REDAKSI

Cp. Carissa Endianasari
Fakultas Kedokteran Gigi-Universitas Hang Tuah
Jl. Arief Rahman Hakim 150 Surabaya
Telp. 031-5945864, 5945894 psw 219/220 Fax. 031-5946261
E-mail: journal.denta@hangtuah.ac.id
<http://journal-denta.hangtuah.ac.id>

DAFTAR ISI

Susunan Redaksi	i
Daftar Isi	ii
Biofilm Effectivity of Ethanol Extracts (Casuarina equisetifolia) Leaves of the Bacteria Enterococcus faecalis <i>Debby Rosalina, Aprilia, Dian Widya Damaiyanti</i>	58-64
Choices and Reasons for RSGM Baiturrahmah Co-ass Student Batch 2018 in Continuing Specialization <i>Adni Muswita, Sri Pandu Utami</i>	65-70
Invitro Micro Encapsulation of Beta Tri Calcium Phosphate from <i>Anadara granosa</i> Shell Synthesis <i>Diana Soesilo, Aprilia, Mohammad Basroni Rizal</i>	71-76
Management of Herpangina <i>Maharani Laillyza Apriasari, Juliyatin Putri Utami</i>	77-81
The Effect of Addition of Nano Hydroxyapatite Powder of <i>Anadara granosa</i> Shells on Surface Roughness of Heat Cured Acrylic Resin <i>Aris Aji Kurniawan, Dian Noviyanti Agus Imam, Helmi Hirawan</i>	82-87
The Effect of Proanthocyanidin Cocoa Pod Rind Extract (<i>Theobroma cacao</i> L.) on MMP-8 Expression in Gingival Tissue of Periodontitis Rats Model <i>Yani Corvianindya Rahayu, Agustin Wulan Suci Dharmayanti, Anya Tania Larasati</i>	88-93
The Effect of Purple Leaf Extract (<i>Graptophyllum pictum</i> L. Griff) to The Amount of Fibroblast in Gingiva Rat Wistar induced by <i>Porphyromonas gingivalis</i> <i>Savira Aulia Rachim, Atik Kurniawati, Pudji Astuti</i>	94-100
The Management of Transalveolar Surgery Teeth with Pulpal Polyps Condition <i>Bayu Vava Violeta, Bambang Tri Hartomo</i>	101-108

The Effect of Proanthocyanidin Cocoa Pod Rind Extract (*Theobroma cacao* L.) on MMP-8 Expression in Gingival Tissue of Periodontitis Rats Model

Yani Corvianindya Rahayu *, Agustin Wulan Suci Dharmayanti **, Anya Tania Larasati ***

* Department of Oral Biology, Faculty of Dentistry, University of Jember

** Department of Biomedical, Faculty of Dentistry, University of Jember

*** Undergraduate program, Faculty of Dentistry, University of Jember

Online submission : 06 November 2020

Accept Submission : 08 November 2020

ABSTRACT

Background: Periodontitis is periodontal tissue inflammation due to *Porphyromonas gingivalis* which invades the gingival tissue due to the activity of virulence factors. This causes the host immune system changes and increases MMP-8 production in periodontal tissue so resulting excessive tissue destruction. Cocoa pod rind containing proanthocyanidin compound as anti-inflammatory drugs is given to reduce MMP-8 and cure periodontitis. **Objective:** To examine the effect of proanthocyanidin extract of cocoa pod rind (*Theobroma cacao* L.) on decreasing MMP-8 expression in gingival tissue of periodontitis rats model. **Materials and Methods:** The samples used were 16 male Wistar rats divided into 2 groups, placebo gel for the control group and proanthocyanidins gel for the treatment group.). Each group was induced by *P.gingivalis* bacteria every 3 days for 14 days and then smeared with placebo gel and proanthocyanidin gel for 7 and 14 days. Then all rats' gingival tissue were taken and made preparations to be observed under a microscope and analyzed using immunoratio software. **Result:** There were differences in MMP-8 expression based on observation time ($p < 0.05$). MMP-8 expression in the 7th day control group was lower than the 14th day and MMP-8 expression in the 7th day treatment group was higher than the 14th day. **Conclusion:** Proanthocyanidin of cocoa pod rind extract (*Theobroma cacao* L.) can reduce MMP-8 expression in gingival tissue of periodontitis rats model.

Keywords: Periodontitis, MMP-8, Proanthocyanidin extract cocoa pod rind (*Theobroma cacao* L.)

Correspondence: Yani Corvianindya Rahayu, Departement of Oral Biology, Faculty of Dentistry, Jember University, Indonesia, Email: yanicorvi25@gmail.com

INTRODUCTION

Periodontitis is an inflammation of the periodontal tissue affecting almost 75% of Indonesia's population of various age groups. Periodontitis caused by gram-negative bacteria is a continuation from gingivitis which will cause attachment loss and end in tooth loss¹.

Porphyromonas gingivalis is one of the proteolytic bacteria because the virulence factor of this bacterium contains protease enzymes, such as capsules, fimbriae, gingipains, and lipopolysaccharides. This protease enzyme is used by *P.gingivalis* bacteria to fight the host defense system and cause degradation of the structural proteins that make up the gingival and periodontal tissues, making it easier to invade deeper gingival tissue. Degradation of this protein will trigger damage and loss of attachment to the periodontal tissue, especially the gingiva².

The gingival tissue is composed of keratinized stratified squamous epithelium which functions to support the integrity of the gingival tissue. Gingival integrity is a form of the body's defense mechanism through physical defense in overcoming dangerous agents, including bacteria. The integrity of the gingival epithelium can be impaired or damaged by bacterial protease enzyme activity or the body's response activity in eliminating bacteria that cause periodontal disease, one of which is cytokine inflammation as a host response to *P.gingivalis* infection².

Colonization and infection of *P.gingivalis* will increase the production of proinflammatory cytokines, including matrix metalloproteinase-8 (MMP-8) which is a collagen-breaking enzyme in connective tissue and holds the greatest control of collagenase activity in the gingival tissue in the periodontitis³. MMP-8 as a biomarker of periodontal tissue inflammation is found in low levels because of the high levels of natural inhibitors of MMP-8 in healthy periodontal tissue and will increase if inflammation occurs⁴.

In order to reduce the production of proinflammatory cytokines in periodontitis from excessive bacterial activity, the treatment that have an anti-inflammatory effect need to be made, one of the treatment comes from cocoa pod rind (*Theobroma cacao L.*) which is rich in polyphenol compounds and allegedly have these effects. The rind cocoa is very abundant in Jember as agricultural waste and has not been utilized properly. It contains water (85%), crude fiber (27%), and protein (8%). The polyphenol compounds including proanthocyanidin (58%), catechins (37%), and anthocyanins (4%)⁵.

Proanthocyanidin is the most abundant polyphenol in the cocoa pod rind (*Theobroma cacao L.*) with utilization that is still not optimal. Previous studies have shown that 10% of proanthocyanidin in rind cocoa can reduce COX-2 levels in periodontitis, whereas COX-2 is related in the regulation of MMP-8 It is suspected that the decrease in COX-2 can reduce MMP-8 levels so that bacterial activity is also inhibited. Proanthocyanidin replaces an inhibitor of MMP-8 activity because of its ability to inhibit the secretion of MMP-8 by diverting the nuclear signal factor-kappaB (NF-κB)⁶.

MATERIALS AND METHODS

This study is a type of experimental laboratory research with the post test only control group design. The code of ethics was obtained from the Health Research Ethics Commission (KEPK) at the Faculty of Dentistry, University of Jember with number 440 /UN25.8/ were observed on the 7th and 14th days. All rats were induced by *Porphyromonas gingivalis* (ATCC 33277) every 3 days for 14 days.

After that, the gingival margins of the mesial portion of the maxillary first molars of the right region were given placebo gel once a day for 7 and 14 days in the control group and were given a cocoa pod rind (*Theobroma cacao L.*) (100 mg/ml) extract once a day for 7 and 14 days



in the treatment group. Then the gingival tissue was removed by cutting the maxillary region of the right region from the mesial portion of the first molar to distal the second or third molar after being anesthetized using ketamine anesthesia. Samples were put into formalin buffer for 24 hours so that the tissue were not damaged and then decalcified with 10% formic acid to make it soft. After that, the tissue samples were processing then coloring using IHC.

The research data were obtained from observations of histological preparations from each group. Analysis of MMP-8 expression in gingival tissue was done on the 7th and 14th days. Observations were carried out with a binocular microscope with the help of optilab with a magnification of 100X. Samples were observed for brownish color intensity arising from IHC staining and determined based on the percentage results that emerged from the Immunoratio software. The data obtained then analyzed using One-Way ANOVA test from SPSS.

Table 1. Calculation of MMP-8 expression in gingival tissue

Sample Groups	7 th Day	14 th Day	p
Control (K)	47.25±35.94	55.75±10.720	0.002
Treatment (P)	39.50±1.291	36.50±1.291	

KEPK / DL / 2019. The making of proanthocyanidin cocoa pod rind extract took place in Phytochemical Laboratory of the Faculty of Pharmacy, Jember University, manufacture and rejuvenation of *P.gingivalis* bacterial suspension in the Laboratory of Microbiology, Faculty of Dentistry, University of Jember, maintenance and treatment of experimental animals in the Biomedical Laboratory of the Faculty of Dentistry, University of Jember and staining of Immunohistochemicals (IHC) in the Laboratory of Histology, Biomedics, Faculty of Dentistry, University of Jember.

The samples used were 16 male Wistar rats which were divided into two groups (control

group and treatment group). Each group consisted of 8 rats which were divided into 2 subgroups with each subgroup consisting of 4 male Wistar rats which The data shows the mean and standard deviation in each sample group.p is the result of the significance of the One- way ANOVA test.

The data obtained were tested for normality using Shapiro-Wilk and homogeneity tests using the Levene Test. After knowing the data are normally distributed and homogeneous, the data were analyzed using the One-way ANOVA test to find out whether or not there were significant differences regarding MMP-8 expressions in all groups. One- way ANOVA test results showed that there were differences in the mean expression of MMP-8 in the treatment and control groups ($p < 0.05$) (Table 1).

Table 2. Summary of the Post Hoc Least Significant Difference (LSD) MMP-8 expression in each sample group

Groups	K7	K14	P7	P14
K7		0.058	0.080	0.021*
K14	0.058		0.002*	0.000*
P7	0.080	0.002*		0.473
P14	0.021*	0.000*	0.473	

Notes:

K7: 7th day control group K14: 14th day control group P7: 7th day treatment group P14: 14th day treatment group

(*): there are significant differences ($p < 0,05$)

Furthermore, the data were tested to determine the average differences between the study groups using the Post Hoc Least Significant Difference (LSD) test. LSD test results showed that there were significant differences in MMP-8 expression between the 7th day control group and the 14th day treatment group and between the 14th day control group and the 14th day treatment group ($p < 0.05$). While the expression of MMP-8 in the control group on the 7th day and the 14th day, the

control group on the 7th day and the treatment group on the 7th day, the control group on the 14th day and the treatment group on the 7th day and the treatment group on the 14th day (Table 0.05)

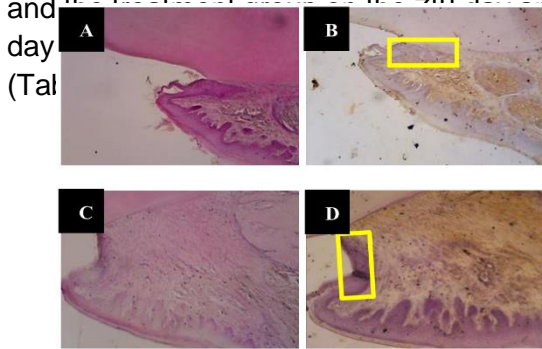


Figure 1. Histological pictures of rat gingival tissue of the 7th day control and treatment group (100X)

Notes:

Yellow squares indicate the epithelial tissue in which MMP-8 is expressed

A: Gingival tissue of the 7th day control group with HE staining (100X)

B: Gingival tissue of the 7th day control group with IHC staining (100X)

C: Gingival tissue of the 7th day treatment group with HE staining (100X)

D: Gingival tissue of the 7th day treatment group with IHC staining (100X)

Figure 1 are some histological pictures of periodontitis rat gingival tissue with HE and IHC staining of the 7th day control and treatment group. MMP-8 expressions were more visible on the 7th day control group (K) than the treatment group (P) because there were more cells expressing MMP-8 in the epithelial tissue in the yellow square from control group (K).

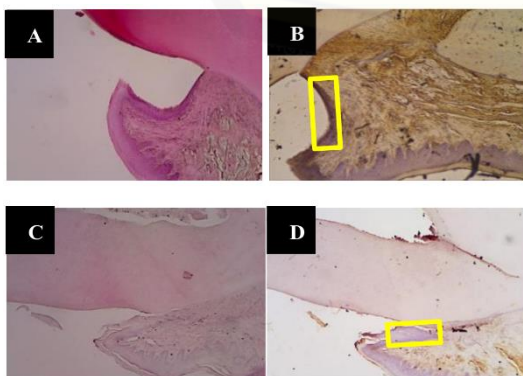


Figure 2. Histological pictures of rat gingival tissue of the 14th day control and treatment group (100X)

Notes:

Yellow squares indicate the epithelial tissue in which MMP-8 is expressed

A: Gingival tissue of the 14th day control group with HE staining (100X)

B: Gingival tissue of the 14th day control group with IHC staining (100X)

C: Gingival tissue of the 14th day treatment group with HE staining (100X)

D: Gingival tissue of the 14th day treatment group with IHC staining (100X)

Figure 2 are some histological pictures of periodontitis rat gingival tissue with HE and IHC staining of the 14th day control and treatment group. MMP-8 expressions were less visible on the 14th day treatment group (P) than the control group (K). This is indicated by the less number of cells expressing MMP-8 in the epithelial tissue in the yellow square from treatment group (P).

DISCUSSION

The results showed that there were differences in MMP-8 expression based on the time of observation in the control and treatment groups. MMP-8 expression on 7th day control group was lower than 14th day. This is probably caused by an inflammatory process in the gingival tissue due to the induction of *Porphyromonas gingivalis*. Inflammation due to *P.gingivalis* triggers collagen degradation involving the MMP-8 enzyme. MMP-8 activity will continue throughout the inflammatory process. The results of Ji (2015) showed that an increase in MMP-8 expression was in line with increased periodontal tissue damage in a rat model that had periodontitis for 14 days.

In the treatment group, MMP-8 expression on the 7th day was higher than the 14th day. It is possible that the administration of proanthocyanidin in cocoa od rind (*Theobroma cacao L.*) is able to inhibit the inflammatory process due to *P.gingivalis* induction through

decreased MMP-8 activity. Inhibition of the inflammatory process will cause a decrease in the activity of enzymes involved in the inflammatory process, such as MMP-8 (Sorsa, 2016). The results of Lagha's research (2015) showed that the proanthocyanidin of cranberries was able to reduce MMP-8 expression so that there was no excessive tissue damage.

In addition, MMP-8 expression on the 7th day control group was higher than the 7th day treatment group, as well as on the 14th day. This is probably because the proanthocyanidin is able to inhibit the inflammatory process. Proanthocyanidin in grape seeds is known to have anti-inflammatory activity because it can inhibit the production of proinflammatory cytokines, one of which is MMP-8, so that there is no inflammatory process which can result in periodontal tissue damage^{3,7,8}.

Proanthocyanidin is the most polyphenol compound (58%) in the rind cocoa (*Theobroma cacao L.*) which is suspected to have anti-inflammatory activity. This is because proanthocyanidin is able to inhibit inflammation by inhibiting the activity of *P.gingivalis* virulence factors that invade the gingival tissue. This activity can reduce the production of proinflammatory cytokines, one of which is MMP-8. MMP-8 reduction will inhibit excessive tissue damage³.

Porphyromonas gingivalis triggers inflammation through the activity of virulence factors that cause host immune deregulation. This process involves proinflammatory cytokines, one of which is MMP-8. MMP-8 is the result of activation of proMMP-8. *P.gingivalis* virulence factor causes MMP-8 production to increase, triggering degradation of type I and III collagen which is a key factor in excessive tissue damage in periodontitis⁷.

This tissue damage process can be inhibited using anti-inflammatory drugs, such as non-steroidal anti-inflammatory drugs (NSAIDs). NSAIDs can prevent tissue damage by modulating the host immune response thereby inhibiting the inflammatory process. NSAIDs can

inhibit proMMP-8 activation and reduce other proinflammatory cytokines, such as TNF- α and IL-1 β , by activating the NF- κ B pathway. This pathway will inhibit MMP-8 production⁹. Proanthocyanidin as one of the herbal ingredients which is allegedly inhibit the inflammatory process through the NF- κ B pathway. PAC resulted in inhibition of translocation of NF- κ B as suggested by decreased protein expression of p65 in the nuclear fraction¹⁰ Under normal circumstances, NF- κ B binds to its inhibitor (I κ B) as an inactive condition in the cytoplasm. NF- κ B is then activated by several stimuli, such as TNF- α and IL-1 β , resulting in an inflammatory process. When NF- κ B is stimulated, I κ B is phosphorylated by I κ B Kinase (IKK) and is degraded. Degraded I κ B will cause NF- κ B to translocate from the cytoplasm to the nucleus to synthesize MMP-8 and cause excessive tissue damage⁶.

Although in this study showed that the proanthocyanidin of cocoa pod rind extract is potent as an anti-inflammatory, but the results of this study still require further research, because the researchers only used a single dose and 2 periods of observation. Lack of observation time in the control group turn out insignificant results on 7th day and 14th day because the inflammatory process is still ongoing. The inflammatory process starts from injury to enter the proliferation phase on the 3rd day until the 21st day. In this phase, MMP-8 will be synthesized and will continue to increase until it reaches its peak on the 21st day then decreases until tissue recovery occurs. Therefore, administration of proanthocyanidin of cocoa pod rind extract (*Theobroma cacao L.*) can reduce MMP-8 expression during the proliferation phase so as to reduce excessive tissue damage¹¹.

CONCLUSION

Based on the research that has been done, it can be concluded that the proanthocyanidin extract of rind cocoa

(*Theobroma cacao L.*) can give effect in the form of decreased MMP-8 expression in gingival tissue of periodontitis rats model.

REFERENCES

1. Robbihi, Hilmy Ila. 2018. *Path Analysis: The Effect of Smoking on the Risk of Periodontal Disease*. Surakarta: Indonesian Journal of Medicine, 3(2): 99-109, e-ISSN: 2549-0265
2. How, Kah Yan. 2016. *Porphyromonas gingivalis: An Overview of Periodontopathic Pathigen below the Gum*. Malaysia: Frontiers in Microbiology, Vol.7, doi:10.3389/fmicb.2016.00053
3. Sorsa, Timo. 2016. *Analysis Of Matrix Metalloproteinases, Especially MMP-8, In Gingival Crevicular Fluid, Mouthrinse And Saliva For Monitoring Periodontal Diseases*. Singapura: John Wiley & Sons Ltd, Periodontology 2000, Vol. 70: 142–163
4. Rangbulla, Vanik. 2017. *Salivary IgA, Interleukin 1 β , and MMP-8 as Salivary Biomarkers in Chronic Periodontitis Patients*. Panchkulla: The Chinese Journal of Dental Research, 20(1), 43-51
5. Dipahayu, Damaranie. 2018. Karakteristik Fisika Masker Gel Peel Off dan Krim Wajah dengan Kandungan Ekstrak Kulit Buah Kakao (*Theobroma cacao, L.*) Sebagai Antioksidan Topikal. Surabaya: Journal of Pharmacy and Science, 3(2), P-ISSN : 2527-6328, E-ISSN : 2549-3558
6. Lagha, Amel Ben. 2015. *Wild Blueberry (Vaccinium Angustifolium Ait.) Polyphenols Target Fusobacterium Nucleatum And The Host Inflammatory Response: Potential Innovative Molecules For Treating Periodontal Diseases*. Canada: Journal of Agricultural and Food Chemistry, 63(31), 6999–7008., doi:10.1021/acs.jafc.5b01525
7. Jaroslav Mysak J, Podzimek S, Sommerova P, Lyuya-Mi Y et al. Porphyromonas gingivalis: Major Periodontopathic Pathogen Overview. Journal of Immunology Research. 2014. Open Access.
8. Ji. 2015. *Bacterial Invasion And Persistence: Critical Events In The Pathogenesis Of Periodontitis*. Singapura: John Wiley & Sons Ltd, J Periodont Res; 50: 570–585, doi:10.1111/jre.12248
9. Kaur, Manpreet. 2017. *Subantimicrobial Dose Doxycycline in Treatment of Periodontitis*. Rohtak: International Journal of Applied Dental Sciences, 3(2): 41-43, ISSN 2394-7489
10. Patel K, Neto C, Pass KC, Hurta R. Proanthocyanidins from Cranberry (*Vaccinium macrocarpon*) Inhibit Matrix Metalloproteinase Expression in Prostate Cancer Cells by Affecting Multiple Cell Signaling Pathways. Journal of Federation of American Societies for Experimental Biology. April 2010: Vol 24 Issue S1. Suppl. 683-2
11. Mester, Alexandru. 2019. *Periodontal Disease May Induce Liver Fibrosis in an Experimental Study on Wistar Rats*. Romania: American Academy of Periodontology, Journal of Periodontology, DOI 10.1002/JPER.18-0585, ISSN 1943-3670

