




- 1 Parents Experience in Providing Reproductive Health Education for Adolescent with visual Disability in Yogyakarta
- 2 Implementation-Specific Nutritional Interventions in Stunting Prevention : Literature Review
- 3 Renoprotective Activity of *Moringa oliefera* Lamk Toward Kidney Injury Rats Induced by Streptozotocin
- 4 Experience of Resilience of Chronic Renal Failure Patients with Haemodialysis Therapy : a Qualitative Study
- 5 Why did You do that to Me? : A Systematic Review of Cyberbullying Impact on Mental Health and Suicide among Adolescent
- 6 Application of Complementary and Alternative Medicine Therapy on Patient with Postoperative
- 7 Pain After Cardiac Surgery : a Literature Review
- 8 Caregiver's Burden Among Families of Hemodialysis Patient : a Cross Sectional Study
- 9 The Effectiveness of Topical Plants Oils Against Pain in Knee Osteoarthritis Patient
- 10 Effectiveness of Cadre Capacity Building Activities : a Comparative Design

**Published by:**  
**Faculty of Nursing Universitas Jember**  
**in collaboration with**  
**The Indonesian Nurses Association (PPNI) District of Jember**





Current Archives About ▾

[Home](#) / [Editorial Team](#)

### Editor in Chief

- Assist Prof. Dr. Iis Rahmawati, Scopus ID: [57192653086](#)  
Assistant Professor Faculty of Nursing, University of Jember, Jember, Indonesia

### Managing Editors

- Assist Prof. Nurfika Asmaningrum, PhD Scopus ID: [57200570663](#)  
Assistant Professor Faculty of Nursing, University of Jember, Jember, Indonesia

### Editorial Board

- Prof. Chichen Zhang, PhD Scopus ID: [55661571300](#)  
Professor Department of Health Management, School of Health Services Management, Southern Medical, Guangdong, China
- Prof. Dr. Titin Andri Wihastuti, S.Kp, M.Kes Scopus ID: [56368450300](#)  
Professor School of Nursing, Faculty of Medicine, Universitas Brawijaya, Malang, Indonesia
- Nguyen Thi Thu Hong, PhD [Orcid ID](#)  
Faculty of Nursing, Hai Phong University of Medicine and Pharmacy, Vietnam
- A/Prof. Ebaa Marwan S. Felemban, PhD Scopus ID: [57204157756](#)  
Assistant Professor of Nursing Education, Nursing Department, Collage of Applied Medical Sciences, Taif University, Saudi Arabia
- A/Prof Yunita Sari, PhD Scopus ID: [24077392400](#)  
Associate Professor School of Nursing, Faculty of Health Science, Universitas Jenderal Soedirman, Purwokerto, Indonesia
- Saldy Yusuf, PhD, Scopus ID: [55621726400](#)  
Faculty of Nursing, Universitas Hassanudin, Makasar, Indonesia

- Digital Repository Universitas Jember
- A/Prof. Tantut Susanto, PhD, Scopus ID: [571915911437](#)  
Associate Professor Faculty of Nursing, University of Jember, Jember, Indonesia
  - Siti Nur Kholifah, PhD, Sinta ID: [6011090](#)  
School of Nursing, Poltekkes Kemenkes Surabaya, Surabaya, Indonesia
  - Ferry Efendi, PhD, Scopus ID: [55301269100](#)  
Faculty of Nursing, Universitas Airlangga, Surabaya, Indonesia
  - Muhamad Zulfatul A'la, M.Kep Sinta ID: [255738](#)  
Faculty of Nursing, Khon Kaen University, Khon Kaen, Thailand
  - Rismawan Adi Yunanto, M.Kep Scopus ID: [57208883468](#)  
Faculty of Nursing, University of Jember, Jember, Indonesia
  - Fitrio Devi Antony, M.Kep Sinta ID: [6682768](#)  
Faculty of Nursing, University of Jember, Jember, Indonesia
  - Eka Afdi Septiyono, M.Kep Sinta ID: [6713100](#)  
Faculty of Nursing, University of Jember, Jember, Indonesia
  - Assist Prof. Anisah Ardiana, PhD Sinta ID: [6682134](#)  
Assistant Professor Faculty of Nursing, University of Jember, Jember, Indonesia
  - Assist Prof. Dr. Iis Rahmawati, Scopus ID: [57192653086](#)  
Assistant Professor Faculty of Nursing, University of Jember, Jember, Indonesia
  - Kushariyadi, M.Kep Sinta ID: [6117437](#)  
Faculty of Nursing, University of Jember, Jember, Indonesia
  - Kholid Rosyidi Muhammad Nur, MNS, Scopus ID: [57201796540](#)  
Faculty of Nursing, University of Jember, Jember, Indonesia
  - Fahrudin Kurdi, M.Kep Sinta ID: [6717570](#)  
Faculty of Nursing, University of Jember, Jember, Indonesia

### Administration

- Amin Aini, S.Kep  
Faculty of Nursing, University of Jember, Indonesia

JOURNAL ACCREDITATION

# SERTIFIKAT

Kementerian Riset dan Teknologi/  
Badan Riset dan Inovasi Nasional



Petikan dari Keputusan Menteri Riset dan Teknologi/  
Kepala Badan Riset dan Inovasi Nasional  
Nomor 200/M/KPT/2020  
Peringkat Akreditasi Jurnal Ilmiah Periode III Tahun 2020  
Nama Jurnal Ilmiah  
**NurseLine Journal**

E-ISSN: 2541464X

Penerbit: Fakultas Keperawatan Bekerja Sama dengan PPNi Kabupaten Jember

Ditetapkan sebagai Jurnal Ilmiah

## TERAKREDITASI PERINGKAT 3

Akreditasi Berlaku selama 5 (lima) Tahun, yaitu  
Volume 5 Nomor 1 Tahun 2020 sampai Volume 9 Nomor 2 Tahun 2024

Jakarta, 23 Desember 2020

Menteri Riset dan Teknologi/  
Kepala Badan Riset dan Inovasi Nasional  
Republik Indonesia,  
*Bambang P. S. Brodjonegoro*



Nurseline Journal

# S3

H-INDEX : 9  
H5-INDEX : 8



last update : 2021-08-12 powered by [sinta2.ristekdikti.go.id](http://sinta2.ristekdikti.go.id)



JOURNAL TEAM

Editorial Team

Reviewer

SUBMISSION

Online Submission

Author Guidelines



---

**RENOPROTECTIVE ACTIVITY OF MORINGA OLEIFERA LAMK TOWARD KIDNEY INJURY RATS INDUCED BY STREPTOZOTOCIN**

**Giovani Gianosa<sup>1</sup>, Suryono Suryono<sup>2\*</sup>, Ali Santosa<sup>3</sup>**

Faculty of Medicine, Jember University, Jember, Indonesia

<sup>1</sup>Medical Education Study Program, Faculty of Medicine, Jember University, Jember, Indonesia

<sup>2</sup>Cardiology Medicine Department, Faculty of Medicine, Jember University, Jember, Indonesia

<sup>3</sup>Internal Medicine Department, Faculty of Medicine, Jember University, Jember, Indonesia

---

**ABSTRACT**

---

**\*Corresponding Author:**

Suryono

Faculty of Medicine, Jember University,  
Jember, Indonesia

suryonofiha@gmail.com

**Article Info:**

Submitted: 2021-01-18

Reviewed: 2021-07-27

Revised: 2022-04-09

Accepted: 2022-04-26

Diabetes mellitus (DM) is a group of metabolic diseases characterized by hyperglycemia that occurs due to abnormalities in insulin secretion. Chronic hyperglycemia in diabetes causes dysfunction and failure of various organs of the body such as the kidneys, eyes, nerves, heart and blood vessels. The purpose of this study was to analyze how the effect of the treatment given by Moringa leaves on diabetes mellitus conditions, especially on glomerular histopathological damage. In this study, to make diabetic mice using the induction of streptozotocin after which Moringa leaves were given as a form of treatment. The dosage of Moringa leaf extract was divided into 5 groups, namely 62.5mg / kg, 125mg / kg, 250mg / kg, 500mg / kg, and 1000mg / kg doses. The histopathological image obtained will be assessed using scoring, and for data analysis using the Kruskal-Wallis test and followed by the post hoc test using the Mann-Whitney test. The results of this study indicate that there is an effect of giving Moringa leaf extract on glomerular histopathological damage. The results of the Kruskal-Wallis data analysis test showed significant results, namely  $p = 0.001$ , after the data obtained were significant data, then it was continued with the post hoc test using the Mann-Whitney test with significant results when compared with negative controls ranging from the 125mg / kg dose group 1000mg / kg.

**Keywords:**

Diabetes, Moringa, Moringa Oleifera Lamk, Renoprotective, Streptozotocin

---

**BACKGROUND**

Diabetes mellitus (DM) is a collection of metabolic diseases with hyperglycemia conditions that occur due to abnormalities in insulin secretion, insulin action or both. Chronic hyperglycemia found in diabetes is associated with long-term damage, dysfunction

or failure of several organs, especially the eyes, kidneys, nerves, heart and blood vessels. Hypertension caused by conditions of oxidative stress due to prolonged diabetes will cause impaired perfusion, especially in the kidney, namely the glomerulus and impaired glomerular filtration which causes damage to the glomerulus (Palygin et al., 2017). The global

prevalence of diabetes among adults over 18 has increased from 4.7% in 1980 to 8.5% in 2014 (WHO, 2018). The International Diabetes Federation (IDF) Atlas in 2017 reported that the epidemiology of diabetes in Indonesia still shows an increasing trend. Indonesia itself is the sixth country in the world after China, India, the United States, Brazil and Mexico with around 10.3 million people with diabetes aged 20-79 years. Diabetics in Indonesia in 2015 were ranked seventh in the world with an estimated 10 million diabetes sufferers (IDF Atlas, 2015). According to the Basic Health Research (Riskesmas), there is a significant increase in the prevalence rate of diabetes, from 6.9% in 2013 to 8.5% in 2018. So it is possible that 16 million people in Indonesia are at risk of developing other diseases such as failure kidney (KEMKES, 2018).

As science develops, there is a need for innovation in diabetes treatment, namely by using drugs with natural ingredients, one of which is the Moringa plant. In Indonesia, Moringa plants have been widely known because many people believe this plant can be an alternative for disease treatment and an easy way to get these plants around their homes. Moringa leaves contain antioxidants, including phenols, alkaloids, terpenoids, saponins, and tannins. Phenol itself has various derivatives of chemical compounds, one of which is flavonoids. Flavonoids themselves have been clinically proven to be useful as a cardioprotective, antioxidant, and anti-inflammatory (Redha, 2013).

The flavonoids found in fruit, flowers, stems and leaves have antioxidant benefits. Research states that the effect of Moringa oleifera in diabetic male rats can reduce blood sugar and reduce free radicals (Sithole et al., 2009). Therefore, the researcher wanted to know the renoprotective effect of Moringa oleifera Lamk leaves on the histopathological structural damage of the rat kidney glomerulus induced by streptozotocin.

## METHODS

This research is a true experimental design with a post test only control group design which was conducted from November 2019 to January 2020. This study used 28 male Wistar rats (*Rattus norvegicus*) as a population weighing approximately at 200 -300 grams and divided into 7 groups through simple random sampling method. The homogeneity of the groups was carried out by simple random sampling method, so that the average weight of each group was the same. Rats were induced by 45mg / kg of streptozotocin intraperitoneally using and then given

moringa leaf extract at doses of 62.5 mg / kg (P1), 125 mg / kg (P2), 250 mg / kg (P3), 500 mg / kg (P4), and 1000 mg / kg (P5) using gastric probe. This study had a positive control group that was only induced by streptozotocin without given Moringa leaf extract and a negative group control that was not treated. Moringa leaf extract was given every day for 4 weeks, and after 4 weeks of treatment the rats were terminated by cervical dislocation and operated on to obtain kidney preparations. The renal preparations were made into histological preparations by using Hematoxylin Eosin (HE) staining and then the glomerular preparations were read with 400x magnification on a light microscope with the scoring method.

Analysis of the research data was processed using IBM SPSS version 26.0. This research variable is non-parametric data so that using the Mann-Whitney test to analyze the scoring results to determine the level of improvement produced by Moringa leaf extract. The results of the study are said to be significant if  $p < 0.05$ .

## RESULTS

The parameters used in glomerular damage using these criteria are based on the glomerular histopathological scoring criteria (Alicic et al., 2017), namely: 0: normal glomerulus; 1: thickening of the glomerular basement membrane (GBM) and mesangial expansion; 2: nodular sclerosis (Kimmelstiel-Wilson Lesion); 3: capillary dilatation (microaneurysm) with hyaline subintima; 4: advancing diabetic glomerulosclerosis or glomerulus obsolescent.

The results of observations of rats kidney damage in the control (K-) and positive control (K +) groups can be seen in Figure 1.

The results of observations of rat glomerular damage in the 62.5mg / kg (P1) dose group and the 125mg / kg (P2) dose group can be seen in Figure 2.

The results of observations of rat glomerular damage in the dose group of 250mg / kg (P3), dose of 500mg / kg (P4), and doses of 1000mg / kg (P5) can be seen in Figure 3.

The results of statistical test analysis using the Kruskal-Wallis test obtained a significance value of 0.001 ( $p < 0.05$ ), which means that there is a significance of rat glomerular damage in this study. The results of statistical tests with Kruskal-Wallis can be seen in table 2.

The data obtained through the Kruskal-Wallis test obtained significant results then continued with the Post Hoc test using the Mann-Whitney test to see the comparison between groups which can be seen

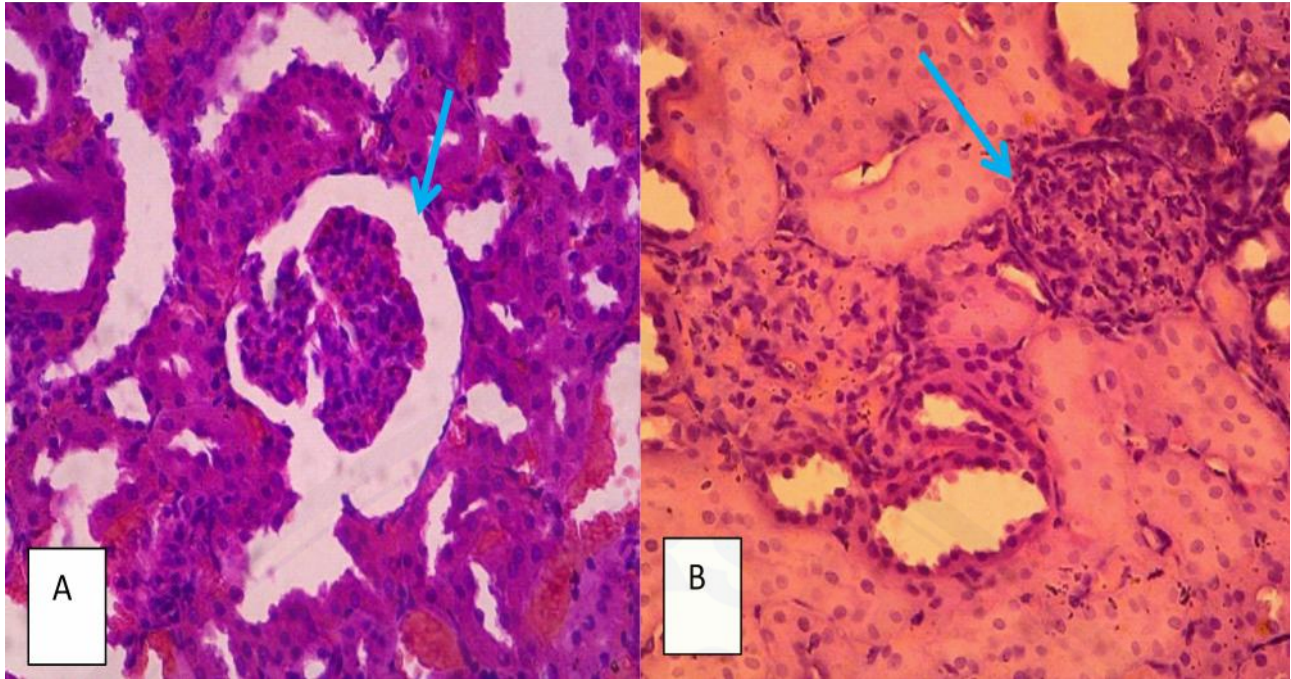


Figure 1 (A) Overview of glomerular damage in the negative control group (K-) with 400x magnification. There were no signs of glomerular damage. (B) Overview of glomerular damage in the positive control group (K+) with magnification of 400x. There was severe damage to all parts of the glomerulus which was marked by scar tissue.

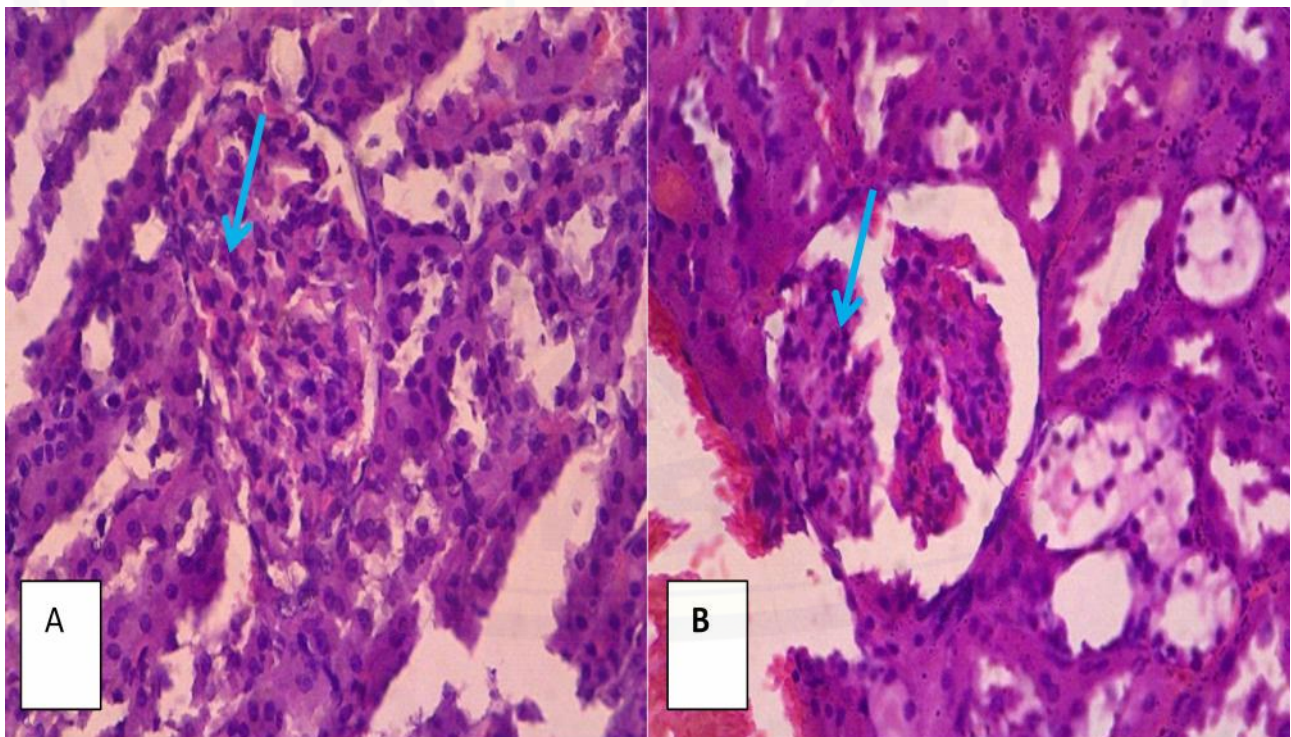


Figure 2 (A) Overview of glomerular damage in the 62.5 mg / kg (P1) dose group with a magnification of 400x. There was severe damage to all parts of the glomerulus which was marked by scar tissue and no improvement was seen at this dose. (B) Overview of glomerular damage in the 125mg / kg (P2) dose group with 400x magnification. There is a picture of nodular sclerosis and the appearance of scar tissue on the glomerulus.

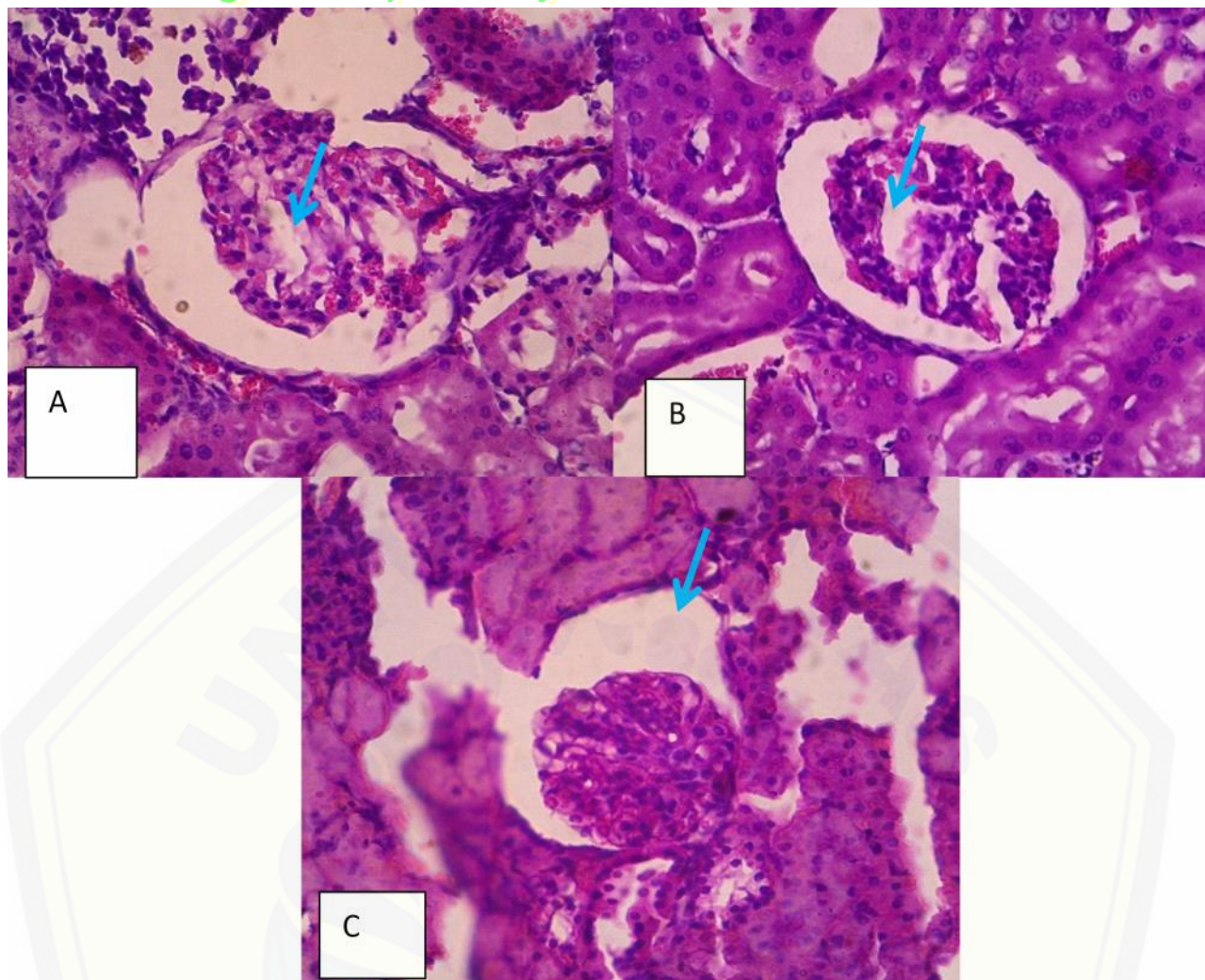


Figure 3 (A) Overview of glomerular damage in the 250 mg / kg (P3) dose group with a magnification of 400x. There is a picture of expansion of mesangial cells and a nodular sclerosis is seen, which is indicated by bleeding in the glomerulus. (B) Overview of glomerular damage in the 500 mg / kg (P4) dose group with magnification of 400x. There is a picture of expansion of mesangial cells in the glomerulus. (C) Overview of glomerular damage in the 1000 mg / kg (P5) dose group with magnification of 400x. In this picture there is an improvement from the dose as evidenced by the appearance of normal glomerulus.

From the post hoc data analysis performed, the results of the scoring of renal glomerular damage in male Wistar rats between the treatment group and the negative group were obtained. The comparison between the P5 and P3 groups with the negative group had the most significant result, namely  $p = 0.011$  ( $<0.05$ ), while the comparison between the P1 group and the negative group was not significant, namely  $p = 0.131$  ( $> 0.05$ ). In all these data groups P2 to P5 obtained significant results ( $p < 0.05$ ) when compared to the negative group.

## DISCUSSION

The result of this study is that there is an effect of moringa leaf extract induced in male Wistar rats with

streptozotocin induced diabetes mellitus models. There is an improvement in the glomerular histopathological picture of male Wistar rats. In the comparison between the P1 group and the negative group there was a change but the results were not significant, whereas if the negative group was compared with the P2, P3, P4, and P5 groups there was a significant change in improvement based on the results of the Mann-Whitney test.

Based on the results obtained, the antioxidant compounds, namely flavonoids, tannins, saponins, and quercetin, contained in Moringa leaves, were able to repair glomerular damage of male Wistar rats. These antioxidant compounds work when male Wistar rats are in a hyperglycemic state which causes oxidative stress conditions. This oxidative stress condition will



Table 1 Scoring Results for Glomerular Damage Observation

Group	N	Max Score	Min Score
Normal	4	0	0
Negative	4	4	4
P1	4	2	4
P2	4	3	4
P3	4	2	3
P4	4	1	3
P5	4	0	1

Table 2 Kruskal-Wallis Non Parametric Test

Uji Kruskal-Wallis	
<i>Kruskal-Wallis</i>	23,162
Degree of Freedom	6
Significance	0,001

Table 3 Mann-Whitney test for the Positive group

Groups	<i>P</i>
P1	0,131
P2	0,040
P3	0,011
P4	0,013
P5	0,011

trigger an increase in nitric oxide in the rat body so that the amount of endothelial nitric oxide synthase (eNOS) is decreased or deficient. When eNOS is deficient, blood pressure drops so that kidney damage will occur. In the state of diabetes mellitus, the rats will continue to experience hyperglycemia so that an oxidative stress reaction will arise which will cause a continuous deficiency of eNOS. This causes the level of kidney damage experienced by rats to con-

tinue to increase (Palygin et al., 2017).

The antioxidant compounds possessed by Moringa leaves are able to inhibit oxidative stress caused by the hyperglycemic state in male Wistar rats. These the hyperglycemic state in male Wistar rats. These antioxidant compounds are obtained from the extraction process of moringa leaves that have been dried and mashed and then mixed with 96% ethanol in a ratio of 1 to 4, namely 1 kilogram of Moringa leaf

powder with 96% ethanol as much as 4 liters which are then left to stand for 48 hours in a closed state. The results of macerated moringa leaves for 48 hours are filtered using filter paper then evaporated using a water bath at a temperature of 60 ° C until the macerated preparation becomes thick like a paste (Wardani et al., 2017). After the maceration process is complete and the moringa leaf extract has become a paste then diluted by weighing the extract required and then dissolving it with aquadest and Dimethyle Sulfoxide (DMSO).

In the results of the reading of the preparations carried out by the scoring method, the P2, P3, P4, and P5 treatment groups showed significant results when compared to the negative group, whereas if the P1 group was compared with the negative group, the results were not significant. This shows that the dose of the P1 group, which is 62.5 mg / kg given for 4 weeks, has not shown significant results in improving the glomerular structure of male Wistar rats, while the P2, P3, P4, and P5 groups showed significant results, which means the leaf extract dose. Moringa given at 125 mg / kg to 1000 mg / kg have a renoprotective effect in conditions of hyperglycemia or diabetes mellitus. It can be concluded that 125 mg / kg of Moringa leaf extract has been able to provide a renoprotective effect on glomerular damage due to diabetes mellitus. However, for treatment within 4 weeks the dose has not been able to provide a maximum renoprotective effect on glomerular damage due to diabetes mellitus. In this study, it was found that the dose of 250 mg / kg to 1000 mg / kg Moringa leaf extract dose can provide a renoprotective effect on glomerulus due to diabetes with a scoring result of 4 being a scoring value of 1 to 0 or returning to its normal condition at 1000 mg/kg dose.

The provision of various moringa leaf extracts of 5 doses, namely 62.5 mg / kg, 125 mg / kg, 250 mg / kg, 500 mg / kg, and 1000 mg / kg get varying results, but with the greater the dose given able to provide repair in the glomerular damage of male wistar rats more quickly. This is supported and in line with a similar study conducted by Omodanisi (2017) using only a 250 mg / kg dose, with the result that there was an improvement in the kidney structure of male wistar rats.

The findings of this study confirmed that diabetes is correlated with renal microvascular complication that should be recognized during diabetic patient nursing care. Future research can be conducted to corroborate our findings about the benefit of Moringa leaf extract in improving the treatment outcomes of diabetic patients.

## CONCLUSION

The conclusion that can be drawn is based on the results of the research conducted, it can be concluded that there is an effect of giving Moringa leaf extract and can provide repair of glomerular damage in male wistar rats model of diabetes mellitus induced by 45 mg / kg streptozotocin. The moringa leaf extract could be considered as one of ingredients of non-pharmacological therapy for diabetic care patients.

## REFERENCES

- Ambarwati, A., Sarjadi, S., Johan, A., & Djamiatun, K. 2014. Efek Moringa oleifera terhadap Gula Darah dan Kolagen Matrik Ekstraseluler Sel ? Pankreas Diabetes Eksperimental. *Jurnal Kedokteran Brawijaya*. 28(2): 74-78.
- Artika, F.D. 2019. Pengaruh Pemberian Ekstrak Daun Kelor (*Moringa oleifera* Lamk) ` , X., Wang, Y., Wang, K., Ji, B., Zhou, F. 2018. Stability of a type 2 diabetes rat model induced by high-fat diet feeding with low-dose streptozotocin injection. *Journal of Zhejiang University-Science*. 19(7): 559-569.
- Omodanisi, E.I., Aboua, Y.G., & Oguntibeju, O.O. 2017. Assessmen of the Anti-Hyperglycaemic, Anti-inflammatory and Antioxidant Activities of the Methanol Extract of *Moringa oleifera* in Diabetes-Induced Nephrotoxic Male Wistar Rats. *Pharmacognosy Research*. 9 (12): 183-187.
- Palygin, O., Ilatovskaya, D.V., Levchenko, V., Endres, B.T., Geurts, A.M., & Staruschenko, A. 2018. Nitric oxide production by glomerular podocytes. *Department of Physiology Medical College of Winconsin*. 72: 24-31.
- Redha, A. 2013. Flavonoid: Struktur, Sifat Antioksidatif Dan Peranannya Dalam Sistem Biologis. *Politeknik Negeri Pontianak*.
- Ratliff, B.B., Abdulmahdi, W., Pawar, R., & Wolin, M.S. 2016. Oxidant Mechanisms in Renal Injury and Disease. *New York Medical College Department of Physiology*. 25(3): 119-146.
- Sibiya, N., Ngubane, P., & Mabandla, M. 2017. The Ameliorative Effect of Pectin-Insulin Patch On Renal Injury in Streptozotocin-Induced Diabetic Rats. *Kidney Blood Press Research*. 42(3): 530-540.
- Sithole, H. 2009. A review of the use of Streptozotocin (STZ) in the induction of diabetes in rats and subsequent ocular tissue changes. *University of South Africa*. 68(2): 82-88.

- Sobotta, J., Paulsen, F. & Waschke, J. 2012. Sobotta Atlas of human anatomy. 23rd ed. München: EGC.
- Szkudelski, T. 2001. The Mechanism of alloxan and streptozotocin action in B cells of threat pancreas. *Physiological Research*. (50): 537-546.
- Wardani, D. N. K., Hendarto, H., & Widjiati. 2017. Pengaruh Ekstrak Etanol Daun Kelor (*Moringa oleifera* Lam.) Terhadap Jumlah Sel Mast Pada Mencit (*Mus musculus*) Model Endometriosis. *Jurnal Biosains Pascasarjana*. 19.
- Widowati, I., & Efiyati, S. 2014. Uji Aktivitas Antibakteri Ekstrak Daun Kelor (*Moringa oleifera*) Terhadap Bakteri Pembusuk Ikan Segar (*Pseudomonas aeruginosa*). Universitas Negeri Yogyakarta.
- World Health Organisation. 2003. Definition, Diagnosis and Classification of Diabetes Mellitus and its Complication of Diabetes Mellitus and its Complications, Geneva, Switzerland: WHO.
- Yaturu, S. 2011. Obesity and type 2 diabetes. *Diabetes Mellitu*. 1(4): 10-6.
- Yuliantika, N., Gelgel, K. & Kardena, I. 2013. Efek Toksisitas Ekstrak Daun Sirih Merah Terhadap Gambaran Mikroskopis Ginjal Tikus Putih Diabetik Yang Diinduksi Aloksan. *Bul. Vet. Udayana*, 5(2): 114-121.