


**Post Circumcision Bleeding
due to Undiagnosed Hemophilia: a Case Report**



Oleh:

dr. Muhammad Ali Shodikin, M.Kes., Sp.A
NIP. 19770625 2005 01 1 002

Laboratorium Mikrobiologi
Fakultas Kedokteran
Universitas Jember

Disampaikan pada:
Seminar Nasional (SINAS) Ikatan Dokter Anak Indonesia (IDAI)
Jambi, 24 -25 April 2021

Post Circumcision Bleeding due to Undiagnosed Haemophilia: a Case Report

Monica Bethari Primanesa*
dr. M. Ali Shodikin, M.Kes. Sp.A**

* RSD. dr. Soebandi Jember

** Laboratorium Mikrobiologi Fakultas Kedokteran Universitas Jember /
KSM. Ilmu Kesehatan Anak RSD. dr. Soebandi Jember

Abstract

Background. Hemophilia is an X-linked recessive bleeding disorder caused by the deficiency of coagulation factors VIII, IX, or XI. In Indonesia, it is estimated that there are 20,000 hemophiliacs out of 270 million population. In about 20% of cases no family history is found, but known when there is spontaneous bleeding that occurs after trauma / surgery. The objective of this study is to describe case of post circumcision bleeding due to undiagnosed hemophilia in primary health care facility.

Case. A 5 years old child experienced bleeding seeps for 16 days from circumcision wound performed in primary health care facility. After reoperated in the hospital, the seeps had stopped for a day then seeped again, therefore the patient admitted for third times. There were no history of previous spontaneous bleeding, no family history of bleeding disorders. Physical examination revealed spontaneous bleeding from the circumcision wound (fig. A). Laboratory finding: Haemoglobin = 10.4 g/dL, White Blood Cell = $8.1 \times 10^3 / \mu\text{L}$, Haematocrite = 30.7%, Platelets = $413 \times 10^3 / \mu\text{L}$, PPT = 11.4 seconds, APTT = 92.0 seconds. Complete blood count showed normal result and prolonged APTT with normal PPT.

The patient received 500 IU of factor VIII replacement for 2 days and 125 mg tranexamic acid injection three times a day. 6 Fr urinary catheter insertion was performed, then treated the circumcision wound with tulle dressings, gauze, bandaged with an elastic fixation bandage toward umbilical (fig. B). After 3 days of hospitalization, the spontaneous bleeding had stopped and the patient discharged (fig. C).



Figure A. Post circumcision bleeding



Figure B. Circumcision wound was treated with tulle dressings, gauze, bandaged with an elastic fixation bandage toward umbilical.

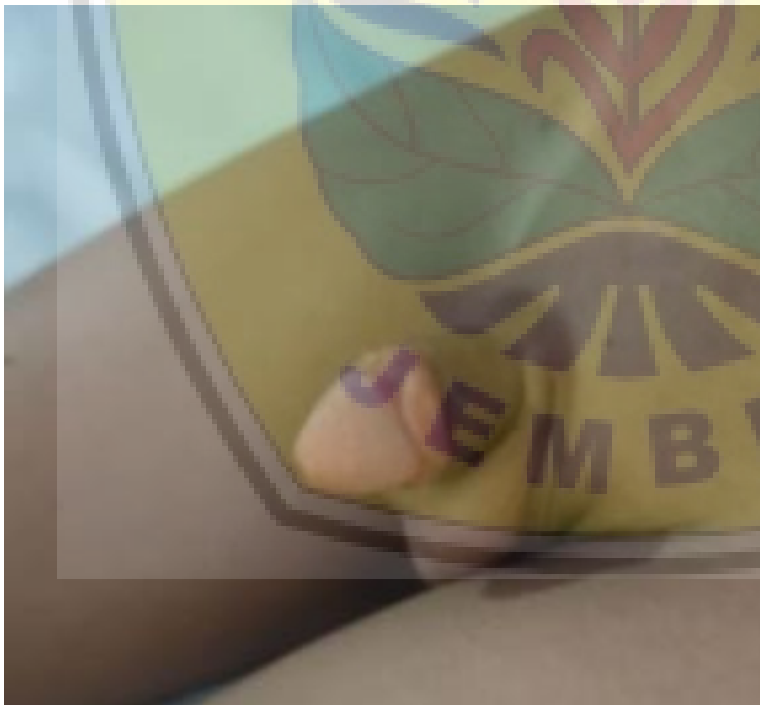

Figure C. After 3 days of hospitalization, the Circumcision wounds was healing.

Discussion. Diagnosis of hemophilia in this patient was based on prolonged APTT with normal PTT. Post circumcision bleeding was the manifestation of 9% hemophiliacs when they first time diagnosed, therefore rarely considered as hemophilia by medical professional in primary health care facilities moreover when there were no abnormality bleeding history to this patient or family. Before performing a surgery, screening questions should be performed regarding previous bleeding history of the patients and bleeding disorder history of their families as a precaution. If there were a history, the patient should be referred to further health care facilities.

Conclusion. Post circumcision bleeding should be considered as hemophilia and the patient should get appropriate treatment immediately.

References:

1. Singh, M., Gupta, L., *et al.* (2020). Hemophilia in children: a clinico-epidemiological profile and review. *Pediatric Review: International Journal of Pediatric Research*, 7(2), 66-72. <https://doi.org/10.17511/ijpr.2020.i02.04>.
2. Swary, A. D. K., Andarsini, M. R., & Hajat, A. (2019). Characteristic of Hemophilia A Patients in Initial Diagnosis in Dr. Soetomo General Hospital Surabaya. *Biomolecular and Health Science Journal*, 2(1), 9-12.
3. Bertamino, M., Riccardi, F., *et al.* (2017). Hemophilia care in the pediatric age. *Journal of clinical medicine*, 6(5), 54.

HOME INFORMASI UMUM PROGRAM REGISTRATION VIRTUAL SINAS LOGIN / SIGN UP

SINAS
WORKSHOP IDAI
JAMBI 2021

Jambi IPS Chapter
In collaboration with
Indonesian Pediatric Society
Working Groups:
Neonatology
Genetic Epidemiology
Neurology/Oncology
Allergy Immunology

SINAS
WORKSHOP IDAI
JAMBI 2021

"Counting Down to 2030: Strengthening
Capacity to Reduce Child Mortality &
Improving Routine Pediatric Care"

Saturday - Sunday, 24-25 April 2021
<http://www.sinasidai-jambi2021.com>

TANGGAL PENTING

- Batas akhir penyampaian Abstrak: 01 APRIL 2021
- Batas akhir penyampaian Karya Foto: 01 APRIL 2021
- Batas akhir registrasi Workshop Online: 15 APRIL 2021
- Batas akhir registrasi SINAS Online: 20 APRIL 2021

UNDUH ANNOUNCEMENT

REGISTRASI ONLINE

Logo of Universitas Jember and other partner institutions.

"Counting Down to 2030: Strengthening Capacity to Reduce Child Mortality and Improving Routine Pediatric Care"

HOME INFORMASI UMUM PROGRAM REGISTRATION VIRTUAL SINAS LOGIN / SIGN UP

SINAS
WORKSHOP IDAI
JAMBI 2021

Jambi IPS Chapter
In collaboration with
Indonesian Pediatric Society
Working Groups:
Neonatology
Genetic Epidemiology
Neurology/Oncology
Allergy Immunology

SINAS
WORKSHOP IDAI
JAMBI 2021

"Counting Down to 2030: Strengthening Capacity to Reduce
Child Mortality & Improving Routine Pediatric Care"
Saturday - Sunday, 24-25 April 2021
<http://www.sinasidai-jambi2021.com>

CALL FOR PAPER
Deadline Abstract Submission 01 April 2021

E-POSTER PRESENTATION LOUNGE
24 - 25 April 2021

MORE INFORMATION +62 819-88-2080

TANGGAL PENTING

- Batas akhir penyampaian Abstrak: 01 APRIL 2021
- Batas akhir penyampaian Karya Foto: 01 APRIL 2021
- Batas akhir registrasi Workshop Online: 15 APRIL 2021
- Batas akhir registrasi SINAS Online: 20 APRIL 2021

UNDUH ANNOUNCEMENT

REGISTRASI ONLINE

Logo of Universitas Jember and other partner institutions.

"Counting Down to 2030: Strengthening Capacity to Reduce Child Mortality and Improving Routine Pediatric Care"



Jambi IPS Chapter
In collaboration with
Indonesian Pediatric Society
Working Groups:
Neonatology
Gastro-Hepatology
Hematology-Oncology
Allergy-Immunology

CERTIFICATE OF APPRECIATION E-POSTER PRESENTATION

This certificate is awarded to

Monica Bethari Primanesa

With The Topic

PERDARAHAN SETELAH SIRKUMSISI KARENA HEMOFILIA YANG TIDAK TERDIAGNOSIS: LAPORAN KASUS

For His/Her Excellence in Free Paper E-Poster Presentation during



"Counting Down to 2030: Strengthening Capacity to Reduce Child Mortality & Improving Routine Pediatric Care"

Saturday – Sunday, 24-25 April 2021


<http://www.sinasidai.jambi2021.com>

as a witness whereof the said Society has caused the Certificate to be signed herewith affixed on the date


President
Indonesian Pediatric Society

Chairman
Jambi Chapter – Indonesian Pediatric Society

Chairman
SINAS & WORKSHOP IDAI JAMBI 2021


Prof. DR. Dr. Aman B. Pulungan,
Sp.A(K), FAAP, FRCPI(Hon)


DR. Dr. Mustarim, Sp.A(K), M.SI.Med


Dr. Agustinus William, Sp.A, M.Kes

Post circumcision bleeding due to undiagnosed hemophilia : a case report

Monica Bethari Primanesa¹, M. Ali Shodikin²

¹General Practitioner, ²Pediatrician RSD dr. Soebandi Jember / Faculty of Medicine Jember University

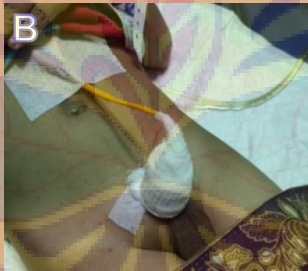
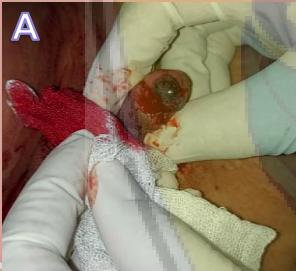SINAS IDAI Jambi, April 24th-25th 2021

Background

Hemophilia is an X-linked recessive bleeding disorder caused by the deficiency of coagulation factors VIII, IX, or XI. In Indonesia, it is estimated that there are 20,000 hemophiliacs out of 270 million population. In about 20% of cases no family history is found, but known when there is spontaneous bleeding that occurs after trauma/surgery. The objective of this study is to describe case of post circumcision bleeding due to undiagnosed hemophilia in primary health care facility.

Case Report

A 5 years old child experienced bleeding seeps for 16 days from circumcision wound performed in primary health care facility. After reoperated in the hospital, the seeps had stopped for a day then seeped again, therefore the patient admitted for third times. There were no history of previous spontaneous bleeding, no family history of bleeding disorders. Physical examination revealed spontaneous bleeding from the circumcision wound (fig. A). Complete blood count showed normal result and prolonged APTT with normal PTT. The patient received 125 mg tranexamic acid injection three times a day and 500 IU of factor VIII replacement for 2 days. Performed an insertion of 6 Fr urinary catheter, then treated the circumcision wound with tulle dressings, gauze, bandaged with an elastic fixation bandage toward umbilical (fig. B). After 3 days of hospitalization, the spontaneous bleeding had stopped and the patient discharged (fig. C).



Discussion

Diagnosis of hemophilia in this patient was based on prolonged APTT with normal PTT. Post circumcision bleeding was the manifestation of 9% hemophiliacs when they first time diagnosed², therefore rarely considered as hemophilia by medical professional in primary health care facilities moreover when there were no abnormality bleeding history to this patient or family.

Before performing a surgery, screening questions should be performed regarding previous bleeding history of the patients and bleeding disorder history of their families as a precaution. If there were a history, the patient should be referred to further health care facilities.

Conclusion: Post circumcision bleeding should be considered as hemophilia and the patient should get appropriate treatment immediately.

Parameters	Result
Hb	10.4 gr/dL
WBC	8.1 x 101/L
Hct	30.7%
Diff Count	-/-/68/26/6
Platelets	413 x 101/L
PTT	11.4 seconds
APTT	92.0 seconds

References:

1. Singh, M., Gupta, L., et al. (2020). Hemophilia in children: a clinico-epidemiological profile and review. *Pediatric Review: International Journal of Pediatric Research*, 7(2), 66-72. https://doi.org/10.17511/ijpr.2020.i02_04
2. Swary, A. D. K., Andarsini, M. R., & Hajat, A. (2019). Characteristic of Hemophilia A Patients in Initial Diagnosis in Dr. Soetomo General Hospital Surabaya. *Biomolecular and Health Science Journal*, 2(1), 9-12.
3. Bertamino, M., Riccardi, F., et al. (2017). Hemophilia care in the pediatric age. *Journal of clinical medicine*, 6(5), 54.