

**KARYA ILMIAH:
SEMINAR INTERNASIONAL**

Late Presentation of Enterocutaneous Fistula

dr. Supangat M.Kes., Ph.D Sp.BA

NIP. 197304241999031002

- Tenaga Pengajar Bagian Paraklinik
Fakultas Kedokteran Universitas Jember

KEMENTERIAN PENDIDIKAN DAN KEBUDAYAAN

UNIVERSITAS JEMBER



Karya Ilmiah Dipresentasikan dalam Seminar Internasional

:International Colorectal Web Meeting , *June 18,2020* W. H. Hendren

Foundation for Pediatric Surgery & Urology in collaboration with

American Pediatric surgical association & Society for Pediatric Urology

International Colorectal Web Meeting: June 2020

Patient Cases

Video Summary of Cases Presented

(<https://www.hendrenproject.org/content/video-summary-international-colorectal-web-meeting-june-2020>)

Case 1. Late Presentation of Enterocutaneous Fistula

(<https://www.hendrenproject.org/content/late-presentation-enterocutaneous-fistula-0>)

Supangat, M.D.; and Henggar Allest Pratama, M.D.; *Dr. Soebandi General Hospital, Faculty of Medicine, University of Jember, East Java, Indonesia*

Case 2. Complex Anorectal Malformation

(<https://www.hendrenproject.org/content/complex-anorectal-malformation-1>)

Luis Mauricio Figueroa Gutiérrez, M.D.; Andrés Felipe Marín Giraldo, M.D.; Juan Felipe Osorno Moncayo, M.D.; Jorge Alexander Solarte Henao, M.D.; *Universidad del Valle, Cali Colombia*

Case 3. Two-Year-Old Male Referred Because of Perianal Condyloma

Acuminatum (<https://www.hendrenproject.org/content/two-year-old-male-referred-because-perianal-condyloma-acuminatum>)

Related Links

About the International Colorectal Web Meetings
(/node/1296)

Submit a Patient Case
(/node/1470)

How To Attend the Web Meetings
(/node/1287)

Recent Web Meetings
(/node/1543)

Future Web Meetings
(/node/1384)

Karla Santos-Jasso, M.D., M.Sc., Ph.D.; and Rossy Angelica Quimbert Montes, M.D.; *National Institute of Pediatrics, Mexico City, Mexico*

THP Colorectal
Surgery Center
(/node/1054)

Case 4. 14-Month-Old Female Born with Cloaca

(<https://www.hendrenproject.org/content/14-month-old-female-born-cloaca>)

Andrea Bischoff, M.D.; *Assistant Director, International Center for Colorectal and Urogenital Care, Children's Hospital Colorado, Aurora, CO*

Case 5. 15-Month-Old Male Patient with Late Diagnosis of

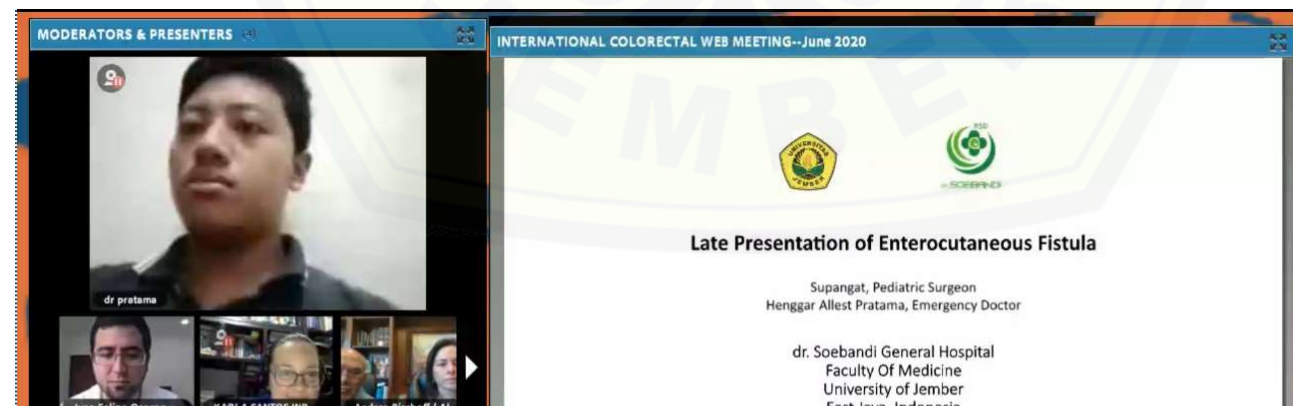Hirschsprung Disease (<https://www.hendrenproject.org/content/15-month-old-male-patient-late-diagnosis-hirschsprung-disease>)

Andrea Bischoff, M.D.; *Assistant Director, International Center for Colorectal and Urogenital Care, Children's Hospital Colorado, Aurora, CO*

Watch an *Interactive Video* of the June 2020 International Colorectal Web Meeting Organized by Slides

(<https://hendrenproject.adobeconnect.com/p72kbceidfcw/>)

Web Meeting Video



The screenshot shows a Zoom meeting sidebar with three main sections:

- IMPORTANT WEB LINKS ON THP:** Lists 'The Hendren Project', 'COVID-19 Resources for Pediatric Surgeons & Urologists', 'International Colorectal Web Meeting', and 'THP Webinar Series'. It includes a search bar labeled 'Browse To'.
- COMMENTS & QUESTIONS ABOUT THE CASE (Everyone):** Contains a list of comments from participants, including: 'Andrea Bischoff / Alberto Pena: Here are the countries I have: Indonesia, Colombia, Mexico, Cameroon, Bangladesh, Bahrain, Pakistan, Spain, Brazil, Romania, Argentina', 'Manuela Rodriguez Cortés: Good morning for everybody, we are connecting from Colombia supangat: jember_Indonesia', 'Vladimir Novozhilov: Russia', 'Lisa VanHouwelingen: Canada!', 'Emmanuel Towu: Hello from the UK', and 'Dr Sarra Nabti: bikini reste'.
- ATTENDEES (50):** Shows a list of participants categorized into 'Hosts (1)', 'Presenters (4)', and 'Participants (45)'. The presenters listed are 'Andrea Bischoff / Alberto Pena', 'dr pratama', 'Juan Felipe Osorno Moncayo', and 'KARLA SANTOS INP MEXICO'.

00:00 00:00

Rate This Presentation:

Your rating: None Average: 5 (1 vote)

[Terms of Use \(/node/398\)](/node/398) | [Privacy Policy \(/node/397\)](/node/397) | [End User Agreement \(/node/399\)](/node/399)

Copyright © 2020 W. H. Hendren Education Foundation for Pediatric Surgery and Urology

Certificate of Presentation

W. H. Hendren Education Foundation for
Pediatric Surgery & Urology

hereby certifies that

Supangat, M.D., M.Sc., Ph.D., *Pediatric Surgeon*

Henggar Allest Pratama, M.D.

Dr. Soebandi General Hospital, Faculty of Medicine, University of Jember, East Java, Indonesia

presented the following patient case:

Late Presentation of Enterocutaneous Fistula

during the

International Colorectal Web Meeting

June 18, 2020



supangat Doctor <drsupangat@unej.ac.id>

Important Information Regarding Your Case Presentation Tomorrow, June 18

1 message

Ray Everngam <ray@hendrenproject.org>

Thu, Jun 18, 2020 at 12:33 AM

To: dokter supangat Kedokteran <drsupangat@unej.ac.id>, Henggar Allest Pratama <henggarap@gmail.com>

Dear Dr. Supangat and Dr. Pratama:

We are honored that you will be presenting a patient case at the International Colorectal Web Meeting tomorrow, Thursday, June 18, 2020. Here is important information regarding your Patient Case Presentation:

YOUR PRESENTATION

Your presentation will be Case #1.

STARTING TIME AND DAY**Thursday, June 18, 2020, 10:00 am ET (16:00 GMT/UTC) / 9:00 am CT / 8:00 am MT / 7:00 am PT [9:00 pm (EAST JAVA INDONESIA)]. Please log into the web meeting room (using the instructions below) at 8:40 pm your time on Thursday. We will watch for you!**

Please follow these instructions to access the web meeting room for your case presentation:

Step 1. New Link to the Web Meeting**Step 2.** Select "Guest"**Step 3.** Enter your name**Step 4.** Select "Enter" and you will be taken to the online web meeting room. When I see that you have arrived, I will make you a Presenter and then you can set up your webcam and microphone.

We look forward to your presentation tomorrow!

Please let me know if you have any questions.

Ray

Raymond L. Everngam
Executive Director
The Hendren Project
www.hendrenproject.org
717-579-6115



Join us on Twitter!
[@hendrenproject](https://twitter.com/hendrenproject)



Late Presentation of Enterocutaneous Fistula

Supangat, M.D.

Henggar Allest Pratama, M.D.

Dr. Soebandi General Hospital, Faculty of Medicine, University of Jember, East Java, Indonesia

Summary Slides:

Late Presentation of Enterocutaneous Fistula

(https://www.hendrenproject.org/sites/default/files/ICWM052020C4_0.pdf)

Patient Case Discussion

Related Links

About the International Colorectal Web Meetings
(/node/1296)

Submit a Patient Case
(/node/1470)


How To Attend the Web Meetings
(/node/1287)

Recent Web Meetings
(/node/1543)

Future Web Meetings
(/node/1384)

The screenshot shows a webinar interface with three main sections:

- Left Panel:** "The Hendren Project", "COVID-19 Resources for Pediatric Surgeons & Urologists", "International Colorectal Web Meeting", "THP Webinar Series".
- Center Panel (COMMENTS & QUESTIONS ABOUT THE CASE):**
 - Andrea Bischoff / Alberto Pena: Here are the countries I have: Indonesia, Colombia, Mexico, Cameroon, Bangladesh, Bahrain, Pakistan, Spain, Brazil, Romania, Argentina
 - Manuela Rodriguez Cortés: Good morning for everybody, we are connecting from Colombia supangat: jember_indonesia
 - Vladimir Novozhilov: Russia
 - Lisa VanHouwelingen: Canada!
 - Emmanuel Towu: Hello from the UK
 - Dr Sarra Nabti: bikini reste
- Right Panel (ATTENDEES):**
 - Hosts (1): THE HENDREN PROJECT--Ray Everngam, dr prat...
 - Presenters (4): Andrea Bischoff / Alberto Pena, dr pratama, Juan Felipe Osorno Moncayo, KARLA SANTOS INP MEXICO
 - Participants (45)



Rate This Presentation:

Your rating: None No votes yet

THP Source:

International Colorectal Web Meetings (/webinar/international-colorectal-web-meetings)

Key Words:

- Male Patient (/tags/male-patient)
- Enterocutaneous Fistula (/tags/enterocutaneous-fistula)
- Meconium (/tags/meconium)

[Terms of Use \(/node/398\)](/node/398) | [Privacy Policy \(/node/397\)](/node/397) | [End User Agreement \(/node/399\)](/node/399)

Copyright © 2020 W. H. Hendren Education Foundation for Pediatric Surgery and Urology



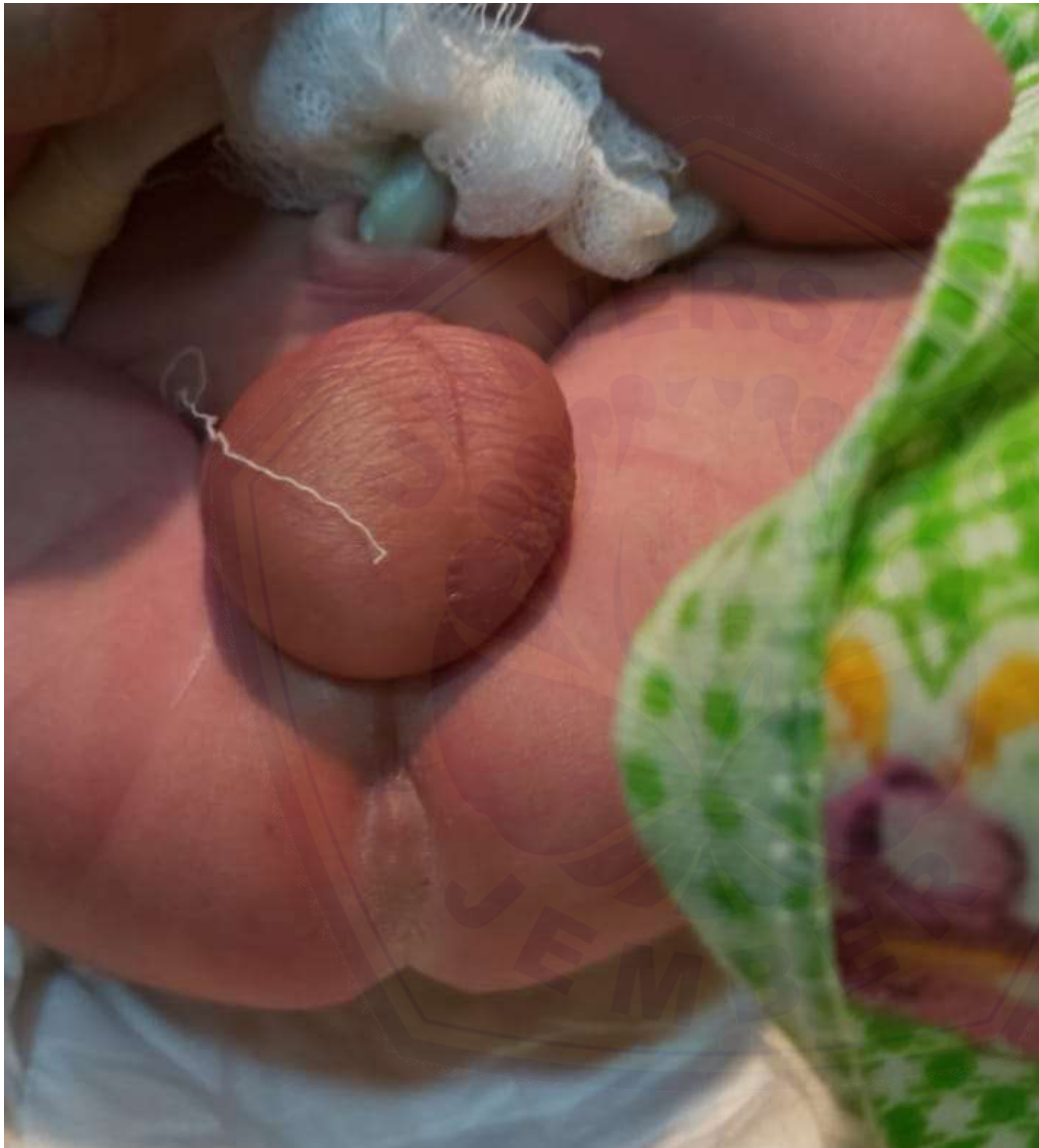Late Presentation of Enterocutaneous Fistula

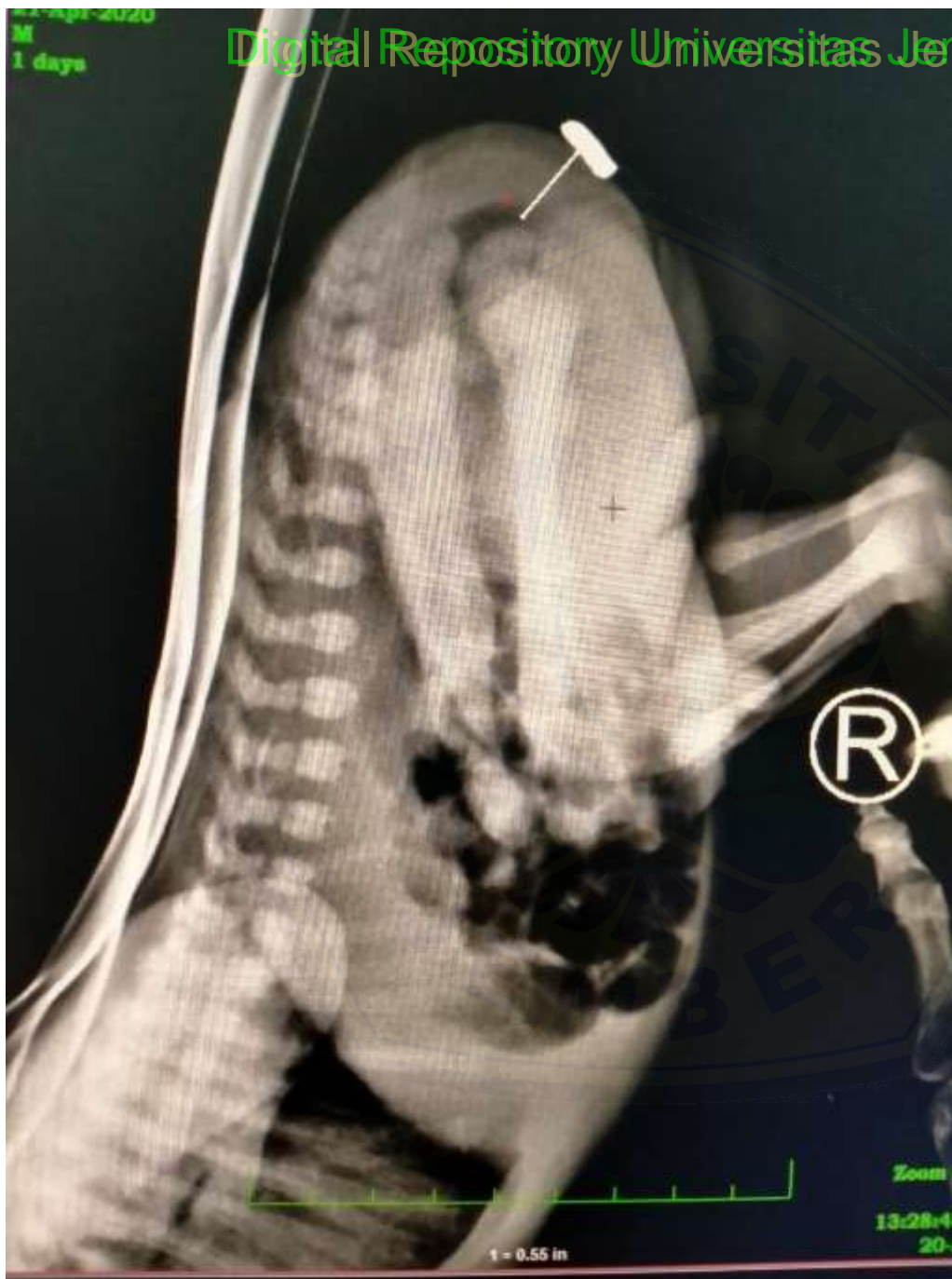Supangat, Pediatric Surgeon
Henggar Allest Pratama, Emergency Doctor

dr. Soebandi General Hospital
Faculty Of Medicine
University of Jember
East Java, Indonesia

Background

- A one-day-old male baby, born by caesarean section to a gravida 2 para 1 abortus 0, at 39 gestational weeks, 2550 grams, was taken to Emergency Department Soebandi Hospital.
- No anal opening was present, no fistula identified at first impression





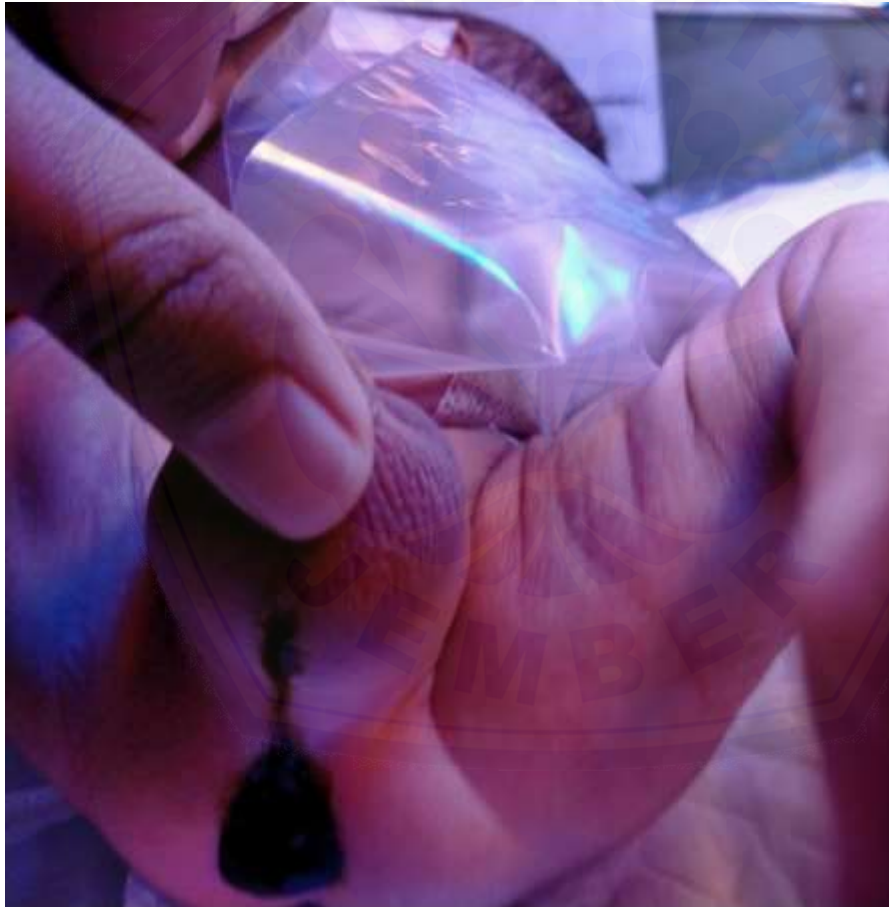The distance between anal hole and distal atresia was 0.55 inch (1.4 cm)

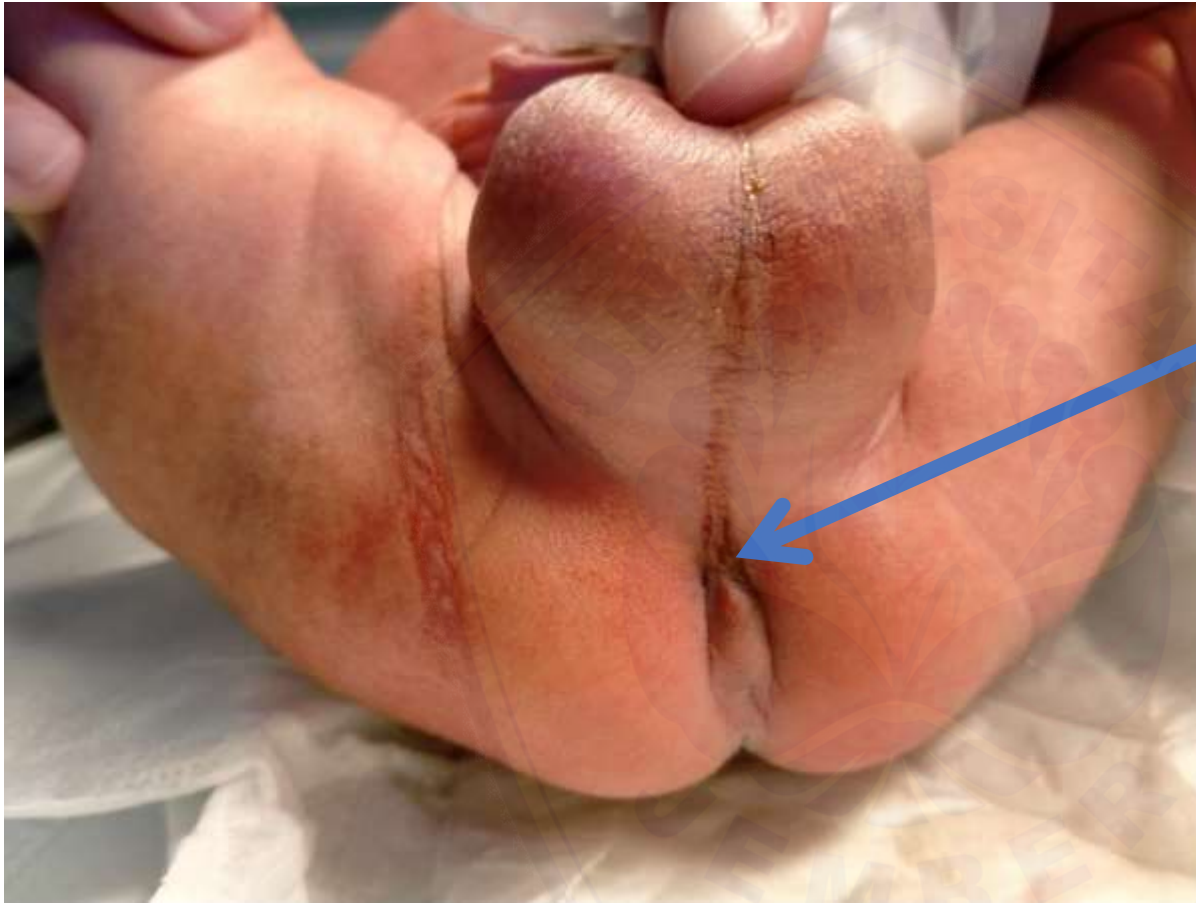Treatment

- NPO
- Orogastric tube decompression
- Fluid resuscitation
- Colostomy opening

Finding

- Two days after Colostomy, we found an enterocutaneous fistula present with meconium





Fistula right site

Result

- Patient could perform defecation from anus adequately with minimal production of stoma and no post-operative complication.

Discussion

- Have you found a late presentation of enterocutaneous fistula before?
- Should we have to waited for colostomy opening in a case of anorectal malformation? If yes, what time we should have waited?
- How to predict the distance between distal rectum and anal impression? Sometimes the prediction of X-Ray is not accurate.



Thank You