

**KARYA ILMIAH:
SEMINAR INTERNASIONAL**

*5-Day-Old Female Patient with
Stooling from Anus*

dr. Supangat M.Kes., Ph.D Sp.BA

NIP. 197304241999031002

- Tenaga Pengajar Bagian Paraklinik
Fakultas Kedokteran Universitas Jember

KEMENTERIAN PENDIDIKAN DAN KEBUDAYAAN

UNIVERSITAS JEMBER



Karya Ilmiah Dipresentasikan dalam Seminar Internasional

:International Colorectal Web Meeting august 29, 2019 W. H. Hendren

Foundation for Pediatric Surgery & Urology in collaboration with

American Pediatric surgical association & Society for Pediatric Urology

International Colorectal Web Meeting: August 2019

Patient Cases

Video Summary of Cases Presented (</case/video-summary-international-colorectal-web-meeting-august-2019>)

Case 1. Five-Day-Old Female Patient with Stooling from Anus

(</content/five-day-old-female-patient-stooling-anus>)

Supangat, M.D., and Azka Darajat, Clinical Student, *Dr. Soebandi General Hospital, Faculty of Medicine, University of Jember, East Java, Indonesia*

Case 2. Recto-urinary Fistula Following a Transanal Proximal

Rectosigmoidectomy (</content/recto-urinary-fistula-following-transanal-proximal-rectosigmoidectomy>)

Sarra Aggoun, M.D., *CHU Sétief Hospital, Sétief, Algeria*

Case 3. Cloaca (</content/cloaca-0>)

Fernando Heinen, M.D., *Buenos Aires, Argentina*

Case 4. Seven-Year-Old Female Patient Adopted from China with an Anorectal Malformation (</content/seven-year-old-female-patient-adopted-china-anorectal-malformation>)

Andrea Bischoff, M.D., *International Center for Colorectal and Urogenital Care, Children's Hospital Colorado, Aurora, CO USA*

Related Links

About the International Colorectal Web Meetings (</node/1296>)

Submit a Patient Case (</node/1470>)

How To Attend the Web Meetings (</node/1287>)

Recent Web Meetings (</node/1543>)

Future Web Meetings (</node/1384>)

Watch an *Interactive Video* of the August 2019 International Colorectal Web Meeting Organized by Slides
(<https://hendrenproject.adobeconnect.com/pkow6ypo9q4m/>)

THP Colorectal Surgery Center
(/node/1054)

Web Meeting Video

Presenters (4)

TODAY'S INTERNATIONAL COLORECTAL WEB MEETING--August 2019

Welcome to the International Colorectal Web Meeting

Four Challenging ARM Patient Cases

Presenters:
Supangat, M.D.
Azka Darajat, M.D.
Sarra Aggoun, M.D.
Fernando Heinen, M.D.
Andrea Bischoff, M.D.

The Hendren Project
Your Global Networked Community for Pediatric Surgery & Urology

INTERNATIONAL CENTER FOR COLORECTAL AND UROGENITAL CARE

Comments & Questions (Everyone)

Jackelyne Alvarado Zelada: Good morning Andrea. Un gusto verte. Jacky from Lima Peru
Dra. Cinthia Lorena Euceda: hello buen dia desde Honduras
Yuri: Hello from Russia
THE HENDREN PROJECT--RAY EVERNGAM: GREETINGS TO RUSSIA!
----- (08/29/2019 09:57) -----
andrea.bischoff@childrenscolorado.org: We will start in 3 minutes
THE HENDREN PROJECT--RAY EVERNGAM: WE CANNOT SEE DR. PENA...
THE HENDREN PROJECT--RAY EVERNGAM: MUCH BETTER!!!
----- (08/29/2019 10:00) -----
rene: Hello from Santa Cruz Bolivia. JAPANESE UNIVERSITY HOSPITAL...

Attendees (33)

andrea.bischoff@childrenscolorado.org

Hosts (1)

THE HENDREN PROJECT--RA...

Presenters (4)

andrea.bischoff@childrenscolorado.org

Dr SARRA AGGOUN

Fernando Heinen

supangat

Participants (33)

00:00 00:00

Rate This Presentation:

Your rating: None Average: 5 (1 vote)

[Terms of Use \(/node/398\)](#) | [Privacy Policy \(/node/397\)](#) | [End User Agreement \(/node/399\)](#)

Copyright © 2020 W. H. Hendren Education Foundation for Pediatric Surgery and Urology



Certificate of Presentation

W. H. Hendren Education Foundation for
Pediatric Surgery & Urology

hereby certifies that

Supangat, M.D., M.Sc., Ph.D., *Pediatric Surgeon*
Azka Darajat, *Clinical Student*

Dr. Soebandi General Hospital, Faculty of Medicine, University of Jember, East Java, Indonesia

presented the following patient case:

5-Day-Old Female Patient with Stooling from Anus

during the

International Colorectal Web Meeting

August 29, 2019

Five-Day-Old Female Patient with Stooling from Anus

Supangat, M.D.

Azka Darajat, General Practitioner

Dr. Soebandi General Hospital, Faculty of Medicine, University of Jember, East Java, Indonesia

- **5-d-old female** presents without **history of delayed passage of meconium** and has been **stooling from the anus**.
- She was **born at 38 wk with APGAR score 7-8**.
- On physical exam, **abnormal connection** between the vestibule of the **vagina and the anus**.

Takeaways

- Perineal groove occurs when there is a mucosal lining from the vagina to the anus. It can occur in patients with or without anorectal malformation. This finding is most commonly seen in patients with perineal fistula.
- Hegar dilator can be used to measure the caliber the anus to evaluate if it is a normal size.
- Sacral X-rays (AP and lateral) should be obtained to evaluate if the sacrum is normal.

Related Links

About the International Colorectal Web Meetings (</node/1296>)

Submit a Patient Case (</node/1470>)

How To Attend the Web Meetings (</node/1287>)

Recent Web Meetings (</node/1543>)

Future Web Meetings (</node/1384>)

- For surgical repair, the mucosal lining can be resected and sutured skin to skin.
- Important to evaluate if the vagina is patent.
- If the anus is normal and the patient isn't having bleeding or discharge, the perineal groove can be observed as it will often epithelialize and resolve.

THP Colorectal
Surgery Center
(/node/1054)

Summary Slides:

Five-Day-Old Female Patient with Stooling from Anus
(<https://www.hendrenproject.org/sites/default/files/Case1--Aug2019.pdf>)

Patient Case Discussion

Presenters

andrea.bischoff@childrencolorado....

Fernando Heinen

supangat

TODAY'S INTERNATIONAL COLORECTAL WEB MEETING--August 2019

UNIVERSITAS JEMBER SOEPANDI KEMENDIS RI

Case #1

Supangat, Pediatric Surgeon
Azka Darajat, Clinical Clerkship Student

dr. Soebandi General Hospita
Faculty Of Medicine
University of Jember
East Java, Indonesia

Comments & Questions

Dra. Cinthia Lorena Euceda: hello buen dia desde Honduras

Yuri: Hello from Russia

THE HENDREN PROJECT--RAY EVERNGAM: GREETINGS TO RUSSIA!
----- (08/29/2019 09:57) -----

andrea.bischoff@childrencolorado.org: We will start in 3 minutes

THE HENDREN PROJECT--RAY EVERNGAM: WE CANNOT SEE DR. PENNA...

THE HENDREN PROJECT--RAY EVERNGAM: MUCH BETTER!!!
----- (08/29/2019 10:00) -----

rene: Hello from Santa Cruz Bolivia. JAPANESE UNIVERSITY HOSPITAL....

Attendees

supangat

Hosts (1)


THE HENDREN PROJECT--RA...

Presenters (4)

andrea.bischoff@childrenc...

Dr SARRA AGGOUN

Fernando Heinen



Rate This Presentation:

Your rating: None Average: 5 (1 vote)

THP Source:

International Colorectal Web Meetings (/webinar/international-colorectal-web-meetings)

Key Words:

Female Patient (/tags/female-patient-0)

Spontaneous Delivery (/tags/spontaneous-delivery)

Anus Location (/tags/anus-location)

Vestibulum (/tags/vestibulum)

[Terms of Use \(/node/398\)](/node/398) | [Privacy Policy \(/node/397\)](/node/397) | [End User Agreement \(/node/399\)](/node/399)

Copyright © 2020 W. H. Hendren Education Foundation for Pediatric Surgery and Urology



Case #1

Supangat, Pediatric Surgeon
Azka Darajat, Clinical Clerkship Student

dr. Soebandi General Hospital
Faculty Of Medicine
University of Jember
East Java, Indonesia

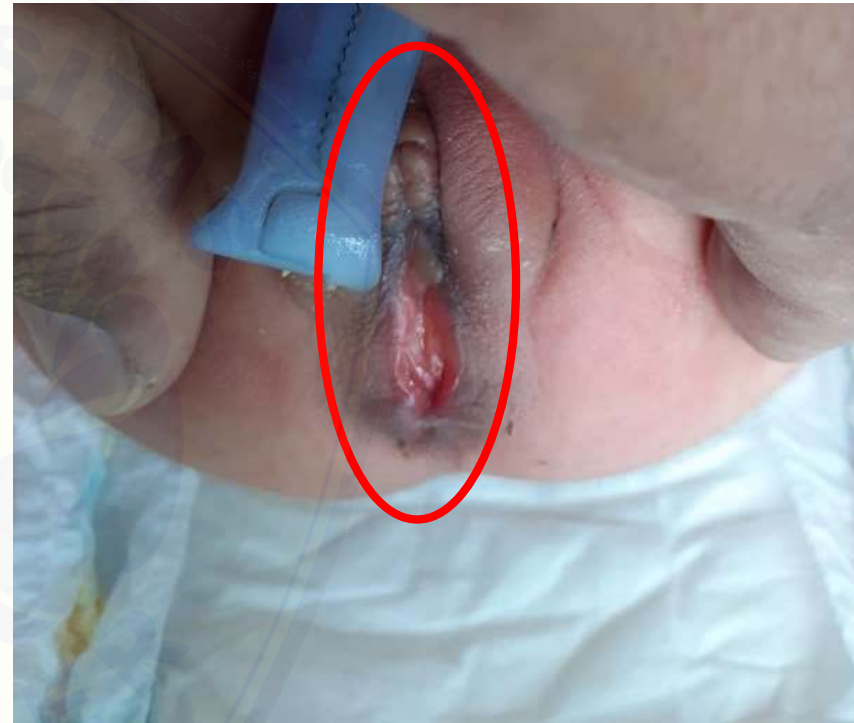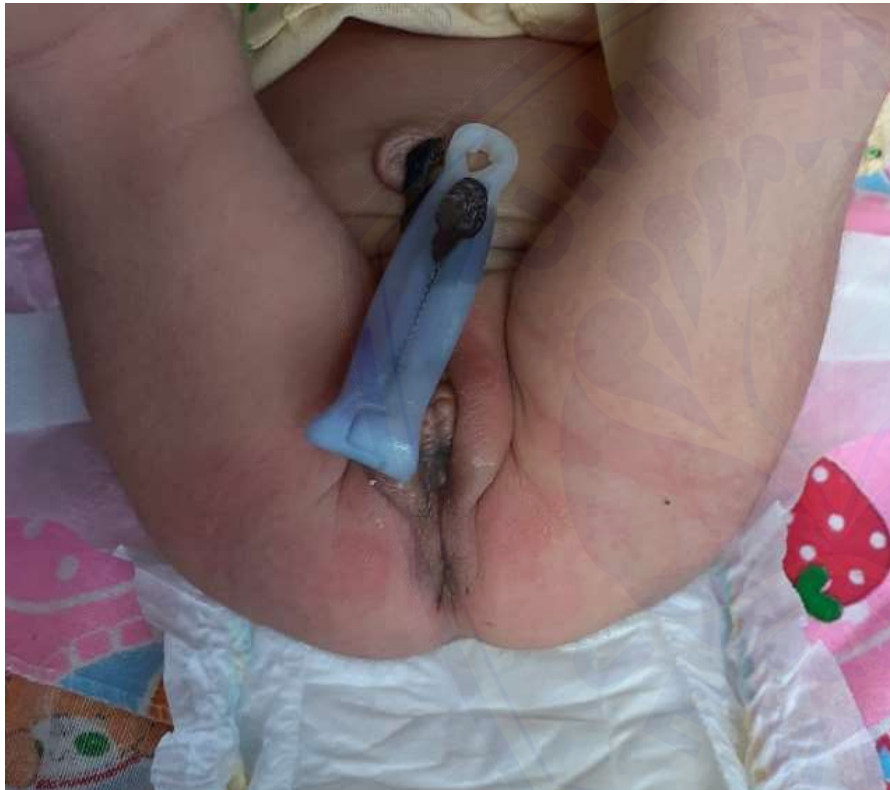Case Presentation

- 5-day-old female baby
- 38 weeks gestation
- Spontaneous delivery
- APGAR Score 7-8
- No delayed meconium passage. Stooling from anus.

Physical Examination


- Abnormal connection between the vestibulum and anus

Picture



Is the anus in the right spot?

1. Yes
2. No
3. I don't know



What should we do with the connection between the anus and the vestibulum?

1. Nothing, just observe
2. Resect the mucosal lining and suture skin to skin
3. I don't know



Thank You