



Contents lists available at ScienceDirect

Journal of Pediatric Surgery Case Reports

journal homepage: <http://www.elsevier.com/locate/epsc>

Jaboulay gastroduodenostomy for pyloric obstruction after corrosive ingestion

Supangat^{a,*}, Muhammad Yuda Nugraha^b, Peter Lundqvist^c^a Division of Pediatric Surgery, Dr. Soebandi Regional Hospital-Faculty of Medicine, Jember University, East Java, Indonesia^b Faculty of Medicine, Jember University, East Java, Indonesia^c Swedish University of Agricultural Sciences, Sweden

ARTICLE INFO

Keywords:
Corrosive
Obstruction
Pyloric

ABSTRACT

Strong acid accidental ingestion is a common case in rural society and children. The effect of strong acids may cause injuries of the gastrointestinal tract. We present a case obstruction in the distal part of gastric after accidental sulfuric acid ingestion in children. Sulfuric acid ingestion is potential in children since its commercial product physical appearance looks like drink water. Then the patient was diagnosed with pyloric obstruction after barium meal examination and was treated using Jaboulay gastroduodenostomy procedure.

1. Introduction

Accidental or intentional ingestion of corrosive agents is very common in rural society. Strong acids are commonly presented as household materials. Strong acid accidental ingestion is more common in children than adults. The common effect of strong acids may cause injuries in the distal part of the esophagus and stomach [1,2]. Obstruction in distal part of gastric that is caused by corrosive ingestion is very rare, approximately as little as 3.8% of all the cases of corrosive ingestion, as reported in literature [3]. We present a case obstruction in distal part of gastric after corrosive ingestion in children and unusual procedure to treat pyloric obstruction.

2. Case report

A 7 years old male patient was admitted to emergency department after getting multiple episodes of vomiting several hours after having meals. The vomitus consisted of only the food contents. There was no any difficulty in swallowing solids or liquids. He had history of hydrogen sulphate (accu water) ingestion 30 days earlier. On abdominal examination there was gastric distension and no peristaltic sound during auscultation. Based on anamnesis and examination findings, there was obstruction in the distal of gastric. Further examination, we did abdominal radiography examination of whole abdomen. Based on barium meal examination, there was total obstruction in pylorus region (Fig. 1).

During surgery, there was obtained a total obstruction of pylorus with sclerotic images along 2 cm with passage to the distal. We used Jaboulay gastroduodenostomy shunting to treat the total obstruction. This procedure makes a shunt between side of the distal part of gastric into the side of duodenum (Fig. 2). There was uneventful during post-operative recovery and the patient was discharged in the several days after surgery.

3. Discussion

Strong acid accidental ingestion commonly happens in developing countries. Most accidental ingestion of strong acid is experienced in children [4]. In this case, the patient is still 7 years old that did accidental ingestion of sulfuric acid or hydrogen sulphate (H₂SO₄). H₂SO₄, well known as accu water, is common household material as electronic supporting device. The accidental ingestion of H₂SO₄ is potential in children since its physical appearance is looks like drink water (Fig. 2).

Strong acid is corrosive agent that leads a coagulation necrosis of the tissue. Then the necrosis tissue will form a tissue scars at the site of injury which further leads to segmental or extensive stricture formation [5]. The degree of tissue injury is determined by concentration, amount, duration of contact, and presence of food in the stomach [6]. Large amount of strong acid may induce perforation of empty stomach within 24–48 hours. The mostly affected structure of the empty stomach is pylorus. Strong acid will induce gastric muscle spasm that increase of acid volume in the pyloric region. Long duration contact of acid to the

* Corresponding author. Tel.: +62 0331 377877

E-mail addresses: drsupangat@unej.ac.id (Supangat), yuda.noegraha@gmail.com (M.Y. Nugraha), Peter.Lundqvist@slu.se (P. Lundqvist).

<https://doi.org/10.1016/j.epsc.2020.101672>

Received 11 September 2020; Received in revised form 24 September 2020; Accepted 2 October 2020

Available online 5 October 2020

2213-5766/© 2020 The Authors.

Published by Elsevier Inc.

This is an open access article under the CC BY-NC-ND license

(<http://creativecommons.org/licenses/by-nc-nd/4.0/>).

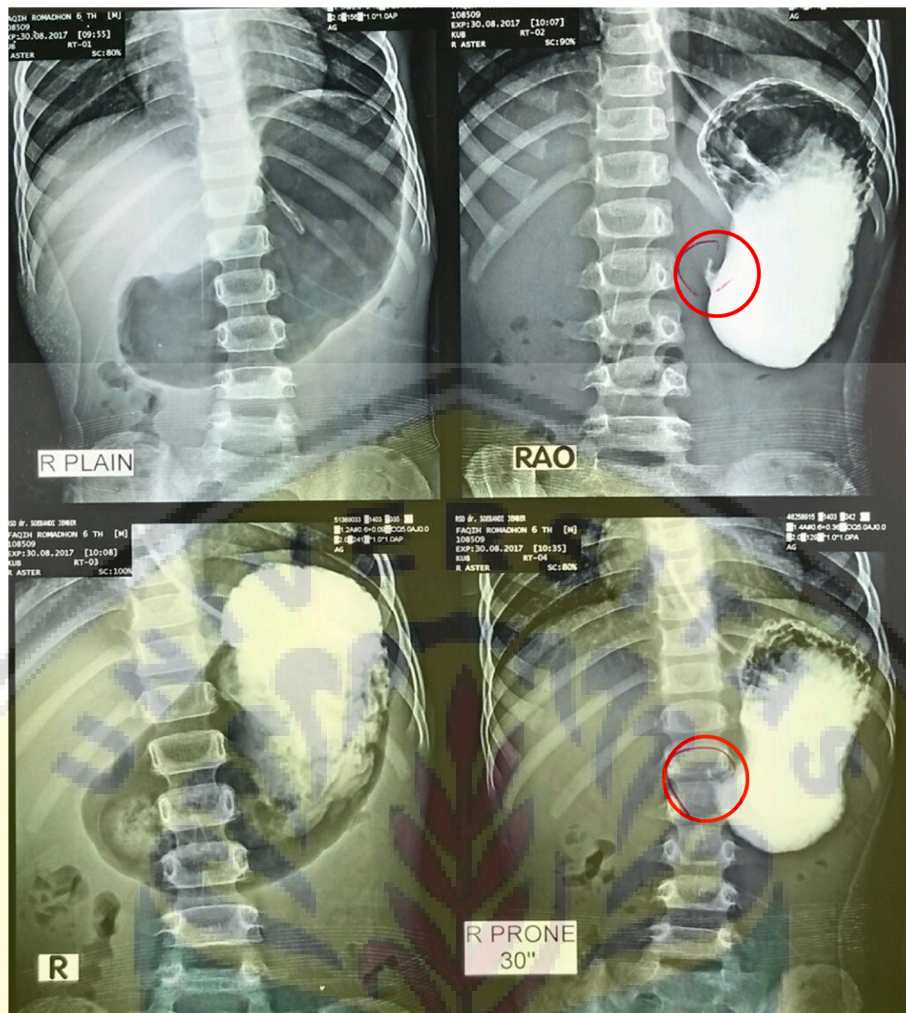


Fig. 1. Abdominal radiography examination.



Fig. 2. A. Accu water (H_2SO_4), B. Drink water.

pyloric mucous will induce progressive tissue inflammation that indirectly will cause pyloric obstruction. The pyloric obstruction will appear commonly 4–6 weeks after ingestion [7]. In this case, the pyloric obstruction occurred 30 days after ingestion.

The main acute symptom of pyloric obstruction is vomiting in 2–3 hours after taking food. The untreated vomiting may present dehydrated and low electrolyte level. While chronic obstruction may induce malnutrition and weight loss [8]. In this case, the patient was admitted

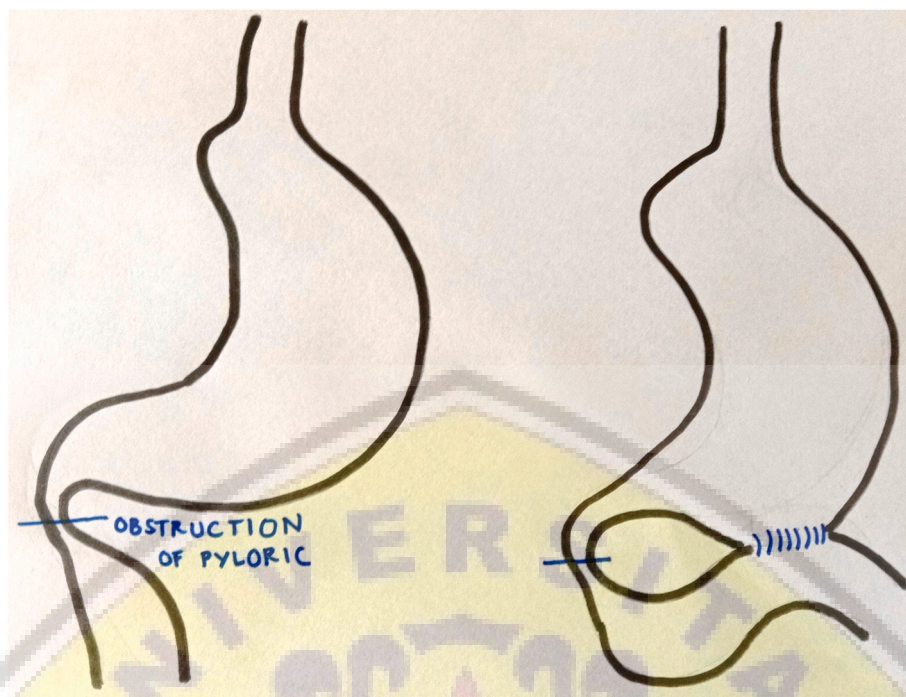


Fig. 3. Jaboulay gastroduodenostomy procedure.

to emergency department after getting multiple episodes of vomiting several hours after having meals. There was no dehydration condition.

The initial treatment of strong acid ingestion usually can be done by conservative treatment. The principle of treatment is to maintain the acidity in the stomach and keep the patient from dehydration. Conservative management usually uses supportive treatment likes proton pump inhibitor (PPI) and intravenous fluids therapy. Then patient should be observed for any development features of esophageal stricture or gastric outlet obstruction. The main choice observation for making the diagnosis is upper gastrointestinal endoscopy, while in the rural hospital can be used barium meal or contrast CT scan of abdomen [9]. Gastric outlet obstruction like pyloric obstruction feature should be treated by definitive surgery. The types of surgery which can be done are pyloroplasty, gastrojejunostomy and gastroduodenostomy surgery. But it depends upon the condition of patient, findings at laparotomy as well as surgeon's ability and judgment [10]. In this case, the patient came to emergency department after obstruction sign was appeared. After radiography examination, the patient was treated with Jaboulay gastroduodenostomy procedure (Fig. 3). This procedure has low risk complication for distal gastric reconstruction due to the pyloric was not resected [11]. This procedure can be main choice for distal gastric reconstruction. Then, the patient recovered well post-surgery with no complication (Fig. 3).

4. Conclusion

Strong acid ingestion sequelae can be featured as pyloric obstruction is significant burden in children health. Initial treatment in sudden onset can be effective to minimize the significant complication. In this case, Jaboulay gastroduodenostomy procedure is effective as definitive surgical procedure of pyloric obstruction treatment with very few complications and failures.

Patient consent

An informed consent was obtained from patient's parents for publication.

Funding

No funding or grant support.

Authorship

All authors attest that they meet the current ICMJE criteria for Authorship.

Declaration of competing interest

The authors declare that they have no known competing financial interests or personal relationships that could have appeared to influence the work reported in this paper.

Acknowledgements

There is no acknowledgement in this article.

References

- [1] Kikendall JW. Caustic ingestion injuries. *Gastroenterol Clin N Am* 1991;20:847–57.
- [2] Hugh TB, Kelly MD. Corrosive ingestion and the surgeon. *J Am Coll Surg* 1999;189: 508–22.
- [3] Ciftci AO, Senocak ME, Buyukpamukcu N, Hiçsönmez A. Gastric outlet obstruction due to corrosive ingestion: incidence and outcome. *Pediatr Surg Int* 1999;15: 88–91.
- [4] Hall AH, Jacquemin D, Henny D, Mathieu L, Josset P, Meyer B. Corrosive substances ingestion: a review. *Crit Rev Toxicol* 2019;49(8):637–69.
- [5] Chibishev A, Simonovska N, Shikole A. Post-corrosive injuries of upper gastrointestinal tract. *Prilozi* 2010;31:297–316.
- [6] Lakshmi CP, Vijayhari R, Kate V, Ananthakrishnan N. A hospital-based epidemiological study of corrosive alimentary injuries with particular reference to the Indian experience. *Natl Med J India* 2013;26:31–6.
- [7] Hsu CP, Chen CY, Hsu NY, Hsia JY. Surgical treatment and its longterm result for caustic-induced prepyloric obstruction. *Eur J Surg* 1997;163:275–9.
- [8] Faridi S. Suicidal acid ingestion leading to isolated pyloric stenosis without esophageal involvement: report of 2 cases. *Surgical Chronicles* 2016;21:94–6.

- [9] Lowe JE, Graham DY, Boisaubin Jr EV, Lanza FL. Corrosive injury to stomach: the natural history and role of fibro optic endoscopy. *Am J Surg* 1979;137:803-6.
- [10] Ansari MM, Haleem S, Harris SH, Khan R, Zia I, Beg MH. Isolated corrosive pyloric stenosis without oesophageal involvement: an experience of 21 years. *Arab J Gastroenterol* 2011;12:94-8.
- [11] Frantzides CT, Carlson MA. Laparoscopic jaboulay gastroduodenostomy for gastric outlet obstruction: a case report. *J Laparoendosc Surg* 1996;6(5):341-4.

