

# **Pesquisa Brasileira em Odontopediatria e Clínica Integrada**



[Home](#) / [Archives](#) / Vol. 23 (2023)

## Vol. 23 (2023)

**Published:** 2023-02-23

### Original Articles

#### Caregivers' Sense of Coherence and Untreated Dental Caries in Children and Adolescents: A Cross-Sectional Study

Monica Gentil Mattos, Ronir Raggio Luiz, Lucianne Cople Maia, Aline de Almeida Neves  
e210099

[PDF](#)

#### Profile of Hospitalizations of Children and Adolescents Victims of Transport Accidents: A Retrospective Study

Naiana Braga da Silva, Taynná Larissa Santos Rodrigues, Ane Polline Lacerda Protasio, Alessandro Leite Cavalcanti  
e210113

[PDF](#)

#### Dimensions of Occlusoproximal Cavitated Carious Lesions as a Cut-Off Point for Restorative Decision in Primary Teeth

Helena Scherer, Cleber Paradzinski Cavalheiro, José Carlos Pettorossi Imparato, Rachel de Oliveira Rocha, Fernanda Ruffo Ortiz, Tathiane Larissa Lenzi  
e220017

[PDF](#)

#### Dental Fear/Anxiety in Children and Child Emotional and Behavioural Problems

Mariana Gonzalez Cademartori, Fernanda Burkert Mathias, Karen Jansen, Marília Leão Goettems  
e210226

[PDF](#)

#### Factors Associated with the Intake of Ultra-Processed Cariogenic Foods by Preschoolers During the COVID-19 Pandemic

Aline Fabris de Araujo Crema, Bruna Letícia Vessoni Menoncin, Sandra Patrícia Crispim, Fabian Calixto Fraiz  
e220080

[PDF](#)

### **Translation and Cross-Cultural Adaptation of the “Child Drawing: Hospital” (CD:H) Scale for Paediatric Dentistry in Brazil**

Natália Baschiroto Custódio, Fernanda Burkert Mathias, Mariana Gonzalez Cademartori, Marília Leão Goettems  
e210229

[PDF](#)

### **Relationship of Dental Caries and Body Mass Index amongst School Children in Hail, Saudi Arabia: A Cross-Sectional Study**

Ali Alsweed, Ahmed Ali AlFawzan, Mohammed Ali Habibullah, Nubesh Khan, Mohamed Tharwat Salama, Prashant Babaji  
e220039

[PDF](#)

### **Variations in Function and Vocal Acoustic Characteristics After Orthognathic Surgery: Preliminary Results**

Mario Palone, Edoardo Mannelli, Elisabetta Pontarolo, Flavia Nardi, Teresa Menegus, Paolo Santoni, Ugo Baciliero  
e210238

[PDF](#)

### **Evaluation of Dental Interns’ Perception and Self-Confidence Levels Regarding Endodontic Treatment”- A Questionnaire Study**

Shambhavi Gogia, Anushtha Jain, Laxmish Mallya, Ramya Shenoy, Swathi Pai  
e210083

[PDF](#)

### **Efficacy of Buccal Infiltration with or without Palatal Injection for Posterior Maxillary Teeth Extraction – A Split-Mouth Randomized Trial**

Abhirup Chatterjee, Srikanth Gadicherla, Sreea Roy, Kalyana-Chakravarthy Pentapati  
e210215

[PDF](#)

### **Accelerating Wound Healing of Traumatic Ulcer with Topical Application of Dental Pulp Mesenchymal Stem Cell Secretome and Robusta Green Coffee Bean Extract Combination in vivo**

Ericko Ichi, Iin Eliana Triwahyuni, Desi Sandra Sari

e210116



### **Effect of Ozonated Water on the Color Stability of Denture Teeth and Heat Polymerized Acrylic Base Resin**

Amirtaher Mirmortazavi, Alireza Chamani, Hossein Bagheri, Abdolrasoul Rangrazi

e210147



### **Quality of Tooth-Whitening Videos Available on YouTube**

Yuanita Lely Rachmawati, Laura Vita Catherine Naibaho, Naufal Rifqi Aulia

e210232



### **Establishing Cephalometric Norms in Primary Dentition Using Comprehensive Craniofacial Growth Analysis – A Digital Cephalometric Study**

Seema Deshmukh, Bhojraj Nandlal

e210180



### **Knowledge, Dental Anxiety, and Patient Expectations During the COVID-19 Pandemic**

Yuanita Lely Rachmawati, Isabela Anjani, Anggiona Dwi Nawang Sasi

e210228



### **Comparison Between Radiographs, White and Fluorescent Images in the Diagnosis and Treatment Decisions for Occlusal Caries: An Ex Vivo Study**

Luciana Pereira da Silva, Luan Ferreira Bastos, Clara Silva Avellar Mascarenhas, Ricardo Tadeu Lopes, Michelle Mikhael Ammari, Luciana Pomarico, Ivete Pomarico Ribeiro de Souza, Maria Augusta Visconti, Aline de Almeida Neves

e210162



## **Systematic Reviews (and Meta-Analysis)**

## Efficacy and Safety of Oral Midazolam Sedation Compared with its Combination with Hydroxyzine Use in Pediatric Dentistry: A Systematic Review

Gustavo Henrique Porto Oliveira, Diogo Gomes Brandão, Fernando José Camello de Lima, Patricia Batista Lopes do Nascimento, Priscylla Gonçalves Correia Leite de Marcelos, Daniela Maria Carvalho Pugliesi, Leopoldo Cosme-Silva, Valdeci Elias dos Santos Júnior

e210213



PDF

## Critical Review

### 3D Bitemark Analysis in Forensic Odontology Utilizing a Smartphone Camera and Open-Source Monoscopic Photogrammetry Surface Scanning

Arofi Kurniawan, An'nisaa Chusida, Haryono Utomo, Maria Istiqomah Marini, Beta Novia Rizky, Beshlina Fitri Widayati Prakoeswa, Janice Hamdani, Rodrigo Salazar-Gamarra, Luciano Lauria Dib, Aspalilah Alias, Mohd. Yusmiaidil Putera Mohd Yusof, Anand Marya

e220087



PDF

## Letters to the Editor

### Technologies on Behalf of the Dentistry Dissemination in Pandemic Times: An Interinstitutional Experience

Lucas Alves da Mota Santana, Marcos Antônio Lima dos Santos, John Nadson Andrade Pinho, Nelmara Sousa-e-Silva, Lucas Celestino Guerzet Ayres, Mark Jon Santana Sabey, Breno Ferreira Barbosa, Gustavo Danilo Nascimento Lima, Graziane Ribeiro Couto, Liciane dos Santos Menezes, Wilton Mitsunari Takeshita, Liane Maciel de Almeida Souza, Cleverson Luciano Trento

e210204



PDF

## Manuscript Submissions and Indexers

Digital Repository Universitas Jember

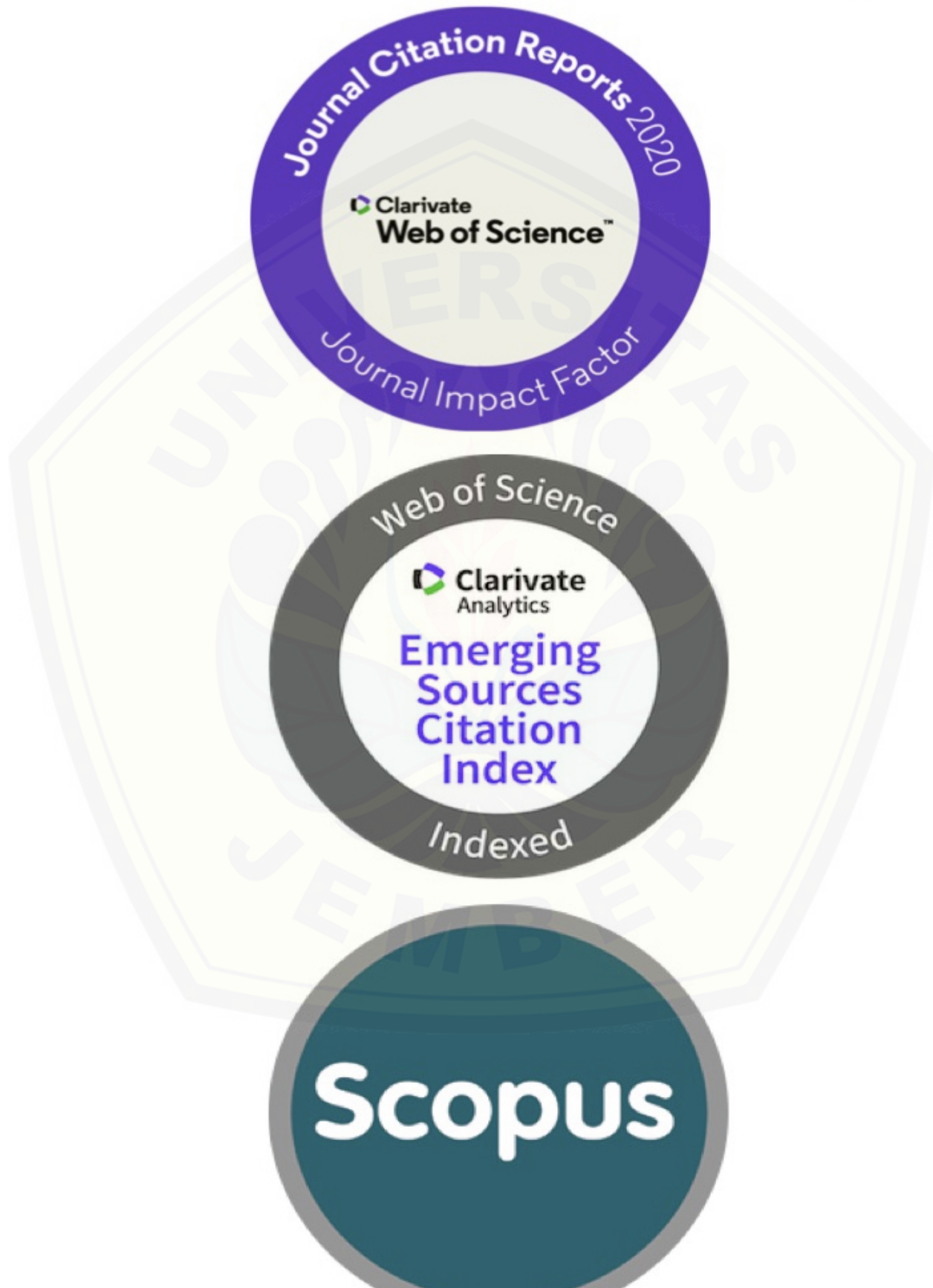
# SCHOLARONE MANUSCRIPTS™

Pesquisa Brasileira em Odontopediatria e Clínica Integrada has moved to ScholarOne Manuscripts, Clarivate Analytics's online submission and peer review tracking system.

[mc04.manuscriptcentral.com/pboci-scielo](https://mc04.manuscriptcentral.com/pboci-scielo)

<https://mc04.manuscriptcentral.com/pboci-scielo>

# Journal Indexing



# Embase®

The SciELO logo features the word "SciELO" in a red, serif font. A black, stylized swoosh with a dot at its end curves over the letters. The logo is centered over a large, faint watermark of the Universitas Jember seal, which includes the text "UNIVERSITAS JEMBER" and a central emblem.

**PBOCI is indexed in the Journal Citation Reports (JCR), Web of Science Emerging Sources Citation Index, SCOPUS, Embase and SciELO.**

**PBOCI IS A MEMBER OF CROSSREF AND ALL THE CONTENT OF ITS JOURNALS ARE LINKED BY DOIS THROUGH CROSSREF.**

Platform &  
workflow by  
**OJS / PKP**



[Home](#) / [Editorial Team](#)

## Editorial Team

### Editors

Alessandro Leite Cavalcanti, Universidade Estadual da Paraíba, Campina Grande, PB, Brazil

Wilton Wilney Nascimento Padilha, Universidade Federal da Paraíba, João Pessoa, PB, Brazil

**Executive Editor:** Ana Maria Gondim Valença, Universidade Federal da Paraíba, João Pessoa, PB, Brazil

### Associated Editors

Alidianne Fábila Cabral Cavalcanti, Universidade Estadual da Paraíba, Campina Grande, PB, Brazil

Burak Buldur, Faculty of Dentistry, Cumhuriyet University, Sivas, Turkey

Catarina Ribeiro Barros de Alencar, Universidade Federal de Campina Grande, Patos, PB, Brazil

Lucianne Cople Maia, Universidade Federal do Rio de Janeiro, Rio de Janeiro, RJ, Brazil

Mohammad Khursheed Alam, College of Dentistry, Al Jouf University, Sakakah Saudi Arabia

Myroslav Goncharuk-Khomyn, Uzhhorod National University, Uzhhorod, Ukraine

Yuri Wanderley Cavalcanti, Universidade Federal da Paraíba, João Pessoa, PB, Brazil

### International Board

Ariel Osvaldo Gómez, Universidad de Buenos Aires, Buenos Aires, Argentina

Ahmad Iqbal, Dental Society Pakistan, Islamabad, Pakistan

B Sivapathasundharam, Meenakshi Ammal Dental College and Hospital, Tamil Nadu, India

## Digital Repository Universitas Jember

Cynthia Yiu, University of Hong Kong, Hong Kong

Chukwudi Ochi Onyeaso, University of Ibadan, Ibadan, Nigeria

Dejan Marković, University of Belgrade, Serbia, Serbia

Febronia Kokulengya Kahabuka, Muhimbili University, Dodoma, Tanzania, United Republic of

Folakemi A Oredugba, University of Lagos, Lagos, Nigeria

Franklin Garcia-Godoy, Nova Southeastern University, Florida, United States

Giuseppe Alessandro Scardina, University of Palermo, Palermo, Italy

Gottfried Schmalz, University of Regensburg, Regensburg, Germany

Hakan Turkkahraman, Suleyman Demirel Universitesi, Isparta, Turkey

Hrvoje Brkic, University of Zagreb, Zagreb, Croatia

Izzet Yavuz, Dicle University Faculty of Dentistry, Diyarbakir, Turkey

Jalil Modaresi, Faculty of Dentistry Yazd, Yazd, Iran, Islamic Republic of

Jaime Portugal, Universidade de Lisboa, Portugal

Juozas Zilinskas, Public Institution "Odontologijos Studija", Kaunas, Lithuania

Kenshi Maki, Kyushu Dental College, Kitakyushu City, Japan

Ljubomir Todorovic, University of Belgrade, Belgrade,

Marc Saadia, Journal of Clinical Pediatric Dentistry, Mexico City, Mexico

Luca Testarelli, Sapienza University of Rome, Rome, Italy ([luca.testarelli@uniroma1.it](mailto:luca.testarelli@uniroma1.it))

Moschos A Papadopoulos, Aristotle University of Thessaloniki, Thessaloniki, Greece

Najla Dar-Odeh, College of Dentistry, Taibah University, Saudi Arabia

Rafael Martín-Granizo López, Universidad Complutense de Madrid, Madrid, Spain

Rita Sarmiento Villena, Universidad Peruana Cayetano Heredia, Lima, Peru

## Digital Repository Universitas Jember

Rodolfo Miralles, Universidad de Chile, Santiago, Chile

Rommie Lucia Merino-Alado, School of Dentistry, Central University of Venezuela, Caracas, Venezuela,  
Bolivarian Republic of

Romulo Luis Cabrini, Universidad de Buenos Aires, Buenos Aires, Argentina

Satyawan G Damle, Nair Hospital Dental College, New Delhi, India

Slavoljub Živković, University of Belgrade, Belgrade,

Vesna Miletic, University of Belgrade, Belgrade,

Vince M Phillips, University of the Western Cape, Cape Town, South Africa

William Murray Thomson, Sir John Walsh Research Institute, Dunedin, New Zealand

### **National Board**

Alessandro Dourado Loguércio, Universidade Estadual de Ponta Grossa, Ponta Grossa, PR, Brazil

Ana Emília Figueiredo de Oliveira, Universidade Federal do Maranhão, São Luís, MA, Brazil

Danyel Elias da Cruz Perez, Universidade Federal de Pernambuco, Recife, PE, Brazil

Denise Stadler Wambier, Universidade Estadual de Ponta Grossa, Ponta Grossa, PR, Brazil

Evandro Piva, Universidade Federal de Pelotas, Pelotas, RS, Brazil

Grace Sampaio Teles, Universidade de Fortaleza, Fortaleza, CE, Brazil

Jefferson Luiz Traebert, Universidade do Sul de Santa Catarina, Tubarão, SC, Brazil

João Luiz Gurgel Calvet Silveira, Fundação Universidade Regional de Blumenau, Blumenau, SC, Brazil

José Antônio Nunes de Mello, Universidade do Estado do Amazonas, Manaus, AM, Brazil

Luciane Ribeiro de Rezende Sucasas da Costa, Universidade Federal de Goiás, Goiânia, GO, Brazil

Lucineide de Melo Santos, Universidade Federal de Alagoas, Maceió, AL, Brazil

## Digital Repository Universitas Jember

Maria Beatriz Duarte Gavião, Universidade Estadual de Campinas, Piracicaba, SP, Brazil

Maria Helena Monteiro de Barros Miotto, Universidade Federal do Espírito Santo, Vitória, ES, Brazil

Maria Letícia Ramos-Jorge, Universidade Federal dos Vales do Jequitinhonha e Mucuri, Diamantina, MG, Brazil

Maria Teresa Botti Rodrigues dos Santos, Universidade Cruzeiro do Sul, São Paulo, SP, Brazil

Mauro Henrique Nogueira Guimarães de Abreu, Universidade Federal de Minas Gerais, Belo Horizonte/MG, Brazil

Paulo Floriani Kramer, Universidade Luterana do Brazil, Canoas, RS, Brazil

Robert Willer Farinazzo Vitral, Universidade Federal de Juiz de Fora, Juiz de Fora, MG, Brazil

Robson Frederico Cunha, Universidade Estadual Paulista, Araçatuba, SP, Brazil

Saul Martins Paiva, Universidade Federal de Minas Gerais, Belo Horizonte, MG, Brazil



Sérgio Adriane Adriane Moura, Universidade Federal do Rio Grande do Norte, Natal, RN, Brazil

Sílvio Issáo Myaki, Universidade Estadual Paulista, São José dos Campos, SP, Brazil

Suzely Adas Saliba Moimaz, Universidade Estadual Paulista, Araçatuba, SP, Brazil

### **Manuscript Submissions and Indexers**

# Accelerating Wound Healing of Traumatic Ulcer with Topical Application of Dental Pulp Mesenchymal Stem Cell Secretome and Robusta Green Coffee Bean Extract Combination *in vivo*

Ericko Ichi<sup>1</sup>, Iin Eliana Triwahyuni<sup>1</sup>, Desi Sandra Sari<sup>1</sup>

<sup>1</sup>Faculty of Dentistry, Jember University of Jember, Jawa Timur, Indonesia.

**Correspondence:** Desi Sandra Sari, Department of Periodontology, Faculty of Dentistry, University of Jember, Kalimantan No 37, Kampus Tegalboto, Jember, Jawa Timur 68121, Indonesia **E-mail:** [desi\\_sari.fkg@unej.ac.id](mailto:desi_sari.fkg@unej.ac.id)

**Academic Editor:** Wilton Wilney Nascimento Padilha

**Received:** 14 June 2021 / **Review:** 21 February 2022 / **Accepted:** 24 May 2022

**How to cite:** Ichi E, Triwahyuni IE, Sari DS. Accelerating wound healing of traumatic ulcer with topical application of dental pulp mesenchymal stem cell secretome and robusta green coffee bean extract combination *in vivo*. *Pesqui Bras Odontopediatria Clín Integr.* 2023; 23:e210116. <https://doi.org/10.1590/pboci.2023.018>

## ABSTRACT

**Objective:** To investigate the ability of a combination dental pulp mesenchymal stem cell secretome (DPMSCS), robusta green coffee bean extract (RGCBE), and Carboxymethylcellulose-Natrium (CMC-Na) in a Wistar rats model of traumatic ulcers. **Material and Methods:** Twenty-eight young, male, healthy Wistar rats (*Rattus norvegicus*) were divided into seven groups randomly: Group K<sub>0</sub>, group K<sub>1-3</sub> (traumatic ulcer rats that received CMC-Na gel for three days), group K<sub>1-7</sub> (traumatic ulcer rats that received CMC-Na gel for seven days), group K<sub>2-3</sub> (traumatic ulcer rats that received RGCBE for three days), group K<sub>2-7</sub> (traumatic ulcer rats that received RGCBE for seven days), group K<sub>3-3</sub> (traumatic ulcer rats that received DPMSCS for three days), and group K<sub>3-7</sub> (traumatic ulcer rats that received DPMSCS for seven days). An ulcer was made with an amalgam stopper on the right buccal mucosa of the rats. DPMSCS 50% gel was applied to the ulcer on the left buccal mucosa. The ulcer diameter was measured on day 3 and day 7. **Results:** There was a significant difference in the diameter of the ulcer, the number of neutrophils, and fibroblasts in the treatment group compared to the control group on day 7. **Conclusion:** A combination of DPMSCS and RGCBE 50% accelerates traumatic ulcer wound healing by lowering ulcer diameter, decreasing neutrophil counts, and increasing fibroblast proliferation *in vivo*.

**Keywords:** Fibroblasts; Neutrophils; Stem Cells; Wound Healing; Medicine.

## Introduction

Injuries are unpredictable events. One of the most common types of wounds is burns. Burns are injuries to the skin or organic surfaces caused by heat or radiation, radioactivity, electricity, or contact with chemicals. According to the World Health Organization (WHO) in 2018, 11 million cases of burns occur every year and often occur in lower-middle-income countries such as Africa and Southeast Asia [1,2]. Most patients with serious burns require prompt emergency treatment to reduce morbidity and mortality. The high fatality rate is not only due to hypovolemic shock and vascular leakage but also to abnormal body responses, including immunosuppression, excessive inflammation, and hypermetabolism. This response can lead to increased infection, sepsis, and multiple organ dysfunction syndrome (MODS), leading to patient death [2].

Therefore, fast and adequate wound closure is needed so as not to cause unwanted events. The wound model made in this study was traumatic ulcer due to burns in Wistar rats. Ulcers are lesions that form due to local damage to the epithelial tissue [3]. Traumatic ulcers are one of the most common lesions on the oral mucosa. These traumatic injuries can occur in the cheek mucosa, labial mucosa, palatal mucosa, and the edge of the tongue. Injuries to the oral mucosa occur due to physical, thermal, or chemical trauma [4]. Physical factors that can cause this include sharp tooth margins, use of orthodontic appliances, or bitten cheeks [5,6]. The prevalence of ulcers worldwide is 25% [5], while in Indonesia at the Oral Medicine Clinic of the Dental and Oral Hospital, Faculty of Dentistry, University of Jember, from March to November 2016, the prevalence of traumatic ulcers was 6.5% out of a total of 766 patients [7].

The clinical picture for this injury shows signs of acute inflammation, such as oval shape, redness, swelling, and pain. The ulcer is lined with a yellowish-white fibrinous exudate and surrounded by an erythematous halo [6]. Treatment for traumatic ulcers is often topical corticosteroids such as topical triamcinolone acetonide. However, this drug can cause side effects such as itching, burning, irritation, dry skin, headaches, and dizziness. In addition, long-term use can cause immune system resistance and epithelial cell atrophy [7]. From this description, it is necessary to use alternative ingredients from herbal sources which have the advantages of anti-inflammatory properties and fewer side effects. The use of synthetic drugs also causes antibiotic resistance. The alternative currently being developed is to combine two ingredients, namely dental pulp mesenchymal stem cell secretome (DPMSCS) and robusta green coffee bean extract (RGCBE), so that they can complement each other. RGCBE contains caffeine, phenolic compounds, trigonellines, and chlorogenic acid, which have antibacterial and anti-inflammatory properties [8,9]. RGCBE is preferred because it has the most chlorogenic acid phenolic compounds compared to other coffee beans [10]. This water-soluble chlorogenic acid is a polyphenol with antimicrobial, antioxidant, anti-carcinogenic, antipyretic, analgesic, and anti-inflammatory functions in vitro and in vivo experiments in animal models [11-13].

Nowadays, stem cells are the main attraction in medical practice due to their regenerative abilities. The DPMSCS surrounding these stem cells can secrete growth factors, cytokines, chemokines, angiogenic factors, and exosomes that have the beneficial function of regenerating damaged tissues through a paracrine effect that stimulates endogenous stem cells [14-16]. Therefore, the combination of DPMSCS and RGCBE is expected to be an alternative for wound treatment. This study hypothesizes that DPMSCS and RGCBE gel combination can decrease neutrophil count and enhance wound healing of traumatic ulcers by decreasing the traumatic ulcer diameter. Furthermore, this study aims to investigate the ability of DPMSCS and RGCBE on wound healing in a Wistar rats (*Rattus norvegicus*) model of traumatic ulcer.

## Material and Methods

Ethical approval for this study (Ref. Number 999/UN25.8/KEPK/DL/2020) was provided by the Ethical Committee of Medical Research at the Faculty of Dentistry at Jember University, Jember, on September 10, 2020. This was laboratory experimental research with a randomized control group post-test only design.

#### Dental Pulp Stem Cells Secretome Processing Procedure

Dental pulp was taken from human tooth stock cultured in the research stem cell and development center at Universitas Airlangga Surabaya. The culture media was  $\alpha$ MEM ( $\alpha$ - Minimum Essential Medium) Eagle (Sigma-Aldrich, UK) Fetal Bovine Serum (Biologend, China), Penicillin-streptomycin (Biologend, China). After 4–5 rounds of processing and reaching 80% confluence, cultures were separated with a trypsin solution (Sigma-Aldrich, UK) and centrifuged to obtain a supernatant called the DPMSCS.

#### Robusta Coffee Bean Extract Manufacturing Process

RGCBE was obtained from the Indonesian Coffee and Cocoa Research Center located on Jalan Renteng, Gebang, Nogosari, Rambli Puji District, Jember Regency, East Java. The coffee beans were identified at Jember State Polytechnic. RGCBE is made using the maceration method. One kilogram of robusta green coffee beans was ground into small flakes and sifted into a fine powder, weighed 346.30 grams and then macerated with a 96% ethanol solution (1:5 ratio) for three days. Stirring was done twice a day, in the morning and evening. The maceration results were filtered using filter paper and then concentrated using a rotary evaporator at a temperature of 40°C so that preparation with a concentration of 100% was obtained. Then, DPMSCS and RGCBE with concentrations of 50% were combined and made into a gel.

#### Preparation of the Gel DPMSCS – RGCBE

The gel was made of 2 grams of CMC-Na 2% developed in 98 mL of hot water at 70°C in a mortar for 15 minutes until it swelled, then stirred until a clear preparation formed. The robusta coffee bean extract was then added and stirred until homogeneous in the mortar. To get a gel combination of DPMSCS and RGCBE with a concentration of 50%, the combination of DPMSCS and RGCBE was mixed with 2.5 grams of CMC-Na. RGCBE and a combination of RGCBE and DPMSCS along with the results of the (3-[4,5-dimethylthiazol-2-yl]-2,5 diphenyl tetrazolium bromide (MTT) test were obtained from previous research results [17].

#### Establishment of Traumatic Ulcer Animal Model

Young, male, healthy Wistar rats (*Rattus norvegicus*) ( $\pm$ 200–300 g) were obtained from the dentistry faculty at Jember University. The animals were acclimatized in the laboratory for one week. All animals were allowed free access to water and fed with standard rat pellets. The Wistar rats were divided into seven groups randomly, with each group consisting of four rats: Group K<sub>0</sub> (normal group), group K<sub>1-3</sub> (traumatic ulcer rats that received CMC-Na gel for three days), group K<sub>1-7</sub> (traumatic ulcer rats administered CMC-Na gel for seven days), group K<sub>2-3</sub> (traumatic ulcer rats administered with RGCBE for three days), group K<sub>2-7</sub> (traumatic ulcer rats administered with RGCBE for seven days), group K<sub>3-3</sub> (traumatic ulcer rats administered with a combination of DPMSCS and RGCBE for three days), and group K<sub>3-7</sub> (traumatic ulcer rats administered with combination DPMSCS and RGCBE for seven days). Ketamine (0.4 mL/kg) and xylazine (0.2 mL/kg) were administered for general anesthesia via the intramuscular route. A traumatic ulcer model was made from an amalgam stopper with a diameter of 3mm. This was heated for 30 seconds on a spirit burner and lightly touched for one second to the left buccal mucosa of the rats. Mice waited for 2 x 24 hours for the ulcer formation process.

The ulcer diameter was measured before gel application using a UNC-15 periodontal probe (Osung, Korea) along the ulcer [18]. All samples were sacrificed with ketamine and xylazine in a lethal dose.

After being sacrificed, cleaned buccal mucosa was placed in a 10% neutral buffered formalin (HT501128, Sigma Aldrich Corp., St. Louis, MO, USA) for at least eight hours. After fixation, dehydration was carried out with 95%, 80%, 70%, and absolute alcohol for 60 minutes each, clearing by inserting the tissue into xylol three times for 60 minutes at each stage. A paraffin block was attached to the holder and then the buccal mucosa was cut vertically to 6 $\mu$ m with a microtome and put into slides. The paraffin was removed and left on a slide warmer at a temperature of 30°C-35°C for 12 hours.

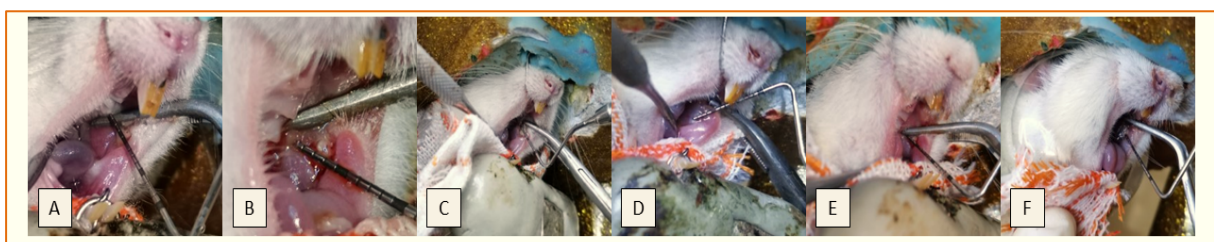
The deparaffinization stage was carried out by immersing the sample in xylol for 2-3 minutes. Samples were dehydrated with alcohol from high to low concentrations (absolute and 95%) for 3 minutes and then rinsed with running water. The slides were stained using hematoxylin and eosin (HE) (MHS1, Sigma Aldrich Corp., St. Louis, MO, USA) for 15 minutes. The sample was stained with eosin for 1-2 minutes and then dehydrated with 95% and absolute alcohol for 2-3 minutes. The clearing was carried out with xylol for three minutes each step, and mounting was carried out for five minutes. The result of this staining shows that the cytoplasm is pink and the nucleus is blue/black. Neutrophils or polymorphonuclear neutrophils are seen with the presence of granulocytes and have multi-lobed nuclei consisting of 3-5 segments that are continuous with thin strands or isthmuses [19]. Fibroblasts have elongated spindle or stellate formations with a multitude of cytoplasmic projections [20]. Cells were counted using a light microscope (Olympus, Tokyo, Japan) at 400x magnification. The counting area consisted of three visual fields in the area around the wound in the form of a V pattern for each sample and was calculated using a counter [21]. Then, the number of fibroblasts and neutrophils was counted in each sample [22,23].

### Statistical Analysis

The data were analyzed using Statistical Package for the Social Sciences 20.0 software (SPSS for Windows; SPSS, Chicago, IL, USA). Data obtained were analyzed with a normality test using the Shapiro-Wilk test to determine whether the data were normally distributed or not, then continued with the variant homogeneity test to examine population variations employing the Levene test ( $p > 0.05$ ). Finally, the Kruskal-Wallis test and the Mann-Whitney test were performed to determine the significance of differences between groups ( $p < 0.05$ ).

### Results

The diameter of ulcers of Wistar rats on the left buccal mucosa was carried out on day 3 and day 7. The clinical presentation of traumatic ulcer can be seen in Figure 1 (A-F). The mean and standard deviations of ulcer diameter, both from the control group and the treatment groups, were tabulated and presented in Figure 2.



**Figure 1.** Traumatic ulcer on the left buccal mucosa of rats, measured with the UNC-15 periodontal probe. A) K<sub>1</sub>-3; B) K<sub>1</sub>-7; C) K<sub>3</sub>-3; D) K<sub>3</sub>-7; E) K<sub>3</sub>-3; F) K<sub>3</sub>-7.



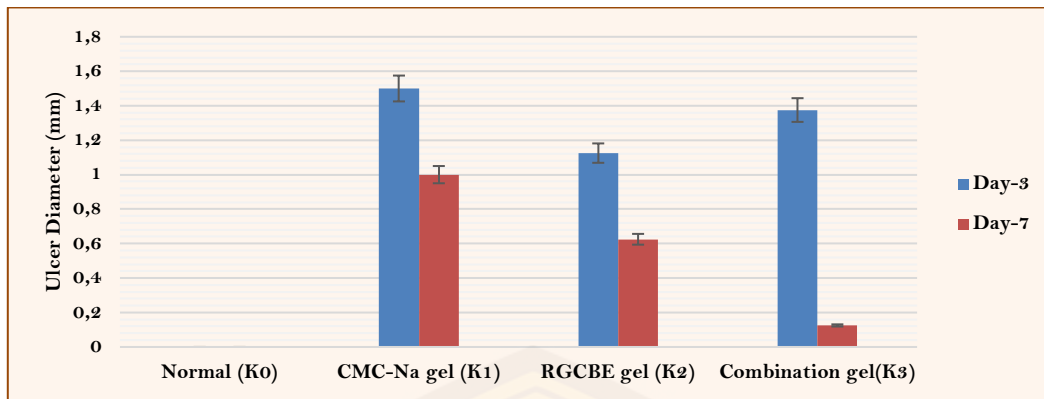


Figure 2. The mean and standard deviation of traumatic ulcer's diameter (mm) in all groups on day 3 and day 7.

Observations revealed that ulcers in the normal group are 0mm because no ulcer was made. In control group K<sub>1</sub>-3, the ulcer has a healing diameter of 1.5±0.40mm, the K<sub>1</sub>-7 control group has a diameter of 1±0.40mm, the K<sub>2</sub>-3 RGCBE gel treatment group has a diameter of 1.125±0.63mm, the RGCBE gel treatment group K<sub>2</sub>-7 has a diameter of 0.625 ± 0.25 mm, the K<sub>3</sub>-3 combination gel treatment group has a diameter of 1.375±0.25mm, and the K<sub>3</sub>-7 combination gel treatment group has a diameter of 0.125 ± 0.25 mm (Figure 2). The Kruskal-Wallis test result revealed a significant difference in the wound healing process on day 7 (p=0.026); however, no difference was found in the day 3 group. The Mann-Whitney test recorded a significant difference in ulcer diameter of the treatment group on day 7 (Table 1).

Table 1. Mann Whitney test results of diameter ulcer at day-7.

Group	K <sub>1</sub> -7	K <sub>2</sub> -7	K <sub>3</sub> -7
K <sub>1</sub> -7	-	0.155	0.025*
K <sub>2</sub> -7	-	-	0.040*
K <sub>3</sub> -7	-	-	-

\*Statistically Significant.

Histopathological observation on the left buccal mucosa was carried out on day 3 and day 7. The mean and standard deviation neutrophils and fibroblasts, from both the control group and treatment group, were presented in Figures 3 and 4. There were increased neutrophils in all treatment groups on day 3 and increased fibroblasts on day 7. The fluctuation is described in Figures 3 and 4 and the histopathological image of neutrophils and fibroblasts is in Figure 5.

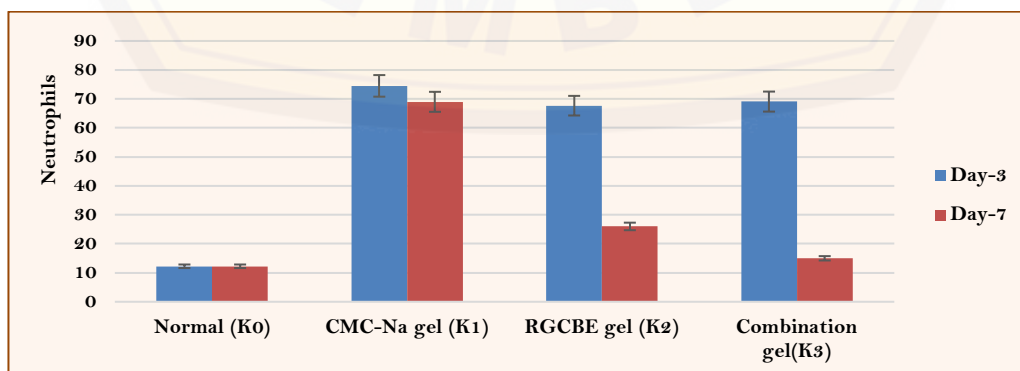


Figure 3. Total neutrophils at different times of evaluation.

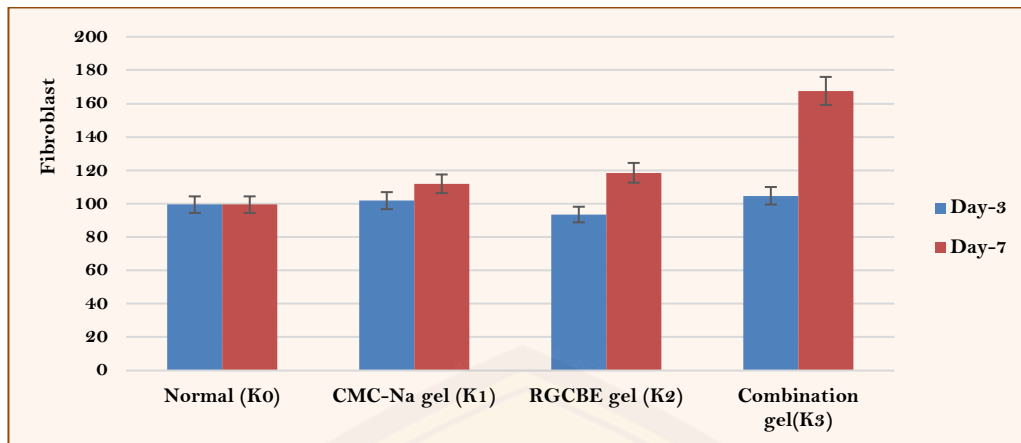


Figure 4. Total fibroblasts at different times of evaluation.

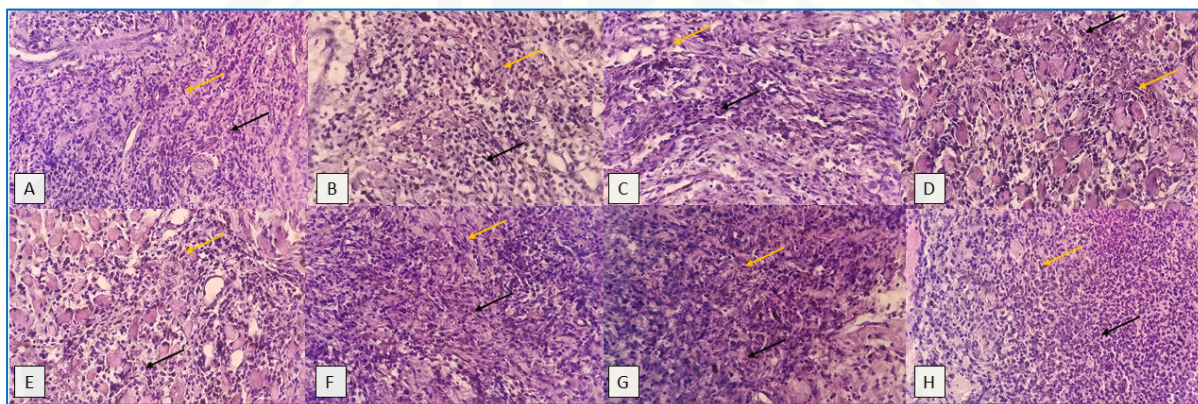


Figure 5. Histopathological image of neutrophils and fibroblasts of traumatic ulcers. Yellow arrows indicate fibroblasts and black arrows indicate neutrophils using HE staining with 400x magnification with a light microscope. A) K<sub>0</sub>-3; B) K<sub>0</sub>-7; C) K<sub>1</sub>-3; D) K<sub>1</sub>-7; E) K<sub>2</sub>-3; F) K<sub>2</sub>-7; G) K<sub>3</sub>-3; H) K<sub>3</sub>-7.

The Kruskal-Wallis test result revealed a significant difference in neutrophils ( $p=0.007$ ) and fibroblasts ( $p=0.028$ ) on day 7. The Mann-Whitney test recorded a significant difference in neutrophils of the treatment group on day 7. There was no significant difference ( $p>0.05$ ) found in neutrophils and fibroblasts on day 3 with the Kruskal-Wallis test (Table 2).

Table 2. Mann-Whitney test results of neutrophils and fibroblast.

Group	Neutrophils				Fibroblast			
	K <sub>0</sub>	K <sub>1</sub> -7	K <sub>2</sub> -7	K <sub>3</sub> -7	K <sub>0</sub>	K <sub>1</sub> -7	K <sub>2</sub> -7	K <sub>3</sub> -7
K <sub>0</sub>	-	0.773	0.564	0.043*	-	1.000	0.564	0.043*
K <sub>1</sub> -7	-	-	0.885	0.043*	-	-	0.309	0.021*
K <sub>2</sub> -7	-	-	-	0.043*	-	-	-	0.043*
K <sub>3</sub> -7	-	-	-	-	-	-	-	-

\*Statistically Significant.

## Discussion

This traumatic ulcer model uses Wistar rats because they have a similar mucosal tissue structure to humans, with both having epithelial, basal layer, and connective tissue structures [24]. After the treatment of traumatic ulcers in rats, ulcer diameter decreased more rapidly in the DPMSCS and RGCBE combination gel group. This examination found that DPMSCS can accelerate wound closure by decreasing the number of

neutrophil cells and increasing the number of fibroblasts, functions that accelerate wound healing. In addition, the ulcer diameter after administration of RGCBE and DPMSCS combination gel group decreased more rapidly. This is caused by several factors, including that the active substance contained in the DPMSCS gel contains extracellular proteins, growth factors, cytokines, chemokines, and several molecules that can affect the microenvironment and directly modulate endogenous mesenchymal stem cells (MSCs) to proliferate. Furthermore, the presence of growth factors in the DPMSCS can accelerate wound healing by inducing inflammatory mediators such as interleukin-1 (IL-1), Interleukin-6 (IL-6), and prostaglandin E<sub>2</sub> (PGE<sub>2</sub>) *in vitro*, reducing the initial inflammatory reaction *in vivo* [25,26].

RGCBE contains acidic compounds that contain more chlorogenic acid (CGA) than arabica coffee and other plants. CGA has been investigated for its antibacterial, antioxidant, and anti-inflammatory activity. RGCBE makes the wound environment acidic [27]. When an injury occurs, pH greatly affects the reactions of the biochemical healing process, such as increasing protease activity, oxygen release, and reducing bacterial (antibacterial) toxicity. RGCBE can control infection and inflammation because it contains CGA, caffeine, trigonelline, carbohydrates, fats, and amino acids. CGA contained in RGCBE gel can shorten the inflammatory phase by inhibiting the release of IL-6. The combination of these ingredients accelerates the ulcer healing process. This was in line with a previous study that showed MSCs' secretome has paracrine effects that are important in modulating regeneration after therapy. Secretome has various therapeutic effects, such as tissue regeneration, angiogenesis, anti-apoptosis, and immunoregulation [28]. The secretome mesenchymal stem cell group was shown to be able to reduce IL-1 $\beta$  compared to other groups with a significance level of 0.0001 ( $p < 0.05$ ) [29]. In addition, it is also known that DPMSCS can increase the expression of OCN and ALP in terms of increasing bone growth *in vivo* [30].

Based on histological observations, there was a significant difference in the decrease in the number of neutrophil cells on day 7 and an increase in the number of fibroblasts on day 7 in the combination DPMSCS and RGCBE gel group compared to the normal group. This test proves that DPMSCS can accelerate wound closure by decreasing the number of neutrophil cells and increasing the number of fibroblasts, all of which function in accelerating wound healing [31]. It can be seen in the study that DPMSCS can reduce neutrophils to nearly normal groups on day 7. Similar studies with 50% RGCBE gel were also shown to reduce tumor necrosis factor- $\alpha$  (TNF- $\alpha$ ) expression. TNF- $\alpha$  is known as an inflammatory cytokine that is often used as an indicator of cellular oxidative stress, apoptosis, or necrosis. TNF- $\alpha$  levels will increase when inflammation occurs [32]. When ulcers occur, pH greatly affects the reactions of biochemical healing processes, including increasing protease activity and oxygen release, reducing bacterial toxicity (antibacterial), triggering angiogenesis, and increasing fibroblast activity [32,33].

The results of this study showed that the ulcer diameter healing process was faster in the combination of DPMSCS and RGCBE group than in the RGCBE-only group, proving that if only one ingredient is given, the healing process is less than optimal because only the compounds contained in RGCBE that have antibacterial and anti-inflammatory activities but do not contain growth factors function to accelerate the healing process. Processing coffee beans can reduce the ability of these compounds [34]. Previous study have shown that the toxicity test of caffeine with keratinocytes is not toxic at various doses [35].




Research on MSCs *in vivo* has shifted the paradigm from MSCs as tissue replacement to becoming a medical signaling cell because of their ability *in vivo* to express the secretome by secreting soluble factor materials in areas of injury and areas of inflammation. MSCs are believed to have a role in repairing tissue damage. The presence of tissue injury is always associated with the activity of the immune system or inflammatory cells, not

only macrophages or neutrophils but also adaptive immune cells, including clusters of differentiation (CD) CD4+T cells, CD8+T cells, and B cells. Inflammatory mediators such as TNF- $\alpha$ , IL-1 $\beta$ , free radicals, chemokines, and leukotrienes are produced by phagocytic cells in response to cell damage. The interaction between MSCs and inflammatory cells is very complex. MSCs can either secrete cytokines or inhibit the action of cytokines. For example, MSCs secrete transforming growth factor- $\beta$  (TGF- $\beta$ ) and other factors, increasing the induction of T cells and macrophages. The paracrine effects of MSCs are critical for maintaining epithelial cell integrity and promoting angiogenesis through their ability to regulate cell proliferation and differentiation [25,36-38]. This study's results were only limited to traumatic ulcer animal model using Wistar rats (*R. norvegicus*). In addition, the biomarker of traumatic ulcer wound healing and examination method in this study is limited, other biomarkers examination regarding traumatic ulcer wound healing is necessary with various methods.

## Conclusion

A combination of DPMSCS and RGCBE 50% accelerates traumatic ulcer wound healing by lowering ulcer diameter, decreasing neutrophils counts and increasing fibroblast proliferation *in vivo*. Further research is needed on combining stem cell secretomes with robusta coffee bean extract to heal ulcers on a combination of days and other dosage forms and cure other dental diseases.

## Authors' Contributions

EI	 <a href="https://orcid.org/0000-0002-4270-8205">https://orcid.org/0000-0002-4270-8205</a>	Conceptualization, Methodology, Formal Analysis, Investigation, Resources, Writing - Original Draft and Writing - Review and Editing.
IET	 <a href="https://orcid.org/0000-0002-0590-5170">https://orcid.org/0000-0002-0590-5170</a>	Conceptualization, Methodology, Formal Analysis, Investigation, Resources, Writing - Original Draft and Writing - Review and Editing.
DSS	 <a href="https://orcid.org/0000-0002-4801-7229">https://orcid.org/0000-0002-4801-7229</a>	Conceptualization, Methodology, Formal Analysis, Investigation, Writing - Original Draft, Writing - Review and Editing and Supervision.
All authors declare that they contributed to critical review of intellectual content and approval of the final version to be published.		

## Financial Support

None.

## Conflict of Interest

The authors declare no conflicts of interest.

## Data Availability

The data used to support the findings of this study can be made available upon request to the corresponding author.

## Acknowledgements



All the authors are thankful to Dentistry faculty of Jember University for technical supports. The authors also thank Alexander Patera Nugraha DDS, MSc, PhD for the discussion of this study.

## References

- [1] WHO. Burns. Fact Sheets 2018. Available from: <https://www.who.int/en/news-room/fact-sheets/detail/burns>. [Accessed on June 19, 2019].
- [2] Zhang P, Zou B, Liou Y-C, Huang C. The pathogenesis and diagnosis of sepsis post burn injury. *Burn Trauma* 2021; 9:tkaa047. <https://doi.org/10.1093/burnst/tkaa047>
- [3] Forbinake NA, Ohandza CS, Fai KN, Agbor VN, Asonglefac BK, Aroke D, et al. Mortality analysis of burns in a developing country: a CAMEROONIAN experience. *BMC Public Health* 2020; 20:1269. <https://doi.org/10.1186/s12889-020-09372-3>

- [4] Regezi JA, Verstraete FJM. Clinical-Pathologic Correlations. In: Verstraete FJM, Lommer MJ. Oral and Maxillofacial Surgery in Dogs and Cats. W.B. Saunders; 2012. <https://doi.org/10.1016/B978-0-7020-4618-6.00039-7>
- [5] Surboyo MDC, Arundina I, Rahayu RP. Increase of collagen in diabetes-related traumatic ulcers after. Dental Journal (Majalah Kedokteran Gigi) 2017; 50(2):71-5. <https://doi.org/10.20473/j.djmk.v50.i2.p71-75>
- [6] Apriasari ML, Rahayu RP, Ernawati DS. Mauli banana stem extract application increased expression of NF-kB in traumatic ulcer healing. Dental Journal 2018; 51(2):67-70. <https://doi.org/10.20473/j.djmk.v51.i2.p67-70>
- [7] Srivastava R, Kundu A, Pradhan D, Jyoti B, Chokotiya H, Parashar P. A comparative study to evaluate the efficacy of Curcumin Lozenges (TurmNova®) and intralesional corticosteroids with hyaluronidase in management of oral submucous fibrosis. J Contemp Dent Pract 2021; 22(7):751-5. <https://doi.org/10.5005/jp-journals-10024-3144>
- [8] Muttaqin Z, Lina Hadi, Zara Maghfirah. Efficacy of Robusta coffee bean extract (Coffea robusta) against bacterial growth of Staphylococcus aureus. Biosci Med J Biomed Transl Res 2022; 6:1675-9. <https://doi.org/10.37275/bsm.v6i4.493>
- [9] Nugraha A, Purwati, Susilowati H, Hendrianto E, Karsari D, Ertanti N, et al. Medicinal Signaling Cells Metabolite Oral Based as a Potential Biocompatible Biomaterial Accelerating Oral Ulcer Healing (In Vitro Study). Eur Dent J 2019; 13(3):432-6. <https://doi.org/10.1055/s-0039-1693923>
- [10] Sunarharum WB, Yuwono SS, Aziza OF. Study on the effect of roasting temperature on antioxidant activity of early-roasted Java coffee powder (Arabica and Robusta). IOP Conf Ser Earth Environ Sci 2019; 230:012045. <https://doi.org/10.1088/1755-1315/230/1/012045>
- [11] Farah A. Nutritional and health effects of coffee. In: Lashermes P. Achieving sustainable cultivation of coffee. Breeding and quality traits. Burleigh Dodds Science Publishing, Cambridge, UK, 2018. 259-90. <https://doi.org/10.19103/as.2017.0022.14>
- [12] Tajik N, Tajik M, Mack I, Enck P. The potential effects of chlorogenic acid, the main phenolic components in coffee, on health: a comprehensive review of the literature. Eur J Nutr 2017; 56(7):2215-44. <https://doi.org/10.1007/s00394-017-1379-1>
- [13] Rezkia F, Wibawa K, Nugraha A. Curcumin loaded chitosan nanoparticle for accelerating the post extraction wound healing in diabetes mellitus patient: a review. Res J Pharm Technol 2020; 13(2):1039-42. <https://doi.org/10.5958/0974-360X.2020.00191.2>
- [14] Suciadi S, Nugraha A, Ernawati D, Ayuningtyas N, Narmada I, Prahasanti C, et al. The efficacy of human dental pulp stem cells in regenerating submandibular gland defects in diabetic wistar rats (Rattus norvegicus). Res J Pharm Tech 2019; 12(4):1573-9. <https://doi.org/10.5958/0974-360X.2019.00261.0>
- [15] Sarasati A, Rezkita F, Wibawa K, Winias S, Nugraha AP, Ridwan RD, et al. Gingival mesenchymal stem cells, concentrated growth factors and silk-fibroin scaffold to alleviate peripheral nerve regeneration: a review. Biochem Cell Arch 2020; 20(1 Suppl):2921-9. <https://doi.org/10.35124/bca.2020.20.S1.2921>
- [16] Aprilianti N, Rahmadhani D, Rizqianti Y, Ridwan RD, Ramadhani N, Nugraha A. Periodontal ligament stem cells, solcoseryl pasta incorporated nano-hydroxyapatite silica gel scaffold for bone defect regeneration in chronic periodontitis: A review. Biochem Cell Arch 2020(1 Suppl); 20:3101-6. <https://doi.org/10.35124/bca.2020.20.S1.3101>
- [17] Sari DS, Bumi MEC. Potensi Asam Klorogenik Dari Biji Kopi Robusta Sebagai Stimulator Sel Punca Mesensimal Pulpa Gigi Dalam Meningkatkan Kecepatan Migrasi, Proliferasi Dan Kemampuan Diferensiasi Osteogenik Sebagai Strategi Terapi Regenerasi Jaringan Periodontal. Lap Penelit Hibah IDB Intern UNEJ 2019. [In Indonesian].
- [18] Hernawati S, Zikra YA, Fatmawati DWA. The effects of topical application of red pomegranate (Punica granatum Linn) extract gel on the healing process of traumatic ulcers in Wistar rats. Dent J (Majalah Kedokt Gigi) 2019; 52(2):90-4. <https://doi.org/10.20473/j.djmk.v52.i2.p90-94>
- [19] Tigner A, Ibrahim SA, Ian M. Histology, White Blood Cell. Blood Cell. 2021 Nov 19. In: StatPearls [Internet]. Treasure Island (FL): StatPearls Publishing; 2022.
- [20] Dick MK, Miao JH, Limaem F. Histology, Fibroblast. 2022 May 8. In: StatPearls [Internet]. Treasure Island (FL): StatPearls Publishing; 2022.
- [21] Hendriati L, Hamid IS, Widodo T, Wandasari C, Risata PM. Effect of Egg White Gel againts Burn Healing on White Rat (Rattus norvegicus). J Ilmu Kefarmasian Indones 2018; 16(2):231. <https://doi.org/10.35814/jifi.v16i2.532>
- [22] Serafini S, Santos MM, Aoun Tannuri AC, Zerbini MCN, de Mendonça Coelho MC, de Oliveira Gonçalves J, et al. Is hematoxylin-eosin staining in rectal mucosal and submucosal biopsies still useful for the diagnosis of Hirschsprung disease? Diagn Pathol 2017; 12(1):84. <https://doi.org/10.1186/s13000-017-0673-9>
- [23] Pramono A, Adiwirno B, Mayasari LO. Efektivitas pemberian ekstrak gel Belimbing Manis (Averrhoa carambola Linn) terhadap kesembuhan ulkus traumatikus studi in vivo terhadap mukosa tikus (Strain Wistar ). Pros Semin Nas Publ Hasil-Hasil Penelit Dan Pengabd Masy "Implementasi Penelit Dan Pengabd Masy Untuk Peningkatan Kekayaan Intelegt 2017; Universita: 39-44. [In Indonesian].
- [24] Groeger S, Meyle J. Oral mucosal epithelial cells. Front Immunol 2019; 10:208. <https://doi.org/10.3389/fimmu.2019.00208>
- [25] Sari DS, Maduratna E, Bumi C, Sudiana I-K, Rantam FA. Role of secretome mesenchymal stem cells as immunomodulator in periodontal diseases. J Dentomaxillofacial Sci 2021; 6(3):139-46. <https://doi.org/10.15562/jdmfs.v6i3.989>

- [26] Rahmawati D, Nugraha AP, Ardani IGAW, Triwardhani A, Narmada IB. Role of hematopoietic stem cell in inflammatory response during orthodontic tooth movement: a narrative review. *Biochem Cell Arch* 2020; 20(1):2879-82. <https://doi.org/10.35124/bca.2020.20.S1.2879>
- [27] Arimbi D, Yuwono HS. pH of wound fluids treated using coffee powder and bacitracin-neomycin powder. *Glob j Surg* 2016; 4(1):9-11. <https://doi.org/10.12691/js-4-1-3>
- [28] Xia J, Minamino S, Kuwabara K, Arai S. Stem cell secretome as a new booster for regenerative medicine. *Biosci Trends* 2019; 13(4):299-307. <https://doi.org/10.5582/bst.2019.01226>
- [29] Shiddiqi T, Adnan Z, Nurudhin A. Pengaruh secretome sel punca mesenkimal terhadap ekspresi interleukin-1 $\beta$  Dan Caspase-1. *Biomedika* 2018; 9(2):31-8. <https://doi.org/10.23917/biomedika.v9i2.5840> [In Indonesian].
- [30] Martin M, Sari D, Mantika R, Praharani D. Combination of dental pulp stem-cell secretome and Robusta coffee bean extract (*Coffea canephora*) in enhancing osteocalcin and alkaline phosphatase expression in periodontitis-induced wistar rats. *J Orofac Sci* 2021; 13(2):136-41. [https://doi.org/10.4103/jofs.jofs\\_157\\_21](https://doi.org/10.4103/jofs.jofs_157_21)
- [31] Kenisa YP, Istiati I, Juliastuti WS. Effect of Robusta coffee beans ointment on full thickness wound healing. *Dent J (Majalah Kedokt Gigi)* 2012; 45(1):52-57. <https://doi.org/10.20473/j.djmk.v45.i1.p52-57>
- [32] Fatimatuzzahro N, Ermawati T, Prasetya RC, Destianingrum PQ. Efek pemberian gel ekstrak biji kopi robusta (*Coffea canephora*) terhadap jumlah osteoblas dan osteoklas pada tulang alveolar tikus periodontitis. *Padjadjaran J Dent Res Students* 2020; 4(2):128-133. <https://doi.org/10.24198/pjdrs.v4i2.28383> [In Indonesian].
- [33] Narmada IB, Putri PD, Lucynda L, Triwardhani A, Ardani IGAW, Nugraha AP. Effect of caffeic acid phenethyl ester provision on fibroblast growth Factor-2, matrix metalloproteinase-9 expression, osteoclast and osteoblast numbers during experimental tooth movement in Wistar rats (*Rattus norvegicus*). *Eur J Dent* 2021; 15(2):295-301. <https://doi.org/10.1055/s-0040-1718640>
- [34] Naveed M, Hejazi V, Abbas M, Kamboh AA, Khan GJ, Shumzaid M, et al. Chlorogenic acid (CGA): A pharmacological review and call for further research. *Biomed Pharmacother* 2018; 97:67-74. <https://doi.org/10.1016/j.biopha.2017.10.064>
- [35] Ojeh N, Stojadinovic O, Pastar I, Sawaya A, Yin N, Tomic-Canic M. The effects of caffeine on wound healing. *Int Wound J* 2016; 13(5):605-13. <https://doi.org/10.1111/iwj.12327>
- [36] Nugraha AP, Narmada IB, Ernawati DS, Dinaryanti A, Hendrianto E, Riawan W, et al. Bone alkaline phosphatase and osteocalcin expression of rat's Gingival mesenchymal stem cells cultured in platelet-rich fibrin for bone remodeling (in vitro study). *Eur J Dent* 2018; 12(4):566-73. [https://doi.org/10.4103/ejd.ejd\\_261\\_18](https://doi.org/10.4103/ejd.ejd_261_18)
- [37] Ma S, Xie N, Li W, Yuan B, Shi Y, Wang Y. Immunobiology of mesenchymal stem cells. *Cell Death Differ* 2014; 21(2):216-25. <https://doi.org/10.1038/cdd.2013.158>
- [38] Nugraha A, Triyono E, Prahasanti C, Sufiawati I, Prasetyo R, Ernawati D. The correlation of pathognomonic periodontal manifestation with CD4<sup>+</sup> level in people live with Human Immunodeficiency Virus/Acquired Immunodeficiency Syndrome in a Tertiary Hospital, Surabaya, Indonesia. *J Int Oral Heal* 2019; 11(3):137-40. [https://doi.org/10.4103/jioh.jioh\\_53\\_19](https://doi.org/10.4103/jioh.jioh_53_19)

Title	Type	↓ SJR	H index	Total Docs. (2022)	Total Docs. (3years)	Total Refs. (2022)	Total Cites (3years)	Citable Docs. (3years)	Cites / Doc. (2years)	Ref. / Doc. (2022)	
97 <a href="#">Pesquisa Brasileira em Odontopediatria e Clinica Integrada</a> 	journal	0.212 Q3	14	80	487	2523	360	482	0.69	31.54	
98 <a href="#">Fluoride - Quarterly Reports</a> 	journal	0.211 Q3	50	16	93	661	71	87	0.83	41.31	
99 <a href="#">Iranian Endodontic Journal</a> 	journal	0.210 Q3	28	38	134	1200	83	132	0.67	31.58	
100 <a href="#">Swiss dental journal</a> 	journal	0.208 Q3	26	32	103	0	89	103	0.66	0.00	

