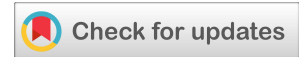

(CASE REPORT)



## Vestibular deepening to improve periodontal pre-prosthetic: A case report

Andry Elvandari <sup>1</sup>, Neira Najatus Sakinah <sup>2</sup>, Samuel Rehuel Santoso <sup>1</sup> and Agung Krismariono <sup>1,\*</sup>

<sup>1</sup> Department of Periodontology, Faculty of Dental Medicine, Universitas Airlangga, Surabaya, Indonesia.

<sup>2</sup> Department of Periodontology, Faculty of Dental Medicine, Universitas Jember, Indonesia.

World Journal of Advanced Research and Reviews, 2022, 14(03), 380–384

Publication history: Received on 11 May 2022; revised on 14 June 2022; accepted on 17 June 2022

Article DOI: <https://doi.org/10.30574/wjarr.2022.14.3.0561>

### Abstract

**Objective:** The treatment of partial or complete denture installation can be challenged by a shallow vestibule. As a preventive, the vestibule must be deepened. The purpose of deepening the vestibule is to improve the esthetics and retention of the denture by increasing the width of the attached gingiva.

**Methods:** The patient visited the Department of Periodontics, Dental and Oral Hospital Universitas Airlangga to eliminate tartar. The patient says that his maxillary front tooth had fallen out the day before and that he wished it replaced. A previous history of hypertension and takes amlodipine 10 mg daily regularly. Because the patient's vestibule is shallow, vestibuloplasty is required to deepen it. Conventional surgical procedures were used to perform vestibuloplasty.

**Results:** One week post-surgical, there was minimal inflammation surrounding the stitches, periodontal pack falls out on the fifth day, and thread suture remains. On the 14th day, there was no inflammation and the clinical results were as expected.

**Conclusion:** Vestibular deepening is effective in increasing the depth of the vestibule and the width of keratinized gingiva.

**Keywords:** Vestibular Deepening; Periodontal Pre-Prosthetic; Maxillary Buccal Vestibulum; Vestibuloplasty

### 1. Introduction

Tooth loss is a prevalent dental and oral health issue. The tooth directly contributes to the mastication function and is important for maintaining the vertical and distal relations between the mandible and the maxilla. The loss of a great number of teeth increases the occlusal pressure on the remaining teeth, leading to more complex treatments. It can also cause the teeth close to them to shift or move. This is due to the teeth having been forced to unequal chewing pressure. Teeth can move or shift as a result of vertical load [1,2].

Missing teeth can be replaced in a variety of ways. Removable Partial Dentures (RPDs), fixed partial dentures, and dental implants are all options [3]. Periodontal status, cosmetic criteria, cost, psychology, anatomical limits, and the patient's acceptability are all factors that may influence the prosthesis chosen. RPDs are widely used in clinical practice because they are cost-effective and make it easier to care for the remaining teeth. According to Dr. Aditi Sharma and Dr. Asra Tabassum's research on patient satisfaction with removable partial dentures after six years, the majority of patients had a positive experience with RPD [4,5].

\* Corresponding author: Agung Krismariono  
Department of Periodontology, Faculty of Dental Medicine, Universitas Airlangga, Surabaya, Indonesia.

If the tooth loss didn't replace, it'll cause resorption of the alveolar ridge. The pace of ridge resorption in the alveolar ridge is determined by the patient's overall wellbeing and the number of forces applied during mastication. Because of the existence of systemic illness, this resorption may be accelerated.[6] Extensive resorption frequently causes vertical and horizontal disharmony (prognathism or retrognathism) between the maxillary and mandibular alveolar ridges, leading to additional deterioration of function [7].

Pre-prosthetic surgery refers to treatments that are performed to help with the construction of prosthetics or to improve the prognosis of prosthodontic care. Pre-prosthetic surgery entails procedures that try to remove lesions or anomalies in the jaws' hard and soft tissues. Pre-prosthetic surgery in shallow vestibulum cases is needed [8].

Oral hygiene and the retention of prosthetic equipment both require the adequate vestibular depth [9,10]. Inadequate vestibular depth can lead to pathologic outcomes such as gingival inflammation, recession, and pocket development, bone resorption.[11] Progressive bone loss in the edentulous maxilla or mandible creates issues with denture stability and placement.[12] Gingival margin binds better around teeth and implants with attached gingiva, which reduces inflammation around restored teeth [13]. A vestibular depth reduction may be caused by a long-term edentulous crest, an alveolar traumatism, or severe periodontitis.[14] To obtain vestibule deepening, a variety of surgical procedures have been proposed. A surgical technique on the soft tissue of the upper or lower jaw is known as vestibuloplasty [12].

Vestibuloplasty is a mucogingival operation that involves deepening the vestibular trough, repositioning the frenulum or muscle attachments, and increasing the attached gingiva zone [11]. Surgical approaches are used in traditional surgical techniques to extend vestibular length Clark's, and Kazanjian's, among others, have been reported [15].

Vestibuloplasty treatment is one pre-prosthetic surgery to improve the denture bearing area and surrounding tissue. The indication of pre-prosthetic surgery to prepare the mouth to receive dental prosthesis are the presence of tori, exostosis, high frenal attachment, and excessive flabby tissue or irregular alveolar ridge [6].

In this case, the patient has lost his anterior teeth. The loss of anterior teeth can affect the aesthetic, phonetic, and difficulties to bite. An effective prosthetic option for individuals with partial tooth loss is a removable partial denture. Minimal worn tooth structure, easy maintenance compared to other forms of prostheses, effective solutions to mechanically address tough problems, and flexibility are only a few of the benefits [16].

---

## 2. Case report

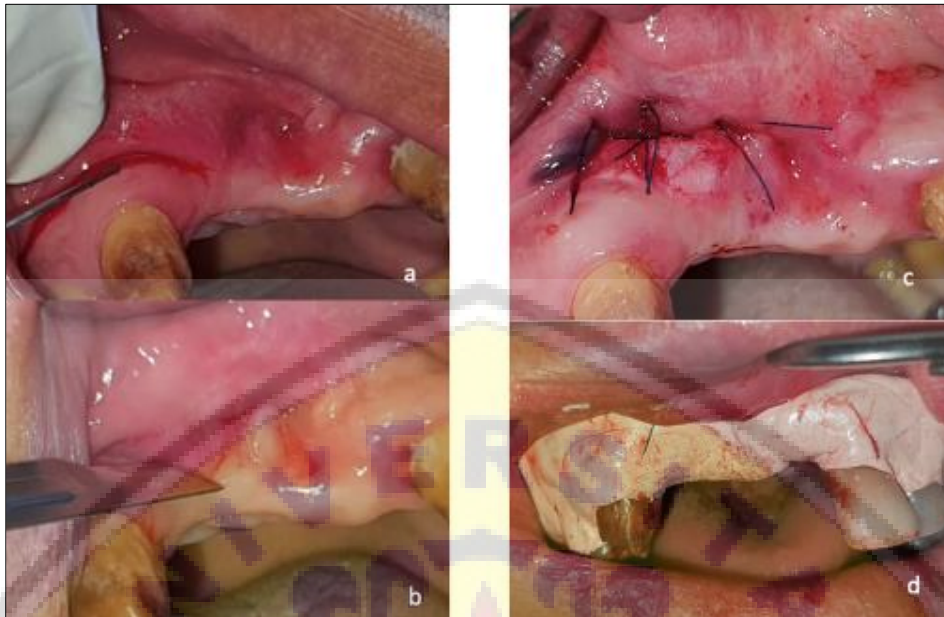A 52-year-old male patient came to the Department of Periodontics, Dental and Oral Hospital, Universitas Airlangga, with complaints that he wanted to clean tartar and replace missing teeth. Clinical examination found that the patient has a shallow vestibule and the width of the keratinized gingiva is inadequate, so treatment for deepening the vestibule is needed. The patient admitted to having a history of hypertension and routinely taking Amlodipine 10 mg once a day every morning. Vestibuloplasty to deepening of the vestibule was performed using the conventional surgical technique.



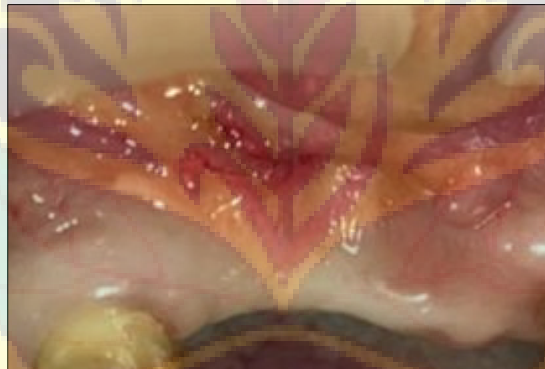
**Figure 1** Before vestibuloplasty

At the initial session, phase one actions were performed, which included scaling and root planing as well as oral hygiene instructions. Patients returned at the second visit to deepen the vestibule. The patient's blood pressure had previously been taken, and the result was 138/85 mm/Hg. Povidone-iodine was used to perform asepsis in the region surrounding the procedure. The mesiobuccal fold was anesthetized with 2% lidocaine and epinephrine 1:80,000. Vestibuloplasty begins with a 45-degree angle horizontal incision at the base of the vestibule with a blade 15c from distal 11 to mesial

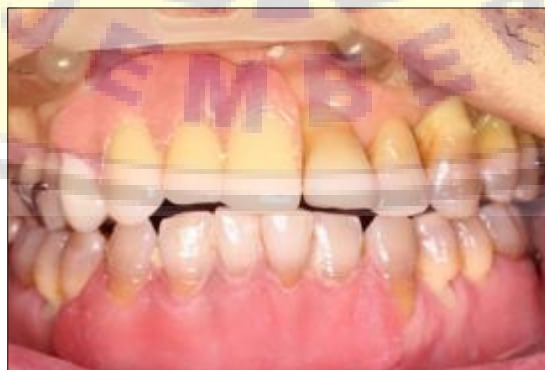13. Partial-thickness flap using a scalpel on the area that has been incised to the limit mesiobuccal fold area next to the area where the vestibule is deepened. Irrigation using saline solution.



**Figure 2** Vestibuloplasty procedure. a. Local anesthesia, b. Incision, c. Suturing, d. Periodontal dressing app



**Figure 3** One month after vestibuloplasty



**Figure 4** Metal frame partial denture insertion

The surgical wound was sutured with a simple interrupted suture using 4.0 Nylon at the incised mucosal margin to the connective tissue of the mesiobuccal fold. After that, the surgical wound was covered with periodontal dressing. Last, the patient is advised not to eat and drink hot for at least 1 hour postoperatively, take medicine as recommended



(Amoxicillin 500mg three times daily every 8 hours, Mefenamic acid 500mg three times daily, Chlorhexidine gluconate 0.2% mouth wash, take care of OH and the patient strong recommended to visit 7 days post-surgery for evaluation.

On the 7<sup>th</sup>-day post-surgery evaluation, the periodontal dressing was detachment on the 5<sup>th</sup>-day, there was still redness around the sutures, and the sutures were still intact. The post-surgical area was irrigated with saline solution and then the patient was instructed to maintain oral hygiene. The second evaluation at 14<sup>th</sup>-days post-surgery, found minimal inflammation in the post-surgical area, and the stitches were removed. One month after vestibuloplasty, missing teeth replacement was performed using metal frame removable partial denture.

---

### 3. Discussion

The alveolar bone atrophy and an insufficient amount of attached gingiva are typical in edentulous jaws. The bone basis may be adequate, but the high muscle attachments and bucco-gingival connections may not provide enough support for prostheses, causing them to slip loose during speech or feeding [17]. The shallow vestibule is a limited zone of keratinized gingiva and high frena attachments frequently occur. When marginal gingiva movement is noticed while pulling the lip, pull syndrome is diagnosed. Brushing teeth is more difficult in a shallow vestibule since there isn't enough space for the toothbrush [18]. Vestibuloplasty is a corrective surgical operation performed on the soft tissue of the upper and lower jaw's alveolar ridge to enhance the relative height of the alveolar ridge. It can be done on the labial or lingual side. Vestibuloplasty should be done to enlarge the denture-bearing area if the vestibule is too narrow [[6,19]].

Vestibuloplasty has a few do's and don'ts. Here the indications and contraindications for Vestibuloplasty [6].

Indications of vestibuloplasty:

- Ridge extension or lowering changes the submucosa, shifting attachments before prosthesis installation.
- When restoring edentulous bone, complement and finish the osseous operation.
- Improve the soft tissue drape if resection has been performed before and prosthesis restoration is needed.
- Dental implant stability and bone health maintenance around an implant

Contraindications of vestibuloplasty [20]:

- Patients with untreated medical disorders that cause extensive bleeding, lowered infection resistance, or poor healing.
- Alveolar ridge height should be kept to a bare minimum.
- Patients undergoing head and neck radiation therapy

Vestibuloplasty using conventional technique has excellent results to increase vestibular depth for periodontal prosthetic surgery. After 14 days post-surgery, minimal inflammation around the site and have the anticipated outcome.

---

### 4. Conclusion

Vestibuloplasty using the conventional technique is a procedure with minimally invasive to prepare periodontal prostheses. This treatment is effective in increasing the depth of vestibule and the width of keratinized gingiva.

---

### Compliance with ethical standards

#### *Acknowledgments*

The authors greatly appreciate to the Faculty of Dental Medicine, Universitas Airlangga.

#### *Disclosure of conflict of interest*

All authors declare no conflict of interest.

#### *Statement of informed consent*

Informed consent was obtained from the patient included in this case report.

## References

- [1] Chairunnisa R, Sihombing RJ. The Association between Number of Tooth Loss, Tooth Loss Quadrants, and Occlusal Support with Temporomandibular Disorders in Partially Edentulous Patients. *Advanced Health Science Research*. 2018; vol 8: 255-258.
- [2] Wirayudha A, Kamadjaja MJK, Agustono B. Increasing Denture Retention Using Compound Denture Technique-A Case Report. *Indonesian Journal of Dental Medicine*. 2018; 1(2): 90-92.
- [3] Vermeulen AHBM, Keltjens AM, Van't Hof MA, Kayser AF. Ten-Year Evaluation of Removable Partial Dentures: Survival Rates Based on Retreatment, Not Wearing and Replacement. *The Journal of Prosthetic Dentistry*. 1996 Sep; 76(3): 267-272 .
- [4] Nassani MZ, Tarakji B, Baroudi K, Sakka S. Reappraisal of the removable partial denture as a treatment option for the shortened dental arch. *European Journal of Dentistry*. 2013; 7(2): 251-256.
- [5] Gonçalves TMSV, Campos CH, Rodrigues Garcia RCM. Implant retention and support for distal extension partial removable dental prostheses: Satisfaction outcomes. *Journal of Prosthetic Dentistry*. 2014; 112(2): 334-339.
- [6] Divya Mehrotra. Pre-prosthetic Surgery. In: *Fundamentals of Oral and Maxillofacial Surgery*. New Delhi: Elsevier; 2020; p.143.
- [7] Phukela SS, Malhotra P, Dabas N, Yadav B, Phogat S, Madan R. Fruitful Ridge Augmentation: A Challenge in Edentulous patients: A Review Article. *Indian Journal of Health Sciences and Care*. 2018; 5(1): 34.
- [8] Chari H, Shaik KV. Preprosthetic Surgery: Review of Literature. *IJSS Case Reports & Reviews*; 2016 Sep; 3(4): 9-16.
- [9] Otoboni Molina G, Tomás de Oliveira M, Ricardo Pereira J, Salomon Ghizoni J. The use of latex biomembrane in mandible vestibuloplasty: a case report. *Revista da Faculdade de Odontologia*. 2013; 18(1): 120-124.
- [10] Newman MG, Takei HH, Klokkevold PR. *Newman and Carranza's Clinical Periodontology* 13<sup>th</sup> Ed. Elsevier; 2019.
- [11] Kalakonda B, Farista S, Koppolu P, et al. Evaluation of patient perceptions after vestibuloplasty procedure: A comparison of diode laser and scalpel techniques. *Journal of Clinical and Diagnostic Research*. 2016; 10(5): ZC96-ZC100.
- [12] Ivanova V, Chenchev I, Gavrailov T. CLINICAL COMPARISON OF THREE METHODS FOR VESTIBULOPLASTY IN THE ANTERIOR PART OF THE MANDIBULE. *Journal of IMAB - Annual Proceeding (Scientific Papers)*. 2018; 24(4): 2223-2227.
- [13] Natarajan S, Banu F, Kumar M, Lavu V. Management of Shallow Vestibule with Reduced Attached Gingiva in Fixed Prosthetic Intervention. *Cureus*. 2019; 11(6): 1-8)
- [14] Fokam ST, Ntep Ntep DB, Bohimbo JE, Nokam Abena ME, Messanga CB. Vestibuloplasty to enhance denture stability: About two observations. *Advances in Oral and Maxillofacial Surgery*. 2022; 6: 100288.
- [15] Yousef M, Abdelfattah MY, Moharam H, Fahmi M, Kossar A. Assessment of Patient Perception, Healing Outcomes and Gained Vestibular Depth of Er: Yag Laser Versus Conventional Surgical Mandibular Vestibuloplasty. *International Journal of Dental Sciences and Research*. 2015; 3(6): 137-143.
- [16] Dammar I, Ajmal A. An alternative approach to the replacement of missing teeth with adhesive bridges and unilateral RPD metal frames: a case report. *Journal of Case Reports in Dental Medicine (J Case Rep Dent Med)*. 2020; 2: 57.
- [17] Dzhongova E. Evaluation of postoperative results from the application of xenogeneic grafts (Mucoderm®) and after a mandibular vestibuloplasty. *Journal of Medical and Dental Practice*. 2019; 6(1): 1007-1016.
- [18] Wyrębek B, Górska R, Nędzi-Góra M, Plakwicz P. Effect of vestibular deepening on the periodontal status of teeth - Preliminary study. *Journal of Stomatology*. 2016; 69(5): 531-537.
- [19] S.M Balaji. Section IV : Minor Oral Surgical Procedur . In: *Textbook of Oral and Maxillofacial Surgery*. Elsevier; 2007.
- [20] UnitedHealthcare. Oral Surgery: Alveoloplasty and Vestibuloplasty – Dental Coverage Guideline. 2021. Available from [uhcprovider.com/content/dam/provider/docs/public/policies/dental/oral-surgery-alveoloplasty-vestibuloplasty.pdf](https://uhcprovider.com/content/dam/provider/docs/public/policies/dental/oral-surgery-alveoloplasty-vestibuloplasty.pdf)