

## Firecrackers Eyes Injury Cases Reports

Nugraha Wahyu Cahyana

Department of Ophthalmology, Faculty Medicine, Jember University, Jember 68121 Indonesia

Correspondence email: [nugraha.nwc@gmail.com](mailto:nugraha.nwc@gmail.com)

### Abstract

We here report three cases of boys aged 5, 8 and 10 years with injuries caused by firecrackers. Injuries consist of characteristic burns from explosions or sparks, indicating the injury was caused by firecrackers. The features of this case are discussed along with their implications. Additional measures taken in all three cases were treatment according to the injury suffered by each patient. The first patient was treated with floxa drops 3x a day, polygranate eye ointment 2x, methylpenisolone tablets 2x4mg, meloxicam 2x3mg. The second patient was given endotropinfloxa drops and methylprenisolan tablets 2x4mg. The third patient was given 3x eye drops for the right and left eyes, polygranate eye ointment for the right and left eyelids, bioplacenton ointment for the forehead and nose.

### Introduction

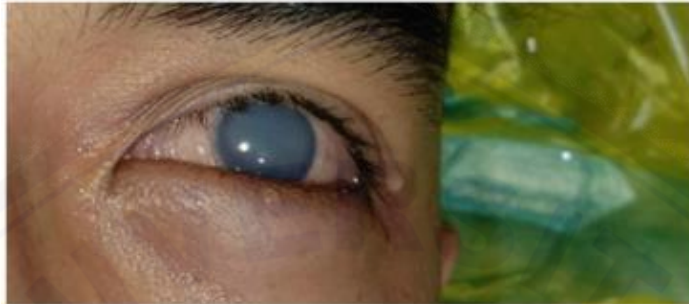In some countries firecrackers are a symbol of celebration, hope and prosperity and are believed to ward off evil spirits (Ying Lin, 2012). However, in Indonesia, firecrackers are more identical to what the majority of people do during Eid to celebrate the completion of the 30-day fast of Ramadan. In addition to Eid al-Fitr, firecrackers are also rife when there are other big days, for example Eid al-Adha, Independence Day and New Year. The firecrackers used can also be considered dangerous because in addition to producing flashes of light, they also produce a very massive explosion. Despite the dangers, this celebration has become a mushrooming habit. The situation is such that even a small accident with firecrackers can lead to life-threatening complications and vision. The body parts most frequently injured by firecrackers were the head and neck region, with the eyes in particular being the most frequently injured sites (45%) followed by the hands (38%)(Clarke J.A., 1994) (Berger LR, 1985) (BJ Fogarty, 1999) (Smith GA, 1996). The face is the most at risk from firecracker attacks, which tend to occur when the user bends over the firecracker to light it or watch it (Vinita Puri, 2009). Eye injuries are also among the most serious injuries caused by firecrackers worldwide, with nearly one in six eye injuries resulting in permanent vision loss (RPL Wisse, 2010). Victims due to firecrackers on the eyes and face that are severe require a large amount of money for the community. In this report we report three cases of the use of firecrackers and their health care implications regarding the eye.

### Case 1

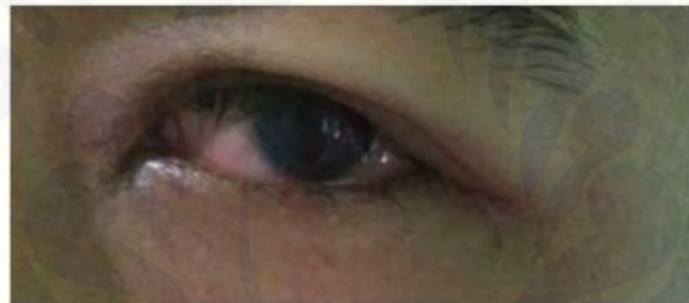On the first day a 5 year old boy was hit by a firecracker in his left eye. On examination, the left eye's visual acuity was 1/infinity. Hyperemic conjunctiva, cloudy cornea, coa, pupillary iris, lens and fundus could not be assessed. The patient was treated with floxa drops 3x a day, polygranate eye ointment 2x, methylpenisolone tablets 2x4mg, meloxicam 2x3mg. Normal right eye with 6/6 vision.

On the second day, visual acuity was 6/40 in the left eye, the conjunctiva hyperemia was reduced, the cornea was clear, the coa was deep and there was no hyphema. Iris/pupil was normal, no iridodialysis was found, lens impression was normal, fundus could not be assessed.

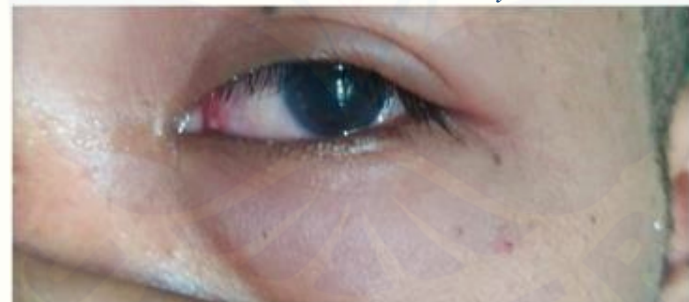
On the third day, the left eye's visual acuity was 6/12, the conjunctiva was clear, the cornea was clear, the coa was deep and there was no hyphema. Iris/pupil was normal, no iridodialysis was found, lens impression was normal, fundus was normal.



*Picture 1 First day*



*Picture 2 The second day*



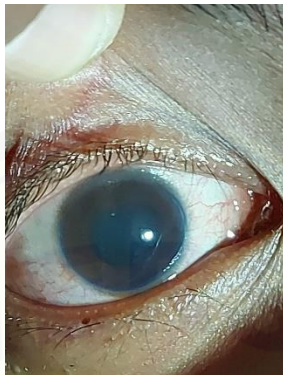
*Picture 3 The third day*

## Case 2

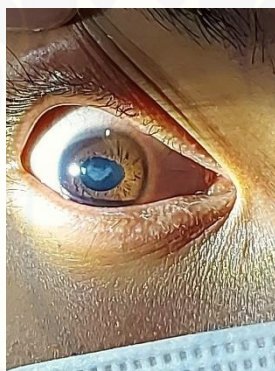A boy aged 10 years, right eye trauma due to firecrackers. Visual 1/60 conjunctiva hyperemia, cloudy cornea, coa there is a little hyphema, iridoplegia, clear lens. Fundus has not yet been assessed. Left eye normal, visual acuity 6/6 given endotropinifloxa drops and methylprenisolan tablets 2x4mg.

On the second day of the right eye, visual acuity was reduced at 2/60 conjunctiva hyperemia, the cornea was clear, there was no hyphema, the pupil was still not round, the lens and fundus could not be assessed.

On the tenth day of the right eye, visual acuity was 5/60, the conjunctiva was clear, the cornea was clear, there was no hyphema, the pupil was not round, the lens was cloudy (cataract was present), the fundus could not be assessed.



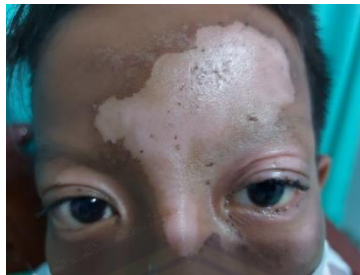*Picture 4 Right eye day 2*



*Figure 5 Right eye day 10*

### **Case 3**

Children aged 8 years, boys, were hit by firecrackers in their right eye, with burns on the superior palpebra, 6/12 vision, clear conjunctiva, clear cornea, iris and pupil, normal lens and fundus. The left eye had burns on the superior and inferior lids, clear conjunctiva, clear cornea, iris and pupil, normal lens and fundus. The forehead and nose also got burns. The therapy we give is floxa eye drops 3x right and left eye, polygranate eye ointment for the right and left eyelids, bioplacenton ointment for forehead and nose, methyl prednisolone tablet 2x4mg, meloxicam 2x3mg.



*Figure 6 Case 3*

## Discussion

Cases of victims of firecrackers from year to year have decreased, especially since 2017 with the issuance of the National Police Chief Regulation No. 17 of 2017 concerning the use of sparks by the public. Three cases of firecracker victims were reported. The first case is 5 years old, the second case is 10 years old, the third case is 8 years old. This is in accordance with the research conducted by Wang and his colleagues in China that the age range of the most victims is 5-14 years (Cheng Wang, 2013).

Of the three cases, all of them were male, this is in accordance with a study conducted by De Faber in the Netherlands 27 December 2008 and 4 January 2009 that 59% of 268 victims with 315 injured eyes male firecrackers. (JT, 2009)

For the three cases in this report the abnormalities included the eyelids, conjunctiva, cornea, anterior chamber, iris and lens. But according to (Preethi Jeyabal, 2019), the most common type of injury suffered by firecrackers is burns. From anterior to posterior, firecrackers can cause the following types of eye injuries:

- Eyelids: burns, lacerations.
- Conjunctiva: burns, abrasions, foreign bodies, symblepharon formation.
- Cornea: abrasions, lacerations, foreign bodies.
- Anterior chamber: hyphema, iritis, foreign body.
- Iris: sphincter tears, iridodialysis.
- Lens: traumatic cataract, subluxation, dislocation.
- Vitreous cavity: bleeding, foreign body
- Retina: detachment.
- Optic nerve: avulsion.
- Rupture of lobes.

Here are some types of firecrackers that cause injury (AR Isa, 1991):

1. Ground spinner or top firecracker
2. Double-bang or match firecrackers
3. Flare/fountain or fountain
4. Crackers or firecrackers
5. Rocket or jangwe

In India the most famous firecracker is the jangwe or rocket. Usually played by being put into a glass bottle and then fired. Among all types of firecrackers, rocket-type firecrackers are the cause of the most severe eye complications. Including blindness because the direction of the rocket is erratic and fast (Alexandra FL Edwin, 2008). Several studies have revealed that firecrackers not only harm the perpetrators, but also include people who look around (Con, 1991)

(Ramesh Venkatesh, 2017). In fact, a study from Northern China (Yichun Kong, 2015) showed that nearly half of their patients (47.5%) with eye injuries caused by firecrackers underwent multiple surgeries at once.

Overall, the factors that cause firecracker-related eye injuries are as follows (Vinita Puri, 2009) (Cheng Wang, 2013) (Kumar R, 2010) (Bagri N, 2013) (Centers for Disease Control and Prevention, 1995):

- a) Misuse or improper handling of the product.
- b) Use of illegal products.
- c) Device does not work or fails.
- d) The characteristics of firecrackers are erratic and unpredictable.
- e) Firecrackers bounce off hard surfaces.
- f) Lack of adult supervision for children.

Injuries due to firecrackers also often occur due to malfunctions in the firecrackers themselves. The malfunction in question is that the wick of the firecracker has been burned but there is no reaction at all. If this is the case, there are several steps to overcome it as follows (Preethi Jeyabal, 2019):

- a) Everyone must keep a safe distance from the firecrackers (not less than 3 meters)
- b) Count to 60 seconds
- c) Adults around in non-flammable clothing should approach with a bucket of water and completely immerse the firecracker
- d) Count to 60 seconds again
- e) Throw away the broken firecrackers and contact the authorities for a report

## Conclusion

Firecrackers are known as symbols of celebration, hope and prosperity and are believed to ward off evil spirits in some countries can pose unimaginable harm to the eyes of users and innocent bystanders. Some of these hazards can be prevented and avoided but there are also those that cannot be prevented and avoided. One method that has been shown to reduce the number of victims of firecrackers is to limit their use. Our responsibility as the medical community is to provide data on the health risks of firecrackers and provide education about the rules regarding firecrackers.

## References

- Centers for Disease Control and Prevention. (1995). Serious eye injuries associated with fireworks—United States. *Morbidity and Mortality Weekly Report*, 449–452.
- A R Isa, H. M. (1991). Fireworks related injuries during Hari Raya festival in Hospital Universiti Sains Malaysia--1986 to 1990. *Medical Journal of Malaysia*.
- Alexandra F L Edwin, T. C. (2008). The impact of recent legislation on paediatric fireworks injuries in the Newcastle upon Tyne region. *Burns*, 953-964.
- B J Fogarty, D. J. (1999). Firework related injury and legislation: the epidemiology of firework injuries and the effect of legislation in Northern Ireland. *Burns*.
- Bagri N, S. A. (2013). Fireworks injuries in children: a prospective study during the festival of lights. *Emergency Medicine Australasia*, 452–456.
- Berger LR, K. S. (1985). Injuries from Fireworks. *Pediatrics*, 877–882.

- Cheng Wang, R. Z.-L.-G.-A. (2013). Firework injuries at a major trauma and burn center: A five-year prospective study. *Burns*.
- Clarke JA, L. J. (1994). Firework related injury in New Zealand. *The New Zealand Medical Journal*, 423-425.
- JT, d. F. (2009). Fireworks injuries treated by Dutch ophthalmologists New Year 2008/09. *Ned Tijdschr Geneeskd*.
- Kon, M. (1991). Firework injuries to the hand. *Annales de chirurgie de la main et du membre superieur : organe officiel des societes de chirurgie de la main = Annals of hand and upper limb surgery*.
- Kumar R, P. M. (2010). Firecracker eye injuries during deepavali festival: a case series. *Indian Journal Ophthalmology*, 157–159.
- Preethi Jeyabal, L. D. (2019). Fireworks: boon or bane to our eyes? *International Ophthalmology*, 2407–2411.
- R P L Wisse, W. R. (2010). Ocular firework trauma: a systematic review on incidence, severity, outcome and prevention. *British Journal of Ophthalmology*, 1586–1591.
- Ramesh Venkatesh, P. G. (2017). Appraising the spectrum of firework trauma and the related laws during Diwali in North India. *Indian Journal Ophthalmology*, 140-143.
- Smith GA, K. J. (1996). The rockets' red glare, the bombs bursting in air: fireworks-related injuries to children. *Pediatrics*, 1–9.
- Vinita Puri, S. M. (2009). Firework injuries: a ten-year study. *Journal of Plastic, Reconstructive & Aesthetic Surgery*, 1103–1111.
- Yichun Kong, X. T. (2015). Six-year clinical study of firework-related eye injuries in North China. *Postgraduate Medical Journal* , 26-29.
- Ying Lin, X. L. (2012). Prognostic factors and visual outcome for fireworks-related burns during spring festival in South China. *Journal of Burn Care & Research*.