

Mental and behavioral disorders due to substances during the COVID-19 Pandemic: Prevalence, diagnosis, and management
Era Catur Prasetya¹, Kharisma Sukma Nanda², Khoffiah Dwi Oktaviana², Lens Hanin Herda Zhafirah², Lia Lisa Arista², M. Dedi Dermawan²

The relationship between bacterial characteristics and mortality in diabetic foot ulcers' patients admitted to Dr. H. Abdul Moeloek General Hospital, Lampung
Iswandi Darwis¹, Gusti Ngurah P Pradnya Wisnu², Sekar Mentari²

Epidemiology of pelvic fracture in the emergency room at Dr. Soetomo General Hospital between 2016-2018
Yuga Rahmadana¹, M. Zaim Chilmi¹

Comparison of subjective and functional results on the operative and non-operative application of clavicle fractures
Haris Dwi Khoirur Rofiq¹, Erwin Ramawan¹

A biomechanical comparison of midshaft clavicle plate fixation between two screws and three screws on each side of the fractures
Naufal Ranadi Firas¹, Erwin Ramawan²

The success of glaucoma therapy in diabetes mellitus and non-diabetes mellitus
Nur Shani Meida¹, Ahmad Ikliluddin², Yunani Setyandriana³, Ilma Naafisa Anthrasita⁴

Shallot (*Allium cepa* L.) skin ethanol extract neutralizes liver oxidative stress in diazinon-induced Wistar rats
Shahifa Audy Rahima¹, Rosita Dewi², Nindya Shinta Rusmatika³, Dina Helianti²

Correlation between obesity and successful ovulation induction with Clomiphene citrate
Rida Eka Setiani¹, Sri Ratna Dwiningsih^{2*}, Gadis Meinar Sari¹

The differences of parasitemia and lungs size in malaria-associated acute respiratory distress syndrome (MA-ARDS) and non-MA-ARDS in mice infected with *Plasmodium berghei* ANKA
Eka Noviya Fuzianingsih¹, Cyuzuzo Callixte², Marselaonety La'lang³, Dinda Eka Putri¹, Heny Arwati², Lucia Tri Suwanti³

Compliance in taking medication for hypertension patients listed at Healthy Indonesia Program with a Family Approach
Merry Tiyas Anggraini¹, Aisyah Lahdji², Hema Dewi Anggraheny³

Analysis of the relationship between using personal protective equipment (PPE) masks on the incidence of respiratory symptoms disorders of online motorcycle taxi drivers in Malang
Jeremi Setiawan¹, Hanna Cakrawati², Anung Putri Illahika³

The effect of ginger (*Zingiber officinale*) extract on the neutrophil level and CAT (COPD Assessment Test) scores in workers with COPD due to dust exposure
Susilo Budi Pratama^{1,2}, Yuliani Setyaningsih³, Daru Lestyanto²

Bradycardia, renal failure, shock, and hyperkalemia (BRASH) caused by AV nodal blocker: a case report of a patient with BRASH syndrome resistant to calcium administration
Sidhi Laksono^{1,2}, Ananta Siddhi Prawara³

Management and quality of life extranodal non hodgkin lymphoma of testis
Bagus Aulia Mahdi¹, Pradana Zaky Romadhon^{1*}, Ugroseno Yudho Bintoro¹, Merlyna Savitri¹, Putu Niken Ayu Amrita¹, Muhammad Noor Diansyah¹, Ami Ashriati Prayoga¹, Kartika Prahasanti²

Management and quality of life extranodal non hodgkin lymphoma of testis
Bagus Aulia Mahdi¹, Pradana Zaky Romadhon¹, Ugroseno Yudho Bintoro¹, Merlyna Savitri¹, Putu Niken Ayu Amrita¹, Muhammad Noor Diansyah¹, Ami Ashriati Prayoga¹, Kartika Prahasanti²

diterbitkan oleh:
Fakultas Kedokteran
Universitas Muhammadiyah Surabaya

2022



**QANUN
MEDIKA**
JURNAL KEDOKTERAN FKUM SURABAYA

p-ISSN. 2541-2272

e-ISSN. 2548-9526

Mental and behavioral disorders due to substances during the COVID-19 Pandemic: Prevalence, diagnosis, and management

Era Catur Prasetya¹, Kharisma Sukma Nanda², Khofifah Dwi Oktaviana³, Lens Hanin Herda Zhafirah², Lia Lisa Arista², M. Dedi Dermawan^{2*}

The relationship between bacterial characteristics and mortality in diabetic foot ulcers' patients admitted to Dr. H. Abdul Moeloek General Hospital, Lampung

Iswandi Darwis^{1*}, Gusti Ngarah P Pradnya Wisnu², Sekar Mentari²

Epidemiology of pelvic fracture in the emergency room at Dr. Soetomo General Hospital between 2016-2018

Yuga Rahmadana^{1*}, M. Zaim Chilmi¹

Comparison of subjective and functional results on the operative and non-operative application of clavicle fractures

Haris Dwi Khoirur Rofiq^{1*}, Erwin Ramawan¹

A biomechanical comparison of midshaft clavicle plate fixation between two screws and three screws on each side of the fractures

Naufal Ranadi Firas^{1*}, Erwin Ramawan²

The success of glaucoma therapy in diabetes mellitus and non-diabetes mellitus

Nur Shani Meida^{1*}, Ahmad Ikhliluddin², Yunani Setyandriana³, Ilma Naafisa Anthrasita⁴

Shallot (*Allium cepa* L.) skin ethanol extract neutralizes liver oxidative stress in diazinon-induced Wistar rats

Shahifa Audy Rahima¹, Rosita Dewi^{2*}, Nindya Shinta Rusmatika³, Dina Helianti²

Correlation between obesity and successful ovulation induction with Clomiphene citrate

Rida Eka Setiani^{1*}, Sri Ratna Dwiningsih^{2*}, Gadis Meinar Sari³

The differences of parasitemia and lungs size in malaria-associated acute respiratory distress syndrome (MA-ARDS) and non-MA-ARDS in mice infected with *Plasmodium berghei* ANKA

Eka Noviya Fuzianingsih¹, Cyuzuzo Callixte¹, Marselaonety La'lang¹, Dinda Eka Putri¹, Heny Arwati^{2*}, Lucia Tri Suwanti³

Compliance in taking medication for hypertension patients listed at Healthy Indonesia Program with a Family Approach

Merry Tiyas Anggraini^{1*}, Aisyah Lahdji², Hema Dewi Anggraheny³

Analysis of the relationship between using personal protective equipment (PPE) masks on the incidence of respiratory symptoms disorders of online motorcycle taxi drivers in Malang

Jeremi Setiawan¹, Hanna Cakrawati², Anung Putri Illahika³

The effect of ginger (*Zingiber officinale*) extract on the neutrophil level and CAT (COPD Assessment Test) scores in workers with COPD due to dust exposure

Susilo Budi Pratama^{1,2}, Yuliani Setyaningsih², Daru Lestyanto²

Bradycardia, renal failure, shock, and hyperkalemia (BRASH) caused by AV nodal blocker: a case report of a patient with BRASH syndrome resistant to calcium administration

Sidhi Laksono^{1,2*}, Ananta Siddhi Prawara³

Management and quality of life extranodal non hodgkin lymphoma of testis

Bagus Aulia Mahdi¹, Pradana Zaky Romadhon^{1*}, Ugroseno Yudho Bintoro¹, Merlyna Savitri¹, Putu Niken Ayu Amrita¹, Muhammad Noor Diansyah¹, Ami Ashriati Prayoga¹, Kartika Prahasanti²

Management and quality of life extranodal non hodgkin lymphoma of testis

Bagus Aulia Mahdi¹, Pradana Zaky Romadhon^{1*}, Ugroseno Yudho Bintoro¹, Merlyna Savitri¹, Putu Niken Ayu Amrita¹, Muhammad Noor Diansyah¹, Ami Ashriati Prayoga¹, Kartika Prahasanti²

Person in Charge

Dr.H.M. Yusuf Wibisono,Sp.P(K),FCCP

Dean of Faculty of Medicine, Muhammadiyah University of Surabaya

Editor in Chief

dr.Yelvi Levani.,M.Sc

Member of Editorial Board

Abdullah Al-Tarique.,Ph.D (Queensland University, Australia)

J.L. Nouwen, MD, Ph.D (Erasmus University Rotterdam, the Netherlands)

Prof. Murat Coskun, Md, Ph.D (IstanbulUniversitesi, Turkey)

Prof.Dr.dr.Suhartono Taat Putera.,M.S (Airlangga University, Surabaya)

Prof. Takashi Yashiro (JICHI Medical School, Japan)

Aziz Alimul Hidayat (Muhammadiyah University of Surabaya,)

Section Editor

dr.Syafarinah Nur Hidayah Akil

dr.Ayu Lidya Paramita

Layout Editor

Dede Nasrullah,S.Kep.Ns.M.Kep

Reviewer

Dr.Reny I'tishom, M.Si

Dr. dr. Muhammad Anas, Sp.OG

dr. Findra Setyaningrum, M.Sc., Ph.D

dr.Uning Marlina.,MHSM.,Sp.OG

dr.Yudith Annisa Ayu Rezkitha.,Sp.PD

dr.Kukuh Dwi Putera Hemugrahanto.,Sp.OT

dr. Afrita Amalia Laitupa, Sp.P

dr. Musa Ghuffron, MMR

dr. Muhammad Reza Utama, MHPE

dr.Hafid Algristian.,Sp.KJ

dr. Mohammad Subkhan, Sp.P

dr. Fadhol Romdhoni, M.Si

FOREWORD

Alhamdulillah, praised to Allah, Journal *Qanun Medika: Fakultas Kedokteran Universitas Muhammadiyah Surabaya* vol 06 no 01 has been published. It consists of 15 articles including 1 literature review, 3 case report and 11 research articles in the medical field. In addition, there is 1 international article from India. We would like to thanks our reviewers and editorial board members who helped us in this publication. In order to be internationalized, we only published articles written in English since July 2019. We hope that these articles can be read widely both by domestic and foreign readers.

Thank you,

Yelvi Levani, MD.,M.Sc

Editor in Chief

Address

Faculty of Medicine

Muhammadiyah University of Surabaya

Jl.Sutorejo 59 Surabaya 60113

Telp.031-3811966 fax031-3813096Email:
qanunmedika@um-surabaya.ac.id

Bank account

Qanun Medika

Bank Jatim cabang Dr.Soetomo

Bank account number 032305544





QANUN MEDIKA

JURNAL KEDOKTERAN FK UM SURABAYA

<http://journal.um-surabaya.ac.id/index.php/qanunmedika>



Research Article

Shallot (*Allium cepa* L.) skin ethanol extract neutralizes liver oxidative stress in diazinon-induced Wistar rats

Shahifa Audy Rahima¹, Rosita Dewi^{2*}, Nindya Shinta Rusmatika³, Dina Helianti²

- 1) Faculty of Medicine, University of Jember, Jl. Kalimantan No. 37 Kampus Tegalboto, Jember, 68121, East Java, Indonesia.
- 2) Histology Department, Faculty of Medicine, University of Jember, Jl. Kalimantan No. 37 Kampus Tegalboto, Jember, 68121, East Java, Indonesia.
- 3) Anatomic Pathology Department, Faculty of Medicine, University of Jember, Jl. Kalimantan No. 37 Kampus

ARTICLE INFO

Submitted : 24th March 2021
Accepted : 2nd August 2021
Published : 25th January 2022

Keywords:

antioxidant, diazinon, Kupffer cell, liver, MDA, shallot

***Correspondence:**

rosita.fk@unej.ac.id

*This is an Open acces article
under the CC-BY license*



ABSTRACT

Diazinon has a hepatotoxic effect since it is metabolized in the liver involving Kupffer cells (KCs) activation, increasing reactive oxygen species (ROS). The flavonoids contained in shallot (*Allium cepa* L.) skin act as antioxidants neutralizing oxidative stress. This study aims to determine the effect of shallot skin ethanol extract (SSEE) on liver MDA level and activated KCs histopathology. The total flavonoids level of SSEE was measured using the aluminum chloride colorimetric method and resulted in 228.1 mg QE/g. Rats were divided into normal, diazinon, and SSEE groups. Diazinon was administered at a dose of 40 mg/kg b.w. for 7 days, followed by SSEE at the dose of 600, 900, and 1,200 mg/kg b.w. for 7 days. Liver malondialdehyde (MDA) level was measured using the MDA-TBA method. The results revealed that diazinon increased liver MDA level ($p < 0.05$), while SSEE at doses of 900 and 1,200 mg/kg b.w. decreased liver MDA level equal to normal ($p > 0.05$). Activated KCs in the SSEE group at a dose of 1,200 mg/kg b.w. was impressively equal to the normal group. In conclusion, SSEE at dose of 1,200 mg/kg b.w. neutralize liver oxidative stress due to diazinon indicated by the decrease of liver MDA level and activated KCs equal to normal.



QANUN MEDIKA

JURNAL KEDOKTERAN FK UM SURABAYA

<http://journal.um-surabaya.ac.id/index.php/qanunmedika>



INTRODUCTION

Diazinon is an organophosphate pesticide that is widely used by farmers. The usage of diazinon has been banned in the USA since 2004 because it endangers human health. Nevertheless, Indonesian farmers still use diazinon to get rid of pests in order to increase crop productivity (Agency for Toxic Substance and Disease Registry (ATSDR), 2018; Direktorat Pupuk dan Pestisida, 2016). It is estimated that at least 200,000 people worldwide die because of organophosphate poisoning each year (Eddleston, et al., 2008). In 2008, in the amount of 76.47% of all respondents at Sumberejo, Magelang got the decrease of blood acetylcholinesterase level indicating organophosphate poisoning. It happened through ingestion, inhalation, or absorption (Utami, Dangiran, & Darundiati, 2017).

Diazinon has a hepatotoxic effect related to the liver as the main site of its metabolism. It increases free radicals in liver tissue and decreases endogenous antioxidants amount and capacity (Elsersek & Filipic, 2011). The previous studies revealed that diazinon increased liver malondialdehyde (MDA). Diazinon also attenuated liver function showed by the increase of alanine transaminase (ALT), aspartate transaminase (AST), and total bilirubin. It induced liver structure damage such as rupture in hepatocytes, vacuole formation in the cytoplasm, necrosis, enlargement of sinusoids, and blood vessel congestion with hemorrhage (Al-Attar, Elnaggar, & Almalki, 2017; Wisudanti, Herdiana, & Qodar, 2019).

One of the cells playing a crucial role in liver homeostasis and the pathogenesis of liver injury are Kupffer cells (KCs) (Kolios, et al., 2006; Owumi et al., 2014). KCs are non-parenchymal liver cells, approximately 15% of the total liver cells, and located in the

sinusoidal lining of the liver. They constitute the resident tissue macrophage in the liver and 80-90% of the tissue macrophages in the reticuloendothelial system (Dixon et al., 2013; Kolios et al., 2006). They are the first-line defense to be exposed to substances absorbed from the gastrointestinal tract. They eliminate and detoxify foreign pathogens such as toxic agents (Kolios et al., 2006). Toxic agents-induced liver injury releases various signaling molecules activating KCs, which are capable of generating ROS production (Gandhi, 2012; Kolios et al., 2006; Nguyen-Lefebvre & Horuzsko, 2015; Sato et al., 2016).

The increase of free radicals caused by diazinon and KCs activation can be neutralized by antioxidants contained in plants such as shallot (*Allium cepa* L.). The flavonoid quercetin is actually found at the highest level on its skin. Isolated quercetin of shallot skin has 3-5 times higher levels than the edible part (Skerget, et al., 2009). Jung, et al. (2011) reported that quercetin in shallot skin decreased liver MDA level in streptozotocin-induced rats. Nonetheless, consumption of shallot skin is still uncommon, and it is only considered as household and industrial waste.

Flavonoids contained in shallot skin have an essential role as an antioxidant by reducing ROS production related to its scavenging capacity (Vásquez-Espinal et al., 2019). We used liver MDA level as a parameter to represent the effectivity of flavonoids to decline free radicals in the liver because of its presence as the final product of lipid peroxidation. MDA level is also more accurate to measure since it has a longer half-life and stable structure than the other free radicals (Suryadinata, Bambang, & Adriani, 2017). There has not been a study analyzing the effect of shallot skin on liver oxidative stress due to diazinon. Based on the explanation above, the researcher is implicated in determining the antioxidant effect of shallot



QANUN MEDIKA

JURNAL KEDOKTERAN FK UM SURABAYA

<http://journal.um-surabaya.ac.id/index.php/qanunmedika>



skin ethanol extract (SSEE) on the liver MDA level and activated KCs histopathology in diazinon-induced Wistar rats.

METHODS

The Preparation of *Simplicia* and SSEE

The shallot skin was elicited from the industrial waste of the fried shallot factory located at Silo, Jember. The variety/species of shallot determined by the Botanical Laboratory of Math and Science Faculty, University of Jember was Biru Lancor (*Allium cepa* L. var. *ascalonicum* Back). The shallot skin was washed using NaCl 2% and subsequently sun-dried. The dried shallot skin was ground to get *Simplicia* powder. A total of 600 g of *Simplicia* powder was put into a jar, and 3 L of 96% ethanol was added and soaked for the first 24 hours with occasional stirring. The filtrate was separated from its solvent by filtration paper. The process was repeated three times. The total filtrate was concentrated using a rotary evaporator at a temperature of 60°C (Elsyana & Tutik, 2018).

The Measurement of Total Flavonoids Level

Chemical Analysis Service Unit measured total flavonoids level, the University of Jember with analysis number registration 02/CASU/III/2021 using aluminium chloride colorimetric method according to the method of Chang et al. (2002). Quercetin was used as standard to calculate the calibration plot ($y = 0.0834x + 0.0107$, $R^2 = 0.998$).

Animals and Treatment

As a research subject, 25 male Wistar rats aged 2-3 months and bodyweight 150-250 g were randomly divided into five groups consisting of normal, diazinon, and SSEE groups. On days 1 to 7, the normal group was administered corn oil orally, while the rest of the groups were administered diazinon 40 mg/kg b.w orally. On days 8 to 14, the normal and diazinon group received DMSO 3% orally, and the treatment

groups received SSEE 600, 900, and 1,200 mg/kg b.w. Orally, respectively. The surgical procedure was carried out immediately to take the liver out for MDA level measurement and histopathological slides preparation. The study was approved by The Ethical Committee for Research, Faculty of Medicine, the University of Jember, with reference number 1465/H.25.1.11/KE/2021.

The Measurement of Liver MDA Level

Liver MDA level was measured using thiobarbituric acid. The liver was washed using Phosphate Buffer Saline (PBS), pH 7.4. As much as 1 g of liver tissue was homogenized with 1 mL of ice-cold NaCl using cold mortar, followed by centrifugation 6000 rpm for 30 minutes. An amount of 550 μ L sterile aquadest, 100 μ L TCA, 250 μ L HCl 1 M, and 100 μ L Na-Thiobarbiturat was added to 100 μ L supernatant of each sample. The mixture was boiled for 20 minutes and chilled at room temperature. All samples were centrifugated 500 rpm for 10 minutes to get rid of precipitation before being measured at 532 nm wavelength. Liver MDA level was calculated using linear regression equation obtained from a series of standard solution 2.5, 5, 10, 20, and 40 nmol/mL ($y = 66.798x - 6.9041$, $R^2 = 0.9981$) and expressed in nmol MDA per mg liver tissue.

Statistical Analysis

The data of liver MDA level was displayed as mean \pm standard deviation. Statistical analysis was performed using the One Way Anova test to analyze the difference between groups, followed by the Least Significant Difference (LSD) post hoc test to analyze the difference of each group compared to others.

Activated KCs Histopathology

The right lobes were soaked in 10% neutral buffer formalin then processed with paraffin. They were cut using microtome with a thickness



of 3-5 microns then stained using hematoxylin-eosin (HE) for microscopic observation. Liver histopathological slides were observed using LEICA DM500 binocular microscope with a magnification of 400X in five fields of view. The qualitative assessment was focused on activated KCs related to the increase of ROS.

RESULTS

Liver MDA Level

The result of the total flavonoids level of SSEE is shown in Table 1. Total flavonoids level was expressed in mg/g in terms of quercetin equivalent (QE).

The mean liver MDA level is presented in Table 2. The highest mean of liver MDA level was found in the diazinon group, while the lowest mean of liver MDA level was found in the normal group. Among the SSEE groups, the lowest mean liver MDA level was found at a dose of 1,200 mg/kg b.w.

One Way Anova test revealed that liver MDA

level was different among groups ($p < 0.05$). Diazinon group showed a higher liver MDA level compared to a normal group, yet it was lower in SSEE groups at doses of 900 and 1,200 mg/kg b.w. It was compared to the diazinon group ($p < 0.05$) and equal to the normal group ($p > 0.05$).

Activated KCs Histopathology

The liver histopathological slides demonstrating activated KCs of each group are presented in Figure 1. Inactivated KCs only showed dense and squamous nuclei; thus, it is difficult to distinguish with endothelial cells. Activated KCs had a wide range of variability in cell shape and size, elongated cytoplasmic processes, and open-face type cells. They were found along the sinusoid and could be observed in contact with other KCs, collagen fibers, and endothelial cells (Basit, Tan, & Webster, 2020). Activated KCs were mostly found in diazinon group; the higher the SSEE dose, the fewer the activated KCs; and activated KCs in the SSEE group at a dose of 1,200 mg/kg b.w. was impressively equal to the normal group.

Table 1. Total flavonoids level

Tested for	Sample code	Test result (mg QE/g extract)
Total flavonoids analysis	SSEE	228.1

Table 2. The mean of liver MDA level

Groups	Mean of liver MDA level \pm SD (nmol/mg)
Normal	11.80 \pm 2.92 ^b
Diazinon	22.17 \pm 5.24 ^a
SSEE 600 mg/kg b.w.	18.39 \pm 4.74 ^a
SSEE 900 mg/kg b.w.	13.46 \pm 4.29 ^b
SSEE 1,200 mg/kg b.w.	13.32 \pm 3.13 ^b

^aSignificant compared to normal group ($p < 0.05$), ^bSignificant compared to diazinon group ($p < 0.05$)

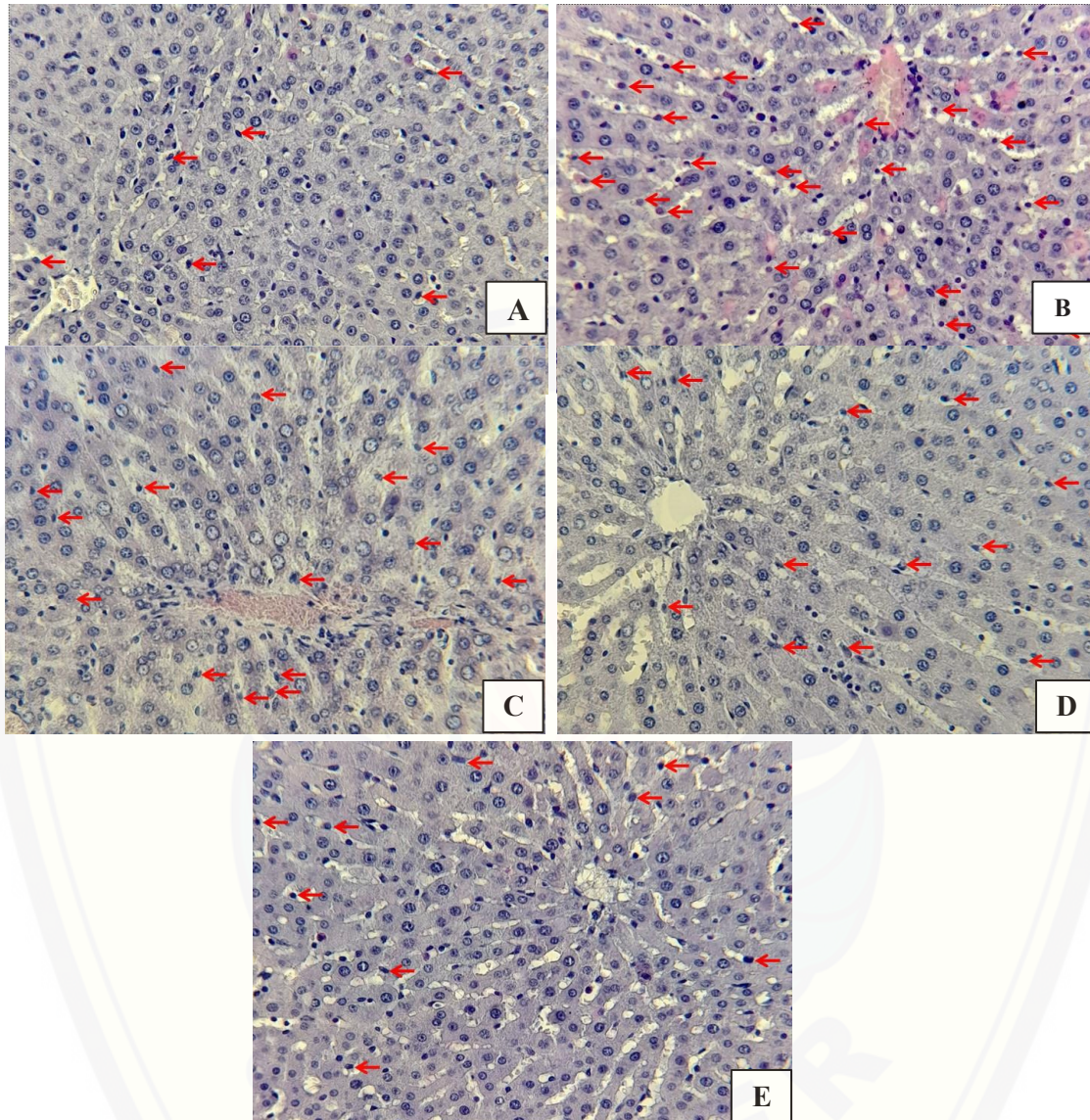


Figure 1. Activated KCs histopathology. A: normal group. B: diazinon group. C: SSEE 600 mg/kg b.w. D: SSEE 900 mg/kg b.w. E: SSEE 1,200 mg/kg b.w. Red arrow shows activated KCs.



QANUN MEDIKA

JURNAL KEDOKTERAN FK UM SURABAYA

<http://journal.um-surabaya.ac.id/index.php/qanunmedika>



DISCUSSION

The administration of diazinon at a dose of 40 mg/kg b.w. for 7 days could significantly increase liver MDA level. A previous study revealed that diazinon 40 mg/kg b.w. administered to rats for 5 days significantly increased liver MDA level (Himah, Wisudanti, & Fatmawati, 2018). Another study reported that diazinon 50 mg/kg b.w. administered to rats for 6 weeks caused liver failure not only indicated by the increase of ALT, AST, total bilirubin, and MDA levels, but also the change of liver histopathological features (Al-Attar et al., 2017)

Diazinon gains the level of free radicals which initiate lipid peroxidation. Diazinon is oxidized to free diazoxon and sulfur atoms by cytochrome P450 (CYP) (Elersek & Filipic, 2011). Diazoxon is a metabolite inhibiting acetylcholinesterase, so that it produces nitric oxide radical (NO•), one of the free radicals formed through the activation of NMDA receptor (Zhao, Vanhoutte, & Leung, 2015). Diazoxon is hydrolyzed by paraoxonase (PON1) to diethyl compounds which can react rapidly with reactive hydroxyl radical group (•OH), resulting in a new free radical (Elersek & Filipic, 2011). Free sulfur atom as a secondary metabolite of diazinon will also bind proton to form H₂S molecule interacting with metalloenzyme such as superoxide dismutase (SOD) then inhibiting its activity (J. Lee, Koo, & Min, 2004). The decrease of antioxidant enzymes inhibits the catalyzation of superoxide-free radical (•O₂⁻) to oxygen (O₂) and hydrogen peroxide (H₂O₂) (Cemeli, Baumgartner, & Anderson, 2009). Excessive free radicals trigger oxidative stress and lipid peroxidation. Lipid peroxidation occurs when polyunsaturated fatty acids (PUFA) in cell membranes or organelle membranes are degraded by free radicals producing lipid hydroperoxide, lipid peroxy radicals, and MDA as the final product (Ayala, Muñoz, & Argüelles, 2014). In this study, activated KCs

were mostly found in diazinon group. KCs are the vital component of the macrophages and specific to the hepatic response to pathogens (Dixon et al., 2013). They are located in sinusoid so that they efficiently phagocytize pathogens entering from the portal circulation (Dixon et al., 2013; Kolios et al., 2006; Sato et al., 2016). KCs are activated by signaling molecule such as interferon-gamma (IFN-γ). When IFN-γ binds to its receptor on macrophages, the signal transducers and activators of transcription 1 (STAT1) and interferon regulatory factors (IRF) are activated, which subsequently cause the activation of KCs (Nguyen-Lefebvre & Horuzsko, 2015). Activated KCs are not only characterized by a high capacity to present antigen, high expression, and secretion of interleukin-12 (IL-12), interleukin-23 (IL-23), and IRF-5, but also high production of NO and ROS as a defense against the toxic agent. Therefore, KCs are capable of generating ROS production (Gandhi, 2012; Kolios et al., 2006; Nguyen-Lefebvre & Horuzsko, 2015; Sato et al., 2016). This theory is supported by Owumi et al. (2014) which stated that KCs depletion reduced cytokines secretion and ROS production, consequently resulting in the amelioration of ethanol-induced liver damage.

The shallot skin contains flavonoids which potentially act as an antioxidant (Mardiah et al., 2017). Shi et al. (2016) isolated flavonoids from dry onion (*Allium Cepa* L.) skin. The flavonoids in NaHCO₃ components of diethyl ether phase were isorhamnetin, quercetin, and kaempferol; the Na₂CO₃ component of diethyl ether phase was quercetin-3-O-β-D-glucopyranoside; the Na₂CO₃ components of ethyl acetate phase were rutin and quercetin; the NaHCO₃ components of ethyl acetate phase were apigenin-7-O-β-D-glucopyranoside and kaempferol-7-O-β-D-glucopyranoside. Our phytochemical screening showed the total flavonoids level of SSEE was 228.1 mg QE/g. Thus, it should be equivalent to 136.86, 205, and 273 mg QE/kg b.w. total flavonoids for each SSEE group, respectively.



QANUN MEDIKA

JURNAL KEDOKTERAN FK UM SURABAYA

<http://journal.um-surabaya.ac.id/index.php/qanunmedika>



The first dose of SSEE could not decrease liver MDA level significantly, yet the second and the third doses of SSEE could decrease liver MDA level significantly equal to normal. The response to flavonoid compound is dose-dependent, so that the different doses will result in the different activity of flavonoid in decreasing free radicals (Carmona-Aparicio et al., 2019). Ahmed et al. (2017), investigating the effect of SSEE on liver oxidative stress on CCl₄-induced rats, stated that liver MDA level was influenced by the dose of SSEE. SSEE at a dose of 50 mg/kg b.w. for 17 days could not alleviate liver MDA level while it was significantly decreased at a dose of 100 mg/kg b.w. There were several previous studies adding shallot skin in the rat's diet. The consumption of a diet with 5% shallot skin powder for 4 weeks could significantly decrease liver MDA level and increase SOD, glutathione peroxidase (GSH-Px), and glutathione reductase (GSH-Rx) levels in rats that have an aging process (B. Lee, Jung, & Kim, 2012). The administration of SSEE 1% in the total diet for 8 weeks could significantly decrease liver MDA level on streptozotocin-induced liver injury in rats (Jung et al., 2011).

Quercetin and quercetin 4'-O- β -glucopyranoside constitute the major part of flavonoids in shallot skin compared to others (AbouZid & Elsherbeiny, 2008). The content of flavonoid quercetin in shallot skin is 3-5 times higher than in its bulb (Skerget et al., 2009). A previous study stated that flavonoid quercetin at the dose of 200 mg/kg b.w. could reduce muscle MDA level significantly from ischemia-reperfusion injury in rats (Akdemir et al., 2016). Quercetin decreases the free radical level through radical scavenging mechanisms in its redox reaction, such as hydrogen atom transfer (HAT), sequential proton loss electron transfer (SPLET), and electron transfer-proton transfer (ET-PT) (Vásquez-Espinal et al., 2019). Additionally, quercetin regulates the

endogenous antioxidants by modulating the expression of A549 genes, directly increasing the enzyme antioxidants such as GSH-Px, GSH-Rx, and SOD (Boadi, Amartey, & Lo, 2016; Zerín et al., 2013). Thereby, those mechanisms prevent the initial stage of lipid peroxidation (Ayala et al., 2014).

The qualitative assessment of KCs showed the higher the SSEE dose, the fewer activated KCs. SSEE at dose of 1,200 mg/kg b.w. impressively reduced activated KCs equal to the normal group. In this study, SSEE was administered after diazinon induction aimed to analyze its therapeutic effect. Quercetin in SSEE is thought to neutralize the free radical sources mainly derived from diazoxon and the damage of hepatocytes as the result of lipid peroxidation. Hence, the KC's environmental stressors are diminished, and KCs are not further activated. Padma et al. (2012) reported that quercetin decreased hepatic serum markers and MDA as well as improved liver histopathological alteration caused by lindane pesticide toxicity in rats. Hassan, Abo El-Ela, & Abdel-Aziz (2019) stated that quercetin decreases the level of ALT and AST by restoring the histopathological architecture of the liver in imidacloprid insecticide induction in rats. In the other organ, Kalender et al. (2012) showed that the antioxidant effect of quercetin reduced testis MDA level and exhibited milder testis histopathological alterations.

The limitation of this study is that the doses of SSEE are less varied, so that the optimal dose can not be determined. Further research using a wider range of doses is needed to establish the optimal dose of SSEE in neutralizing liver oxidative stress caused by diazinon.

CONCLUSION

In conclusion, SSEE at dose of 1,200 mg/kg b.w. neutralize liver oxidative stress due to diazinon indicated by the decrease of liver MDA level and activated KCs equal to normal.



QANUN MEDIKA

JURNAL KEDOKTERAN FK UM SURABAYA

<http://journal.um-surabaya.ac.id/index.php/qanunmedika>



REFERENCES

- AbouZid, S. F., & Elsherbeiny, G. M. (2008). Increase in flavonoids content in red onion peel by mechanical shredding. *Journal of Medicinal Plants Research*, 2(9), 258–260.
- Agency for Toxic Substance and Disease Registry (ATSDR). (2018). Toxological Profiles for Diazinon. Retrieved October 8, 2020, from <https://www.atsdr.cdc.gov/toxprofiles/tp.asp?id=512&tid=90>
- Ahmed, A. F., Al-Yousef, H. M., Al-Qahtani, J. H., & Al-Said, M. S. (2017). A hepatonephro-protective phenolic-rich extract from red onion (*Allium cepa* L.) peels. *Pakistan Journal of Pharmaceutical Sciences*, 30(5), 1971–1979.
- Akdemir, F. N. E., Gülçin, İ., Karagöz, B., & Soslu, R. (2016). Quercetin protects rat skeletal muscle from ischemia reperfusion injury. *Journal of Enzyme Inhibition and Medicinal Chemistry*, 31, 162–166. <https://doi.org/10.1080/14756366.2016.1193735>
- Al-Attar, A. M., Elnaggar, M. H. R., & Almalki, E. A. (2017). Protective effect of some plant oils on diazinon induced hepatorenal toxicity in male rats. *Saudi Journal of Biological Sciences*, 24(6), 1162–1171. <https://doi.org/10.1016/j.sjbs.2016.10.013>
- Ayala, A., Muñoz, M. F., & Argüelles, S. (2014). Lipid peroxidation: Production, metabolism, and signaling mechanisms of malondialdehyde and 4-hydroxy-2-nonenal. *Oxidative Medicine and Cellular Longevity*, 2014, 360438. <https://doi.org/10.1155/2014/360438>
- Basit, H., Tan, M. L., & Webster, D. R. (2020). Histology, Kupffer Cell. In *StatPearls*. Treasure Island: StatPearls Publishing. Retrieved from <https://www.ncbi.nlm.nih.gov/books/NBK493226/>
- Boadi, W. Y., Amartey, P. K., & Lo, A. (2016). Effect of quercetin, genistein and kaempferol on glutathione and glutathione-redox cycle enzymes in 3T3-L1 preadipocytes. *Drug and Chemical Toxicology*, 39(3), 239–247. <https://doi.org/10.3109/01480545.2015.1082135>
- Carmona-Aparicio, L., Cárdenas-Rodríguez, N., Delgado-Lamas, G., Pedraza-Chaverri, J., Montesinos-Correa, H., Rivera-Espinosa, L., ... Coballase-Urrutia, E. (2019). Dose-Dependent Behavioral and Antioxidant Effects of Quercetin and Methanolic and Acetonic Extracts from *Heterotheca inuloides* on Several Rat Tissues following Kainic Acid-Induced Status Epilepticus. *Oxidative Medicine and Cellular Longevity*, 2019, 5287507. <https://doi.org/10.1155/2019/5287507>
- Cemeli, E., Baumgartner, A., & Anderson, D. (2009). Antioxidants and the Comet assay. *Mutation Research - Reviews in Mutation Research*, 681(1), 51–67. <https://doi.org/10.1016/j.mrrev.2008.05.002>
- Chang, C. C., Yang, M. H., Wen, H. M., & Chern, J. C. (2002). Estimation of total flavonoid content in propolis by two complementary colometric methods. *Journal of Food and Drug Analysis*, 10(3), 178–182. <https://doi.org/10.38212/2224-6614.2748>
- Direktorat Pupuk Dan Pestisida. (2016). *Pestisida Pertanian dan Kehutanan Tahun 2016*. Jakarta: Kementerian Pertanian Republik Indonesia.
- Dixon, L., Barnes, M. B., Tang, H., Pritchard, M. T., & Nagy, L. E. (2013). Kupffer Cells in the Liver. *Physiology & Behavior*, 176(1), 139–148. <https://doi.org/10.1002/cphy.c120026>.Kupffer



QANUN MEDIKA

JURNAL KEDOKTERAN FK UM SURABAYA

<http://journal.um-surabaya.ac.id/index.php/qanunmedika>



- Eddleston, M., Buckley, N. A., Eyer, P., & Dawson, A. H. (2008). Management of acute organophosphorus pesticide poisoning. *The Lancet*, Vol. 371, pp. 597–607. [https://doi.org/10.1016/S0140-6736\(07\)61202-1](https://doi.org/10.1016/S0140-6736(07)61202-1)
- Elersek, T., & Filipic, M. (2011). Organophosphorous Pesticides - Mechanisms of Their Toxicity. In I. T. Europe (Ed.), *Pesticides - The Impacts of Pesticides Exposure*. Rijeka. <https://doi.org/10.5772/14020>
- Elsyana, V., & Tutik. (2018). Penapisan Fitokimia dan Skrining Toksisitas Ekstrak Etanol Kulit Bawang Merah. *Jurnal Farmasi Malahayati*, 1(2), 107–114.
- Gandhi, C. R. (2012). Oxidative Stress and Hepatic Stellate Cells: A PARADOXICAL RELATIONSHIP. *Trends in Cell & Molecular Biology*, 7(412), 1–10.
- Hassan, A. moniem S., Abo El-Ela, F. I., & Abdel-Aziz, A. M. (2019). Investigating the potential protective effects of natural product quercetin against imidacloprid-induced biochemical toxicity and DNA damage in adults rats. *Toxicology Reports*, 6(July), 727–735. <https://doi.org/10.1016/j.toxrep.2019.07.007>
- Himah, S. A., Wisudanti, D. D., & Fatmawati, H. (2018). Effect of Soyflour (*Glycine max L.*) Hepatoprotector Activity on Liver MDA Level in Male Wistar Rat Induced by Diazinon. *Journal of Agromedicine and Medical Sciences*, 4(1), 1–6. <https://doi.org/10.19184/ams.v4i1.6857>
- Jung, J. Y., Lim, Y., Moon, M. S., Kim, J. Y., & Kwon, O. (2011). Onion peel extracts ameliorate hyperglycemia and insulin resistance in high fat diet/streptozotocin-induced diabetic rats. *Nutrition and Metabolism*, 8(1). <https://doi.org/10.1186/1743-7075-8-18>
- Kalender, Y., Kaya, S., Durak, D., Uzun, F. G., & Demir, F. (2012). Protective effects of catechin and quercetin on antioxidant status, lipid peroxidation and testis-histoarchitecture induced by chlorpyrifos in male rats. *Environmental Toxicology and Pharmacology*, 33(2), 141–148. <https://doi.org/10.1016/j.etap.2011.12.008>
- Kolios, G., Valatas, V., & Kouroumalis, E. (2006). Role of Kupffer cells in the pathogenesis of liver disease. *World Journal of Gastroenterology*, 12(46), 7413–7420. <https://doi.org/10.3748/wjg.v12.i46.7413>
- Lee, B., Jung, J. H., & Kim, H. S. (2012). Assessment of red onion on antioxidant activity in rat. *Food and Chemical Toxicology*, 50(11), 3912–3919. <https://doi.org/10.1016/j.fct.2012.08.004>
- Lee, J., Koo, N., & Min, D. B. (2004). Reactive Oxygen Species, Aging, and Antioxidative Nutraceuticals. *Comprehensive Reviews in Food Science and Food Safety*, 3(1), 21–33. <https://doi.org/10.1111/j.1541-4337.2004.tb00058.x>
- Mardiah, N., Mulyanto, C., Amelia, A., Lisnawati, L., Anggraeni, D., & Rahmawanty, D. (2017). Penentuan Aktivitas Antioksidan dari Ekstrak Kulit Bawang Merah dengan Metode DPPH. *Jurnal Pharmascience*, 4(2). <https://doi.org/10.20527/jps.v4i2.5768>
- Nguyen-Lefebvre, A. T., & Horuzsko, A. (2015). Kupffer Cell Metabolism and Function. *J Enzymol Metab.*, 1(1), 1–26.
- Owumi, S. E., Corthals, S. M., Uwaifo, A. O., Kamendulis, L. M., & Klaunig, J. E. (2014). Depletion of Kupffer cells modulates ethanol-induced hepatocyte DNA synthesis in C57Bl/6 mice. *Environmental Toxicology*, 29(8), 867–875. <https://doi.org/10.1002/tox.21814>



QANUN MEDIKA
JURNAL KEDOKTERAN FK UM SURABAYA
<http://journal.um-surabaya.ac.id/index.php/qanunmedika>



- Padma, V. V., Baskaran, R., Roopesh, R. S., & Poornima, P. (2012). Quercetin attenuates lindane induced oxidative stress in wistar rats. *Molecular Biology Reports*, 39(6), 6895–6905. <https://doi.org/10.1007/s11033-012-1516-0>
- Sato, K., Hall, C., Glaser, S., Francis, H., Meng, F., & Alpini, G. (2016). Pathogenesis of Kupffer Cells in Cholestatic Liver Injury. *American Journal of Pathology*, 186(9), 2238–2247. <https://doi.org/10.1016/j.ajpath.2016.06.003>
- Shi, G. Q., Yang, J., Liu, J., Liu, S. N., Song, H. X., Zhao, W. E., & Liu, Y. Q. (2016). Isolation of flavonoids from onion skin and their effects on K562 cell viability. *Bangladesh Journal of Pharmacology*, 11, 18–25. <https://doi.org/10.3329/bjp.v11iS1.26419>
- Skerget, M., Majhenic, L., Bezjak, M., & Knez, Z. (2009). Antioxidant, radical scavenging and antimicrobial activities of red onion (*Allium cepa* L) skin and edible part extracts. *Chemical and Biochemical Engineering Quarterly*, 23(4), 435–444.
- Suryadinata, R. V., Bambang, W., & Adriani, M. (2017). Efektivitas Penurunan Malondialdehyde dengan Kombinasi Suplemen Antioksidan Superoxide Dismutase Melondan Gliadin Akibat Paparan Rokok. *Global Medical and Health Communication*, 5(2), 79–83.
- Utami, D. P., Dangiran, H. L., & Darundiati, Y. H. (2017). Hubungan Paparan Pestisida Organofosfat Dengan Laju Endap Darah (Led) Pada Petani Di Desa Sumberejo Kecamatan Ngablak Kabupaten Magelang (Association Between Exposure Organophosphate Pesticides With Erythrocyte Sedimentation Rate (Esr) Among Farmers in De. *Jurnal Kesehatan Masyarakat (e-Journal)*, 5(3).
- Vásquez-Espinal, A., Yañez, O., Osorio, E., Areche, C., García-Beltrán, O., Ruiz, L. M., ... Tiznado, W. (2019). Theoretical Study of the Antioxidant Activity of Quercetin Oxidation Products. *Frontiers in Chemistry*, 7(818). <https://doi.org/10.3389/fchem.2019.00818>
- Wisudanti, D. D., Herdiana, F., & Qodar, T. S. (2019). Diazinon Toxicity to Kidney and Liver of Wistar Male Rats in terms of Biochemical and Histopathological Parameters. *Journal of Agromedicine and Medical Sciences*, 5(2), 112–117. <https://doi.org/10.19184/ams.v5i2.11575>
- Zerin, T., Kim, Y. S., Hong, S. Y., & Song, H. Y. (2013). Quercetin reduces oxidative damage induced by paraquat via modulating expression of antioxidant genes in A549 cells. *Journal of Applied Toxicology*, 33(12), 1460–1467. <https://doi.org/10.1002/jat.2812>
- Zhao, Y., Vanhoutte, P. M., & Leung, S. W. S. (2015). Vascular nitric oxide: Beyond eNOS. *Journal of Pharmacological Sciences*, 129(2), 83–94. <https://doi.org/10.1016/j.jphs.2015.09.002>