

KARYA ILMIAH:
JURNAL INTERNASIONAL

Amyand's hernia associated with mesenteric chylous cyst in infant:
a rare case report

dr. Supangat M.Kes., Ph.D Sp.BA

NIP. 197304241999031002

- Tenaga Pengajar Bagian Paraklinik
Fakultas Kedokteran Universitas Jember

**KEMENTERIAN RISET, TEKNOLOGI, DAN
PENDIDIKAN TINGGI
UNIVERSITAS JEMBER**




Karya Ilmiah Diterbitkan Pada Jurnal Internasional :

BMC Surgery ISSN 1471-2482

Springer Nature. (2020). 20, 309

 **BMC** *Series*

BMC Gastroenterology



ISSN 1543-2114
CODEN BCGA

Editorial Board

Editor

[Lisa Heinke](#), *BMC Series*

Assistant Editor

[Jashan Abraham](#), *BMC Series*

Systematic Reviews Editor

Mohammad Yaghoobi, *McMaster University, Canada*

Senior Editorial Board Members

Quirino Lai, *Sapienza University of Rome, Italy*

Peter Lakatos, *McGill University Health Center, Canada*

Yeong Yeh Lee, *Universiti Sains Malaysia, Malaysia*

Bárbara Peleteiro, *University of Porto Medical School, Portugal*

Vishal Sharma, *Post Graduate Institute of Medical Education and Research, India*

Editorial Board Members

Colorectal cancer

Andrew Beggs, *University of Birmingham, UK*

Luis Carvajal Carmona, *University of California, Davis, USA*

Joaquín Cubiella, *Hospital Universitario de Ourense, Spain*

Mitsuru Esaki, *Department of Medicine and Bioregulatory Science, Graduate School of Medicine, Kyushu University, Japan*

Shiki Fujino, *Osaka University, Japan*

Jennifer Hardingham, *The Queen Elizabeth Hospital, Australia*

Stephan Hollerbach, *AKC Celle, Germany*

Leonardo Lino-Silva, *National Cancer Institute (Mexico), Mexico*

Norikatsu Miyoshi, *Osaka Medical Center for Cancer and Cardiovascular Disease, Japan*

Dominik Modest, *LMU Munich, Germany*

Mala Pande, *MD Anderson Cancer Center, USA*

Barbara Pardini, *Academy of Sciences, Czech Republic*

Amitesh Roy, *Flinders University, Australia*

Alexander Stein, *University Cancer Center Hamburg, Germany*

Epidemiology of gastroenterological disorders

Lei Huang, *German Cancer Research Center (DKFZ), Germany*

Alfredo Larrosa-Haro, *University of Guadalajara, Mexico*

Tatsuki Mizuochi, *Kurume University, Japan*

Alan Moss, *Beth Israel Deaconess Medical Center, USA*

Madunil Niriella, *Faculty of Medicine, University of Kelaniya, Sri Lanka*

Daniele Piovani, *Humanitas University, Italy*

Gholamreza Roshandel, *Golestan University of Medical Sciences, Iran*
Leo van Rossum, *Dutch Health Council, Netherlands*

Gastroesophageal disorders

Amin Talebi Bezmin Abadi, *Tarbiat Modares University, Iran*
Stavros A Antoniou, *University of Heraklion, Grece*
Chang Seok Bang, *Hallym University College of Medicine, Korea, Republic of*
Nicola de Bortoli, *University of Pisa, Italy*
Osvaldo Borrelli, *Great Ormond Street Hospital, UK*
Shiyao Chen, *Zhongshan Hospital, Fudan University, China*
King-Wah Chiu, *Kaohsiung Chang Gung Memoiral Hospital, Taiwan*
Seng-Kee Chuah, *Chang Gung University College of Medicine, Taiwan*
Chen Shuan Chung, *Far Eastern Memorial Hospital, Taiwan*
Luigi L Corvaglia, *S Orsola Malpighi Hospital, Italy*
Ram Dickman, *RMC, Israel*
Dan Dumitrascu, *Iuliu Hatieganu University of Medicine and Pharmacy Cluj-Napoca, Romania*
Leonardo Henry Eusebi, *University of Bologna, Italy, Italy*
Matteo Fassan, *University of Padua, Italy*
Craig Friesen, *Children's Mercy Kansas City, USA*
Noriyuki Hirahara, *Shimane University Faculty of Medicine, Japan*
Shiaw-Hooi Ho, *University of Malaya, Malaysia*
Qin Huang, *Harvard Medical School, USA*
Damian Hussey, *Flinders Medical Centre, Australia*
Masahiko Inamori, *Yokohama City University, Japan*
Jingfang Ju, *Stony Brook University, USA*
Gwang Ha Kim, *Pusan National University Hospital, Pusan National University School of Medicine, Republic of Korea*
Shin-ichi Kosugi, *Uonuma Institute of Community Medicine, Niigata University Medical and Dental Hospital, Japan*
Philippe Lehours, *University Bordeaux, France*
Jiing-Chyuan Luo, *Veteran General Hospital & National Yang Ming University, Taiwan*
Samantha Morais, *Institute of Public Health of the University of Porto, Portugal*
Wayne Phillips, *Peter MacCallum Cancer Centre, Australia*
Radhakrishna Rao, *University of Tennessee Health Science Center, USA*
Efstratios Saliakellis, *Great Ormond Street Hospital for Children NHS Foundation Trust, United Kingdom*
Edoardo Savarino, *Azienda Ospedaliera Universitaria, Italy*
Traci Testerman, *University of South Carolina School of Medicine, USA*
Salvatore Tolone, *University of Campania, Italy*
Ping-Huei Tseng, *National Taiwan University Hospital, Taiwan*
Paolo Usai-Satta, *Gastroenterology Unit, Brotzu Hospital, Cagliari, Italy*
Wen-Lun Wang, *E-Da Hospital and I-Shou University, Taiwan*
Thomas Wex, *Otto-von-Guericke University, Germany*
Hyo-Joon Yang, *Sungkyunkwan University School of Medicine, South Korea*

Hepatobiliary and pancreatic disorders

Ludovico Abenavoli , *University Magna Graecia, Italy*

Gian Luigi Adani, *Academic University Hospital. Department of Surgery and Transplantation, Italy*

Filippo Antonini, *Augusto Murri Hospital, Italy*

Georg Auzinger, *King's College Hospital London & Cleveland Clinic London, UK*

Stefano Bellentani, *Clinica Santa Chiara, Switzerland*

Dimitrios Bogdanos, *University of Thessaly Medical School, Department of Medicine, Greece*

Marco Carbone, *University of Milano-Bicocca, Italy*

Phunchai Charatcharoenwithaya, *Mahidol University Faculty of Medicine Siriraj Hospital, Thailand*

Evangelos Cholongitas, *Medical School of National & Kapodistrian University of Athens, Greece*

Halina Cichoż-Lach, *Medical University of Lublin, Poland*

Arif Mansur Cosar, *Karadeniz Technical University Medical School, Turkey*

Stefano Francesco Crinà, *The Pancreas Institute, University of Verona, Italy*

Sayed Daoud, *Washington State University, USA*

Hailemichael Desalegn, *St. Paul's Hospital Millennium Medical College, Ethiopia*

Aisha Elsharkawy, *Cairo University, Egypt*

Ahad Eshraghian, *Avicenna Center for Medicine and Organ Transplant, Iran*

Antonio Facciorusso, *University of Foggia, Italy*

Dechun Feng, *National Institute of Health, USA*

Conrado Fernandez Rodriguez, *Hospital Universitario Fundacion Alcorcon, Spain*

Paula Ghaneh, *University of Liverpool, UK*

Lydia Giannitrapani, *University of Palermo, Italy*

Shannon Glaser, *Texas A&M Health Science Center, USA*

Amit Goel, *Sanjay Gandhi Post Graduate Institute of Medical Sciences, India*

Stephan Haas, *Karolinska University Hospital, Sweden*

Masahide Hamaguchi, *Kyoto Prefectural University of Medicine, Japan, Japan*

Joung-Ho Han, *Chungbuk National University College of Medicine & Hospital, Korea, Republic of*

Ming-Lun Han, *National Taiwan University Hospital, Taiwan*

Goran Hauser, *Clinical Hospital Centre; Medical faculty Rijeka, Croatia*

Cheng-Maw Ho, *National Taiwan University Hospital and College of Medicine, Taiwan*

Thomas Horvatits, *University Medical Centre Hamburg-Eppendorf, Germany*

Akira Imoto, *Aoyama Hospital, Japan*

Alisan Kahraman, *Max-Grundig Clinic, Germany*

Tatsuo Kanda, *Nihon University School of Medicine, Japan*

Wei-Yu Kao, *Division of Gastroenterology, Department of Medicine, Taipei Medical University Hospital, Taiwan*

David Kaplan, *Perelman School of Medicine, University of Pennsylvania, USA*

Lindsey Kennedy, *Indiana University, USA*

Tatsuya Kin, *University of Alberta, Canada*

Aydın Köksal, *Sakarya University, Department of Gastroenterology, Turkey*

Sundeep Lakhtakia, *Asian Institute of Gastroenterology, AIG Hospitals, Hyderabad, India*

Hyun Woong Lee, *Chung Ang University Hospital, South Korea*

Cosmas Rinaldi Lesmana, *Dr. Cipto Mangunkusumo National General Hospital, Indonesia*
Xiwen Liao, *The First Affiliated Hospital of Guangxi Medical University, China*
Faten Limaïem, *Centre Hospitalier Universitaire Mongi Slim, Tunisia*
Andrea Lisotti, *University of Bologna - Hospital of Imola, Italy*
Claudio Luchini, *Universita degli Studi di Verona, Italy*
Benjamin Maasoumy, *Hannover Medical School, Germany*
Paolo Magistri, *Universita degli Studi di Modena e Reggio Emilia, Italy*
Claudia Mandato, *AORN santobono-Pausilipon, Italy*
Mario Masarone, *Universita degli Studi di Salerno, Italy*
Ryota Masuzaki, *Vanderbilt University, USA*
Luca Morelli, *University of Pisa, Italy*
Shinichi Morita, *Uonuma Institute of Community Medicine Niigata University Hospital, Japan*
Sajan Nagpal, *University of Chicago, USA*
Alessia Nottegar, *Ospedale San Bortolo di Vicenza, Italy*
Takeshi Ogura, *Osaka Medical College, Japan*
Vincenzo Palmieri, *University of Bari, Italy*
Marcello Persico, *University of Salerno, Italy*
Cyriac Philips, *Ernakulam Medical Center, India*
Sven Pischke, *University Hospital Hamburg Eppendorf, Germany*
Carlo Pulitanó, *San Raffaele Scientific Institute, Italy*
Xingshun Qi, *General Hospital of Northern Theater Command, China*
Giuliano Ramadori, *University Clinic Internal Medicine, Germany*
Thomas Reiberger, *Medical University of Vienna, Austria*
Ning Ren, *Zhongshan Hospital, Fudan University, China*
Jonas Rosendahl, *University of Halle, Germany*
Philipp Schwabl, *Medical University of Vienna, Austria*
C. Roberto Simons-Linares, *Cleveland Clinic, USA*
Abhasnee Sobhonslidsuk, *Ramathibodi hospital, Thailand*
Gabriele Spoletini, *Gemelli University Hospital, Italy*
Gaya Spolverato, *University Hospital of Padova, Italy*
Maria Stepanova, *Inova Health System, USA*
Tung-Hung Su, *National Taiwan University Hospital, Taiwan*
Hirokazu Takahashi, *Liver enter, Saga University Hospital, Japan*
Akinobu Takaki, *Okayama University, Japan*
Rupjyoti Talukdar, *Asian Institute of Gastroenterology, India*
Alpaslan Tanoglu, *University of Health Sciences, Turkey, Turkey*
Sombat Treeprasertsuk, *Chulalongkorn University, Thailand*
Chih-Wei Tseng, *Dalin Tzu Chi Hospital, Buddhist Tzu Chi Medical Foundation, Taiwan*
Apostolos Tsolakis, *Karolinska Institute, Sweden*
Cristiane Villela-Nogueira, *Universidade Federal do Rio de Janeiro, Brazil*
Manlio Vinciguerra, *University College London, UK*
Alessandro Vitale, *Unità di Chirurgia Epatobiliare e Trapianto Epatico, Italy*
Yee Hui Yeo, *Stanford University School of Medicine, USA*
Alessandro Zerbi, *Humanitas University, Italy*
Dongwei Zhang, *University of Rochester Medical Center, USA*
Yanming Zhou, *The First Affiliated Hospital of Xiamen University, China*

Intestinal disorders

Makoto Arai, *Graduate School of Medicine, Chiba University, Japan*
Rupa Banerjee, *Asian Institute of Gastroenterology, India*
Massimo Bellini, *University of Pisa, Italy*
Lorenzo Bertani, *University of Pisa, Italy*
Govind Bhagat, *Columbia University, USA*
Wojciech Blonski, *University of Pennsylvania, USA*
Hsiu-Chi Cheng, *National Cheng Kung University Hospital, Taiwan*
Giuseppe Chiarioni, *University of Verona, Italy*
Silvio Danese, *Istituto Clinico Humanitas, Italy*
Parakkal Deepak, *Washington University School of Medicine, USA*
Arjuna De Silva, *Faculty of medicine Ragama University of Kelaniya, Sri Lanka*
Piotr Eder, *Poznan University of Medical Sciences, Poland*
Wael El-Matary, *University of Manitoba, Canada*
Gaetano Gallo, *University of Catanzaro, Italy*
Takuma Higurashi, *Yokohama City University, Japan*
Jörg Hoffmann, *St. Marien- und St. Annastifts Krankenhaus, Germany*
Gianluca Ianiro, *Catholic University of Rome, Italy*
Susanne Krug, *University of Berlin, Germany*
Marco Vincenzo Lenti, *University of Pavia – IRCCS Policlinico San Matteo, Italy*
Julajak Limsrivilai, *Faculty of Medicine, Siriraj Hospital, Mahidol University, Thailand*
Govind Makharia, *All India Institute of Medical Sciences, India*
Benjamin Misselwitz, *Universitat Zurich, Switzerland*
Valérie Pittet, *Center for Primary Care and Public Health, Switzerland*
Raja Affendi Raja Ali, *The National University of Malaysia, Malaysia*
Reetta Satokari, *University of Helsinki, Finland*
Annalisa Schieppatti, *University of Pavia, Italy*
Shahram Solaymani-Mohammadi, *University of North Dakota, Grand Forks, USA*
Marco Soncini, *S. Carlo Hospital, Italy*
Ajit Sood, *Dayanand Medical College & Hospital, Ludhiana, Punjab, India*
Hidetoshi Takedatsu, *Kurume University School of Medicine, Japan*
Henrik Toft Sørensen, *Aarhus University, Denmark*
Yen-Po Wang, *Taipei Veterans General Hospital, Taiwan*
Shu Chen Wei, *National Taiwan University Hospital and College of Medicine, Taiwan*
John Winston, *University of Texas, USA*
Hsu-Heng Yen, *Changhua Christian Hospital, Taiwan*
Fabiana Zingone, *University of Padua, Italy*

Nutrition and metabolism

Motahar Heidari-Beni, *Isfahan University of Medical Sciences, Iran*
Azita Hekmatdoost, *NNFTRI, Iran*
Paul Kelly, *Barts & The London School of Medicine, UK*
Richard Young, *Nerve-Gut Research Laboratory, Australia*
Maria Grazia Zizzo, *University of Palermo, Italy*

Editorial Advisors

Matías A. Avila, *Universidad de Navarra, Spain*

Giuseppe Brisinda, *University Hospital Agostino Gemelli, Italy*

Jonathan Dranoff, *University of Arkansas for Medical Sciences, USA*

Rebecca Fitzgerald, *Hutchison-MRC Research Centre, UK*

Peter Malfertheiner, *Otto-von Guericke Universitat Magdeburg, Germany*

Carmelo Scarpignato, *University of Parma, Italy*

Martin Storr, *University of Calgary, Canada*

Nurdan Tozun, *Acibadem University, Turkey*

Luca Valenti, *Universita' degli Studi di Milano, Fondazione Ca' Granda IRCCS Ospedale Maggiore Policlinico, Italy*

Field Willingham, *Emory University School of Medicine, USA*



Relationship between body composition and the histology of non-alcoholic fatty liver disease: a cross-sectional study

Causes of non-alcoholic fatty liver disease and its progression include visceral fat accumulation and loss of muscle mass; however, which of the two phenomena is more critical is unclear.

Therefore, we intend...

Authors: Teruki Miyake, Masumi Miyazaki, Osamu Yoshida, Sayaka Kanzaki, Hironobu Nakaguchi, Yoshiko Nakamura, Takao Watanabe, Yasunori Yamamoto, Yohei Koizumi, Yoshio Tokumoto, Masashi Hirooka, Shinya Furukawa, Eiji Takeshita, Teru Kumagi, Yoshio Ikeda, Masanori Abe...

Citation: *BMC Gastroenterology* 2021 21:170

Content type: Research article

Published on: 13 April 2021

- [View Full Text](#)
- [View PDF](#)

Perioperative risk factors for survival outcomes in elective colorectal cancer surgery: a retrospective cohort study

Surgical resection remains the best option for long-term survival in colorectal cancer (CRC); however, surgery can lead to tumor cell release into the circulation. Previous studies have also shown that surgery...

Authors: Xing-Xing Liu, Jun Su, Yuan-yuan Long, Miao He and Zhao-Qiong Zhu

Citation: *BMC Gastroenterology* 2021 21:169

Content type: Research

Published on: 13 April 2021

- [View Full Text](#)
- [View PDF](#)

• Clinicopathological and prognostic evaluations of anorectal cancer after fecal diversion for patients with Crohn's disease

Colorectum diversion with a proximal stoma is often the preferred surgical approach in patients with Crohn's disease-related anorectal lesions or refractory colitis. To date, few studies have assessed the inci...

Authors: Hirosuke Kuroki, Akira Sugita, Kazutaka Koganei, Kenji Tatsumi, Ryo Futatsuki, Eiichi Nakao, Nao Obara and Katsuhiko Arai

Citation: *BMC Gastroenterology* 2021 21:168

Content type: Research

Published on: 13 April 2021

- [View Full Text](#)
- [View PDF](#)

• **Characterization of novel and large fragment deletions in exon 1 of the *IL10RA* gene in Chinese children with very early onset inflammatory bowel diseases**

Defects in interleukin 10 (IL10) and its receptors are particularly involved in very early onset inflammatory bowel disease (VEOIBD). However, large fragment deletions of IL10 receptor A (*IL10RA*) are rare.

Authors: Zifei Tang, Ping Zhang, Min Ji, Chunlan Yin, Ruiqin Zhao, Zhiheng Huang and Ying Huang

Citation: *BMC Gastroenterology* 2021 21:167

Content type: Research article

Published on: 13 April 2021

- [View Full Text](#)
- [View PDF](#)

• **The microbial diversity following antibiotic treatment of *Clostridioides difficile* infection**

Clostridioides difficile (*C. difficile*) is a major nosocomial pathogen that infects the human gut and can cause diarrheal disease. A dominant risk factor is antibiotic treatment that disrupts the normal gut micro...

Authors: Dana Binyamin, Orna Nitzan, Maya Azrad, Zohar Hamo, Omry Koren and Avi Peretz

Citation: *BMC Gastroenterology* 2021 21:166

Content type: Research article

Published on: 13 April 2021

- [View Full Text](#)
- [View PDF](#)

• **Left-side incarcerated Amyand's hernia with appendix and caecum provoke by early banana diet: a case report**

Amyand's hernia was an unusual condition defined by the presence of an appendix located in the inguinal hernia sac. Its prevalence was 1% of all inguinal hernia in children. The clinical manifestation of Amyan...

Authors: Supangat, Henggar Allest Pratama, Nanda Eka Sri Sejati, Brenda Desy Romadhon and Ina Sulistyani

Citation: *BMC Gastroenterology* 2021 21:165

Content type: Case report

Published on: 13 April 2021

- [View Full Text](#)
- [View PDF](#)

• **Primary pancreatic hydatid cyst: a case report and literature review**

Hydatid cysts are parasitic zoonoses that often occur in the liver. Pancreatic hydatid cysts are very rare and are usually misdiagnosed as pancreatic cystadenomas. At present, surgical resection combined with ...

Authors: Yilei Wu, Jun Gong, Wei Xiong, Xiaojiong Yu and Xiangyu Lu

Citation: *BMC Gastroenterology* 2021 21:164

Content type: Case report

Published on: 13 April 2021

- [View Full Text](#)
- [View PDF](#)

• **Successful treatment of infantile oxysterol 7 α -hydroxylase deficiency with oral chenodeoxycholic acid**

Deficiency of oxysterol 7 α -hydroxylase, encoded by *CYP7B1*, is associated with fatal infantile progressive intrahepatic cholestasis and hereditary spastic paraplegia type 5. Most reported patients with *CYP7B1* muta...

Authors: Yun-Ping Tang, Jing-Yu Gong, Kenneth D. R. Setchell, Wujuan Zhang, Jing Zhao and Jian-She Wang

Citation: *BMC Gastroenterology* 2021 21:163

Content type: Case report

Published on: 13 April 2021

- [View Full Text](#)
- [View PDF](#)

• **A case of intraductal tubulopapillary neoplasm of the pancreas in a branch duct: a rare case report and literature review**

Intraductal tubulopapillary neoplasm (ITPN) of the pancreas is a new disease concept defined by the World Health Organization in 2010. ITPN progresses with tubulopapillary growth in the pancreatic duct and is ...

Authors: Atsushi Yamaguchi, Takuro Hamada, Kaoru Wada, Riho Moriuchi, Kanae Tao, Hirona Konishi, Yuzuru Tamaru, Ryusaku Kusunoki, Toshio Kuwai, Hirotaka Kouno, Kohei Ishiyama, Naoto Hadano, Takeshi Sudo, Naoyuki Toyota, Junichi Zaitso, Kazuya Kuraoka...

Citation: *BMC Gastroenterology* 2021 21:162

Content type: Case report

Published on: 13 April 2021

- [View Full Text](#)
- [View PDF](#)

CASE REPORT

Open Access



Amyand's hernia associated with mesenteric chylous cyst in infant: a rare case report

Supangat^{1,4*} , Muhammad Yuda Nugraha² and Meiske Margaretha³

Abstract

Background: Amyand's hernia is a rare condition approximately 0.4–0.6% of all inguinal hernias. Although rare, the Amyand's hernia is worthy of discussion since the variable presentation that make clinical challenge to diagnose especially in infant. A mesenteric chylous cyst is rare disease and has not been reported in Amyand's hernia.

Case presentation: We report an unusual case of Type II Amyand's hernia with an enlarging chylous mesenteric cyst on the retrocaecal in the anulus into canalis inguinalis. A-2-months old infant presented with enlarging mass in the right scrotal. During laparotomy exploration, we found inguinal sac with intestinal and appendix content in the sac. In the edge site of the sac we found enlarging of mesenteric cyst on the retrocaecal in the anulus into canalis inguinalis. Based on the histopathology examination, the morphological feature is suitable for mesenteric chylous cyst appearance.

Conclusion: Presentation of mesenteric chylous cyst is rare, and there was no report about it in Amyand's hernia. This unusual presentation should be considered by the surgeon, especially pediatric surgeon, in Amyand's hernia cases.

Keywords: Hernia, Mesenteric cyst, Pediatric, Surgery

Background

Amyand's hernia is a rare condition approximately 0.4–0.6% of all inguinal hernias where the vermiform of appendix is found in inguinal hernia sac [1]. An incarcerated or strangulated hernia is commonly presenting in Amyand's hernia, but it is classified as several types for variable presentation. We report an unusual case of Type II Amyand's hernia with an enlarging chylous mesenteric cyst on the retrocaecal in the anulus into canalis inguinalis.

Case presentation

A-2-months old infant presented with enlarging mass in the right scrotal. On physical examination, the enlarging mass was found with diameter 10 cm non-fluctuant,

non-erythematous which was fixed and mildly tender to palpation (Fig. 1). Based on hetero anamnesis, the patient vomited with green fluid before presenting into emergency department. The vital sign was steady in normal limit. During abdominal examination, there was decreasing of bowel sounds but there was no abdominal distention sign.

In the emergency department the patient underwent to take plain abdominal radiography. There was intestinal like appearance in the scrotal region and some dilated intestinal but no evidence of intestinal obstruction or aeration in the scrotal compartments (Fig. 2). The advance radiological examination cannot be performed since the patient's condition. All laboratory values were within normal limits. Based on the clinical examination and radiography the patient was diagnosed with Right Scrotum Hernia. After first initial treatment in the emergency department with normal fluid resuscitation, then patient was planned into laparotomy approach to treat the hernia.

*Correspondence: drsupangat@unej.ac.id

⁴ Faculty of Medicine, Universitas Jember, Jl Kalimantan No 37, Krajan Timur, Sumber sari Kec Sumber sari, Jember 68121, East Java, Indonesia
Full list of author information is available at the end of the article



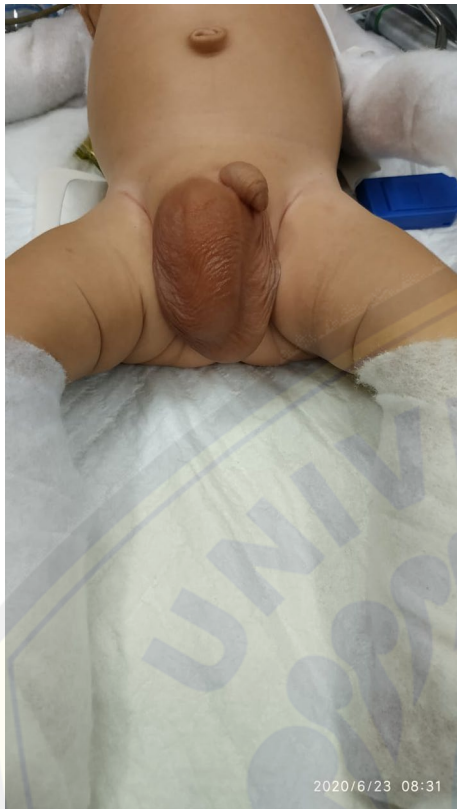

Fig. 1 Enlarging mass in the right scrotal

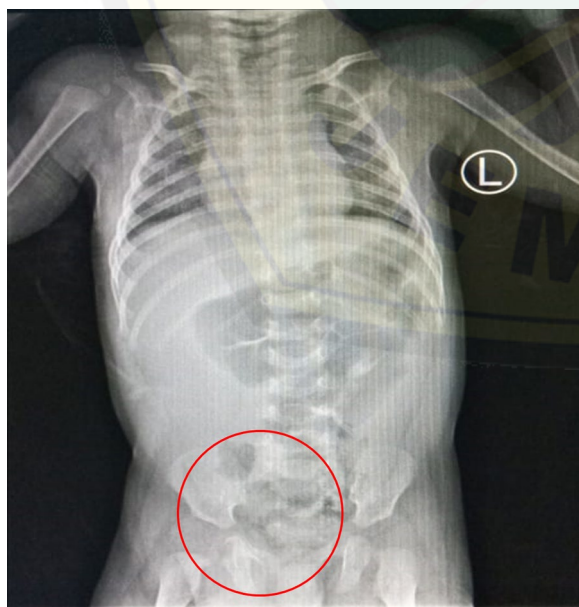

Fig. 2 Plain abdominal radiography

During laparotomy exploration, we found inguinal sac with intestinal and appendix content in the sac (Fig. 3a). The inflamed appendix but there was no perforation sign that indicate the type II of Amyand's Hernia as intraoperative diagnosis. In the edge site of the sac we found hyperemia mesenteric cyst on the retrocaecal in the canalis inguinalis (Fig. 3b). Appendectomy, cyst resection and hernia closure were done. Then the cyst resection was presented to histopathology examination.

Based on the histopathology examination, the cyst resection is form of a swollen connective tissue (red arrow in Fig. 4a) that coated with spindle-shaped cells resembling endothelial cells on the surface (blue arrow in Fig. 4a). Lymphoplasmatic inflammatory cells appeared in the stroma then also moderate neutrophil PMN type (orange arrow in Fig. 4a) and dilated blood vessels (yellow arrow in Fig. 4a). There was also benign smooth muscle tissue and the large area of bleeding (Fig. 4b). There are no malignant signs on this resection. This morphological feature is suitable for Chylous cyst appearance.

Discussion and conclusion

In 1735 at the St. hospital George in London, dr. Claudius Amyand succeeded in carrying out the first appendicitis surgery in the world. The patient is an 11-year-old boy with a diagnosis of inguinal hernia combined with acute appendicitis. During the operation, dr. Amyand finds the appendix in the hernia sac [2]. This rare pathology is then given the name "Amyand Hernia" according to the name of the surgeon who first described it and treated it. The incidence of an Amyand's Hernia is less than 1% of inguinal hernias with the most patients is male. In this case, the patient is infant and male. It is really challenging to diagnose Amyand's hernia in infant.

Amyand 's Hernia commonly located on the right side due to the location of the appendix. Approximately 0.1% of Amyand's Hernia cases, appendix could be inflamed [3]. Therefore, Losanoff et al. classified Amyand's hernias into four type. The type I is defined when there is no described appendix inflammation; type II describes acute appendicitis within the hernia sac; type III acute appendicitis complicated with peritonitis; and type IV acute appendicitis is accompanied by other diseases [4]. In this case, we found an acute appendicitis during intraoperative but there was no sign of peritonitis. Then, the type of Amyand's Hernia in this case is classified as type II Amyand's Hernia.

Amyand's Hernia commonly performs as incarcerated inguinal hernias that make it very difficult to diagnose only by clinical assesment especially in infant. Preoperative diagnosis of Amyand's Hernia can be established using investigations in the form of ultrasound or CT scan. Mostly cases of Amyand's Hernia are diagnosed

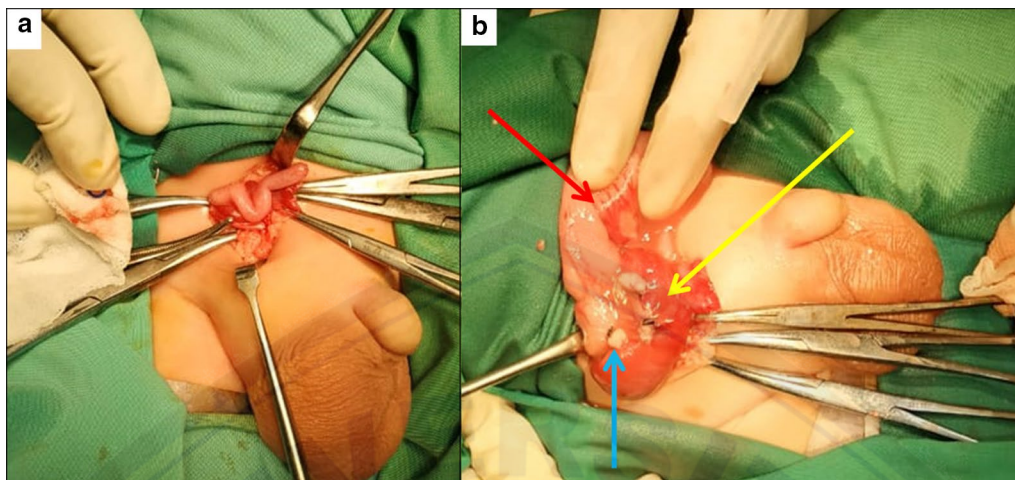


Fig. 3 a Appendix and intestinal in the inguinal sac, b Hyperemia mesenteric cyst (yellow arrow), post appendectomy (blue arrow) and caecum (red arrow) in the inguinal sac

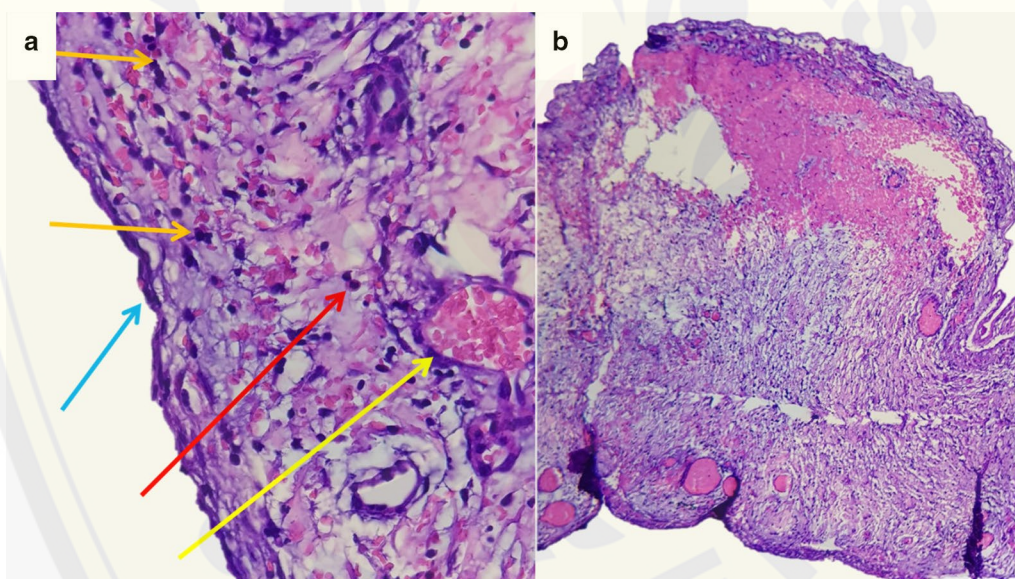


Fig. 4 Histopathology examination of cyst resection

intraoperatively during the operation process [5]. In this case, we diagnosed Amyand's Hernia intraoperatively. During preoperative diagnosis, we only performed scrotal hernia as a diagnosis based on clinically and plain abdominal radiography since abdominal ultrasound or CT Scan cannot be performed.

In Amyand's Hernia, the appendix can be found together with the right cecum or colon in the hernia sac. In some cases it can also be found a bladder, ovary, fallopian tube, omentum or meckel diverticulum in the hernia sac [6]. In this case we found mesenteric cyst in the

hernia sac. After histopathology examination, the type of cyst is classified as mesenteric chylous cyst. The presenting of mesenteric chylous cyst in Amyand's hernia has not been reported before.

Mesenteric cysts is a rare pathologic entity that identified in approximately 1 out of 100,000 adult and 1 in 20,000 paediatric in hospital admissions [7]. A mesenteric chylous cyst is the type of mesentery cyst which may extend from the base of the mesentery into the retroperitoneum [8]. A mesenteric chylous cyst could be totally asymptomatic or present with unspecific abdominal

symptoms. It is a rare disease, but surgeons must consider the diagnosis in the presence of a cystic abdominal tumor [9].

Amyand's hernia has variability in presentation that makes it difficult to diagnose clinically in infant and mostly identified intraoperatively. Presentation of mesenteric chylous cyst is rare, and there was no report about it in Amyand's hernia. This unusual presentation should be considered by the surgeon, especially pediatric surgeon, in Amyand's hernia cases.

Abbreviations

CT scan: Computed tomography scan; PMN: Polymorphonuclear.

Acknowledgements

Not applicable

Authors' contributions

MYN drafted the manuscript. S and MM provided expert opinion and edited the manuscript and article guarantor. All authors have read and approved the manuscript and ensure that this is the case.

Funding

No funding was applied for this study.

Availability of data and materials

Not applicable.

Ethics approval and consent to participate

The study involving a human participant to report was approved by the ethics committee of Faculty of Medicine, Jember University. Written consent was obtained from the patient's parents.

Consent for publication

Written informed consent was obtained from the patient guardian for publication of this case report and accompanying images since the patient is under 16 years old. A copy of the written consent is available for review by the Editor of this journal.

Competing interests

The authors declare no conflict of interest.

Author details

¹ Division of Pediatric Surgery, dr. Soebandi Regional Hospital-Faculty of Medicine, Jember University, Jember, East Java, Indonesia. ² Faculty of Medicine, Jember University, Jember, East Java, Indonesia. ³ Division of Pathological Anatomy, dr. Soebandi Regional Hospital, Jember, East Java, Indonesia.

⁴ Faculty of Medicine, Universitas Jember, Jl Kalimantan No 37, Krajan Timur, Sumber sari Kec Sumber sari, Jember 68121, East Java, Indonesia.

Received: 14 July 2020 Accepted: 4 November 2020

Published online: 02 December 2020

References

1. Burgess PL, Brockmeyer JR, Johnson EK. Amyand hernia repaired with Bio-A: a case report and review. *J Sur Educ*. 2011;68:62–6.
2. Amyand C. Of an inguinal rupture, with a pin in the appendix caeci, incrusted with stone; and some observations on wounds in the guts. *Philos Trans R Soc Lond*. 1736;39:329–36.
3. Ballas K, Kontoulis T, Skouras C, Triantafyllou A, Symeonidis N, Pavlidis T, et al. Unusual findings in inguinal hernia surgery: report of 6 rare cases. *Hippokratia*. 2009;13:169–71.
4. Losanoff JE, Basson MD. Amyand hernia: what lies beneath—a proposed classification scheme to determine management. *Am Surg*. 2007;73:1288–90.
5. Michalinos A, Moris D, Vernadakis S. Amyand's hernia: a review. *Am J Surg*. 2014;207(6):989–95.
6. Goyal S, Shrivastva M, Verma RK, Goyal S. "Uncommon contents of inguinal hernial sac": a surgical dilemma. *Indian J Surg*. 2015;77(Suppl 2):305–9.
7. Tebala GD, Camperchioli I, Tognoni V, Noia M, Gaspari AL. Laparoscopic treatment of a huge mesenteric chylous cyst. *JSLs*. 2010;14:436–8.
8. Lee DLP, Madhuvrata P, Reed MW, Balasubramanian SP. Chylous mesenteric cyst: a diagnostic dilemma. *Asian J Surg*. 2016;39:182–6.
9. Dioscoridi L, Perri G, Freschi G. Chylous mesenteric cysts: a rare surgical challenge. *J Surg Case Rep*. 2014;2014(3):rju012.

Publisher's Note

Springer Nature remains neutral with regard to jurisdictional claims in published maps and institutional affiliations.

Ready to submit your research? Choose BMC and benefit from:

- fast, convenient online submission
- thorough peer review by experienced researchers in your field
- rapid publication on acceptance
- support for research data, including large and complex data types
- gold Open Access which fosters wider collaboration and increased citations
- maximum visibility for your research: over 100M website views per year

At BMC, research is always in progress.

Learn more biomedcentral.com/submissions

