

KARYA ILMIAH:
SEMINAR NASIONAL

Management of Congenital Diaphragmatic Hernia in a Limited Facility:

A Case Report

dr. Supangat M.Kes., Ph.D Sp.BA

NIP. 197304241999031002

- Tenaga Pengajar Bagian Paraklinik
Fakultas Kedokteran Universitas Jember



**KEMENTERIAN RISET, TEKNOLOGI, DAN
PENDIDIKAN TINGGI
UNIVERSITAS JEMBER**

Karya Ilmiah Dipresentasikan Pada Seminar Nasional:

Pertemuan Ilmiah Tahunan (PIT) ke XXVII PERBANI

01-04 Oktober 2019, Malang

Thank you for submitting the abstract to the 27th Annual Scientific Meeting of PERBANI (PIT PERBANI 2019), upcoming Oct 1-4th, in Malang East Java.

We are pleased to inform you that the following abstract which you submitted has been selected for an **short oral presentation**.

Abstract submission number : 037

Abstract title :

Managemnt of Congenital Diaphragmatic Hernia in A Limited Facility: A Case Report

Note:

(1) Accepted first authors must complete registration by September 9th (Mon), 2019.

If the first author has not registered by then, the abstract will be excluded and won't be published in the program book.

(2) The timing and location of the presentation will be sent out as we finalize program, by Sept 20th (Fri), 2019 at the latest.

(3) The detailed session information including presentation style (oral/eposter) is still under consideration at this moment, and will be informed later.

Best regards,

Widanto, M.D

Chairman, PIT Perbani 2019

Pediatric Surgery Division

dr. Saiful Anwar Hospital

Jl. Jaksa Agung Suprpto No. 2 Malang

0341-356111

perbanimalang@gmail.com

081334563233



MANAGEMENT OF CONGENITAL DIAPHRAGMATIC HERNIA IN A LIMITED FACILITY: A CASE REPORT

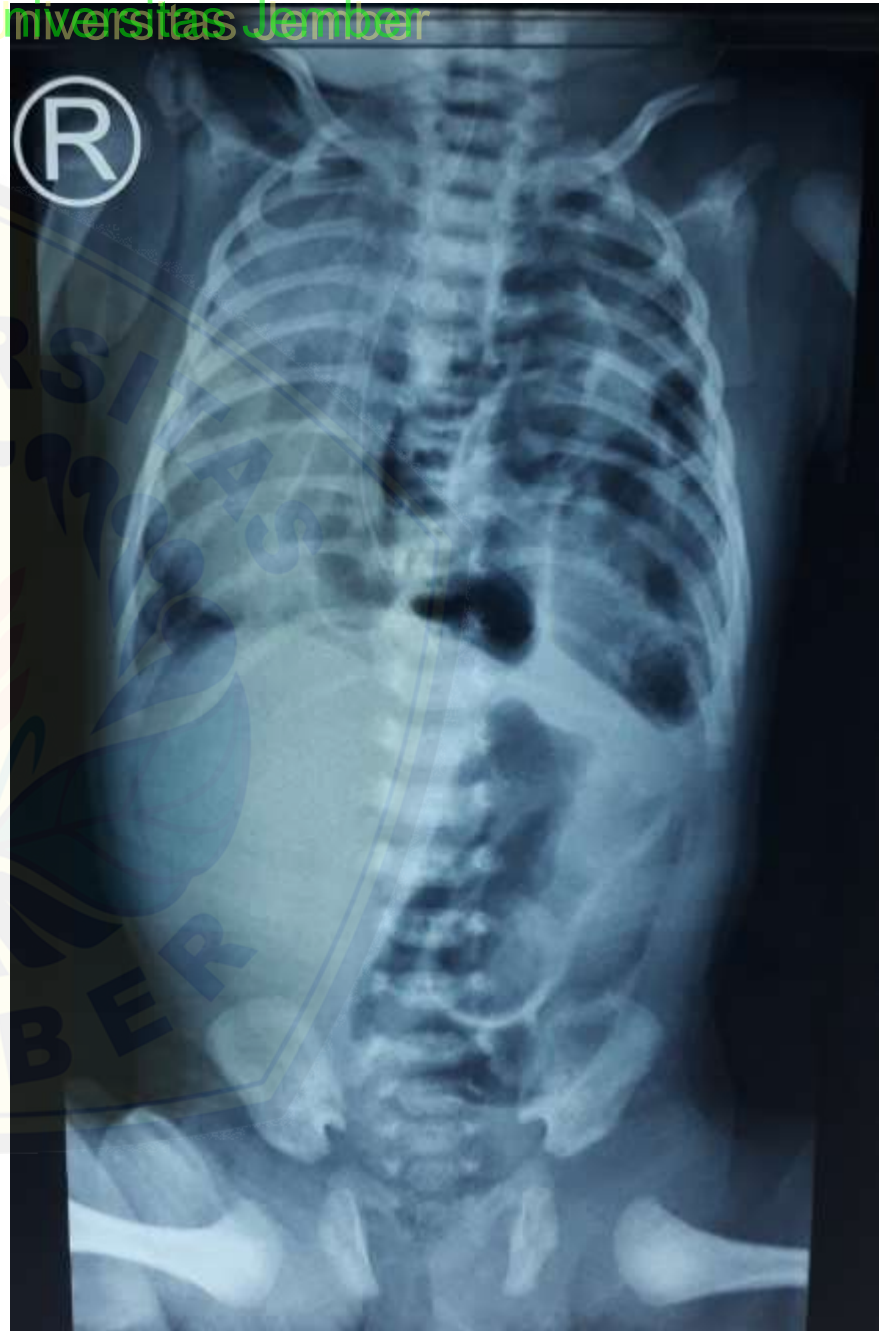Supangat, Pediatric Surgeon
Gilang Vigorous, General Practitioner

dr. Soebandi General Hospital
Faculty of Medicine University of Jember
East Java, Indonesia

1st Day of Admission

- 15 days-old baby, male, C-section due to total placenta previa and breech position, BW : 2700g
- Chief complaint : dyspneu and cyanotic appearance
- No history of cough, fever

- Cyanotic appearance
- Tachypneu (68bpm)
- intercostal retractions
- Use of accessory respiratory muscles
- 85% O₂ sat (mask-reservoir)

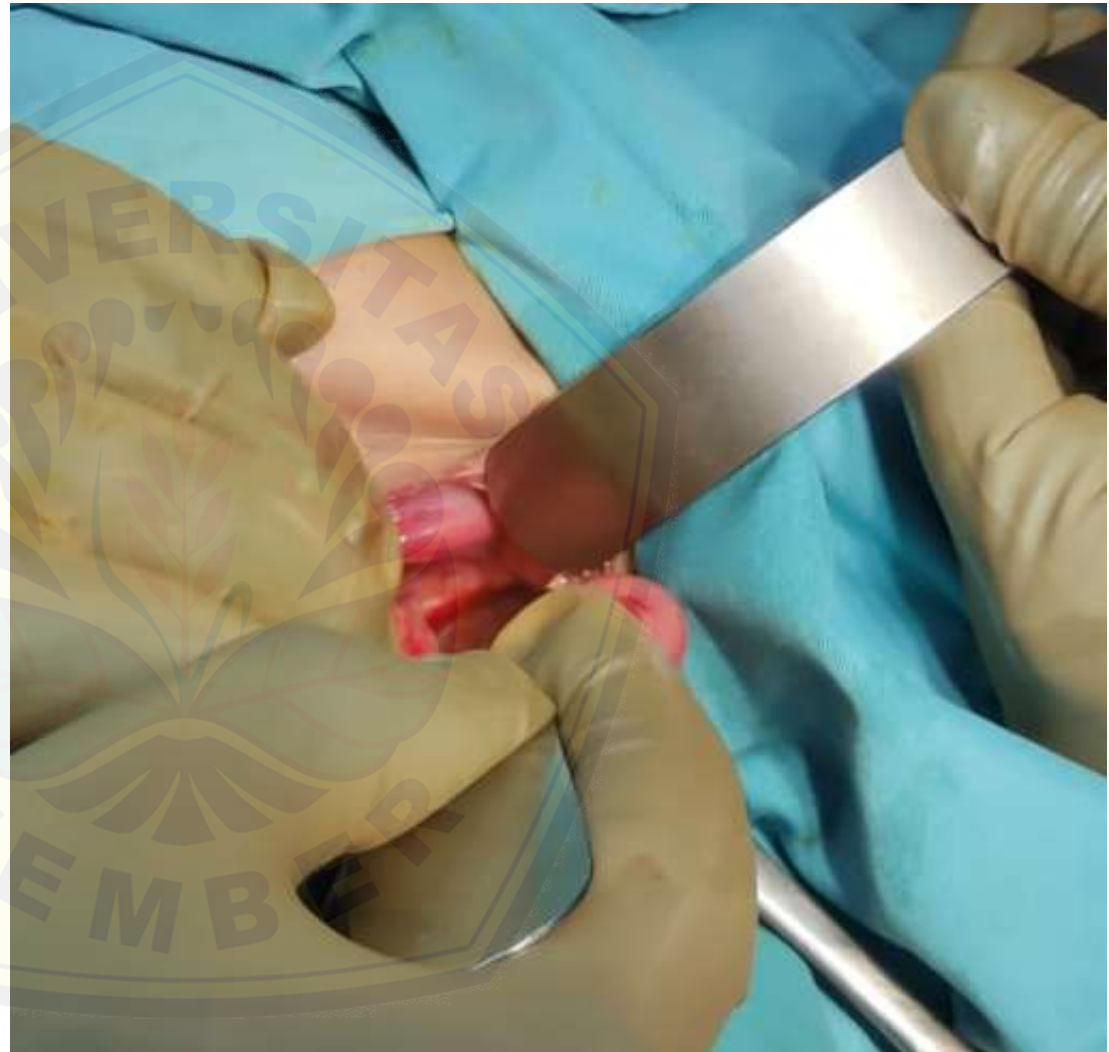


5th day of admission (20th day of life)

- Abdominal approach
- Posterior-lateral defect

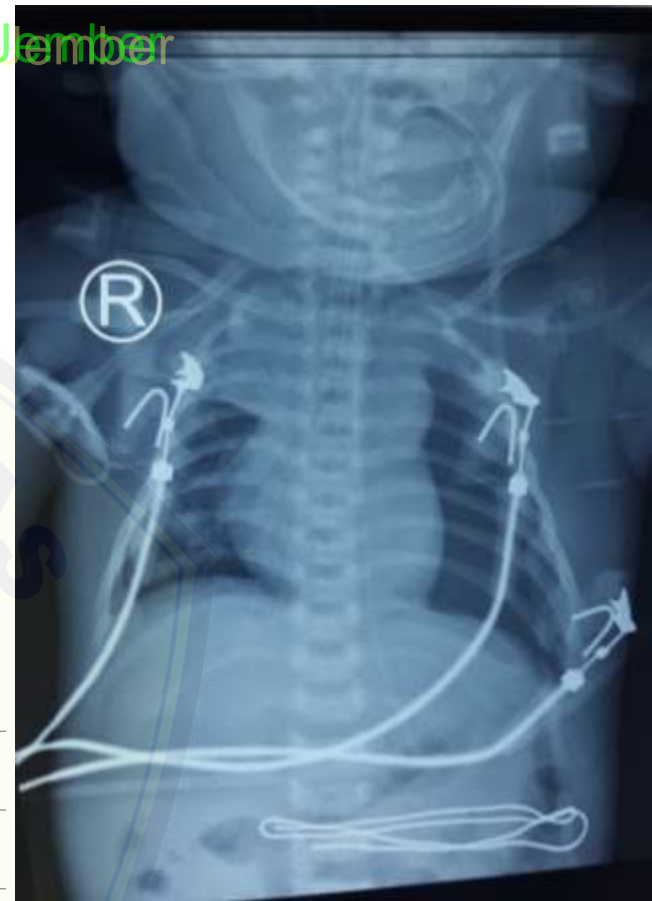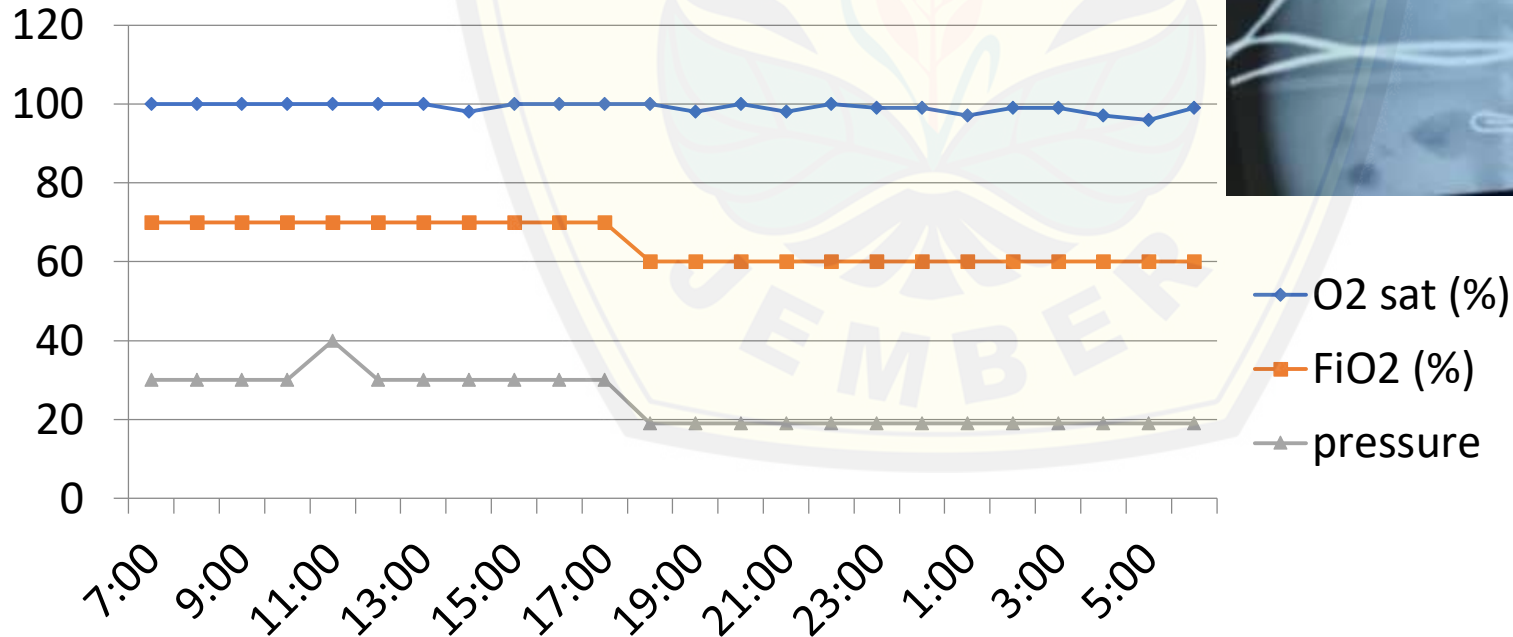
Postoperative :

- Fluids
- Antibiotics
- Ventilation

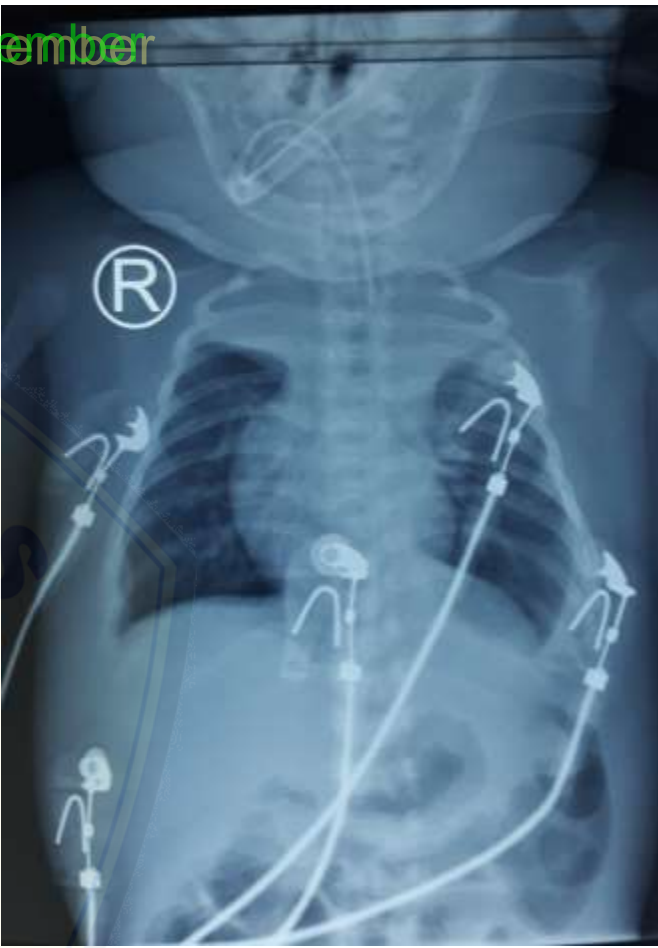

(24th DOL, 4th day post-laparotomy)

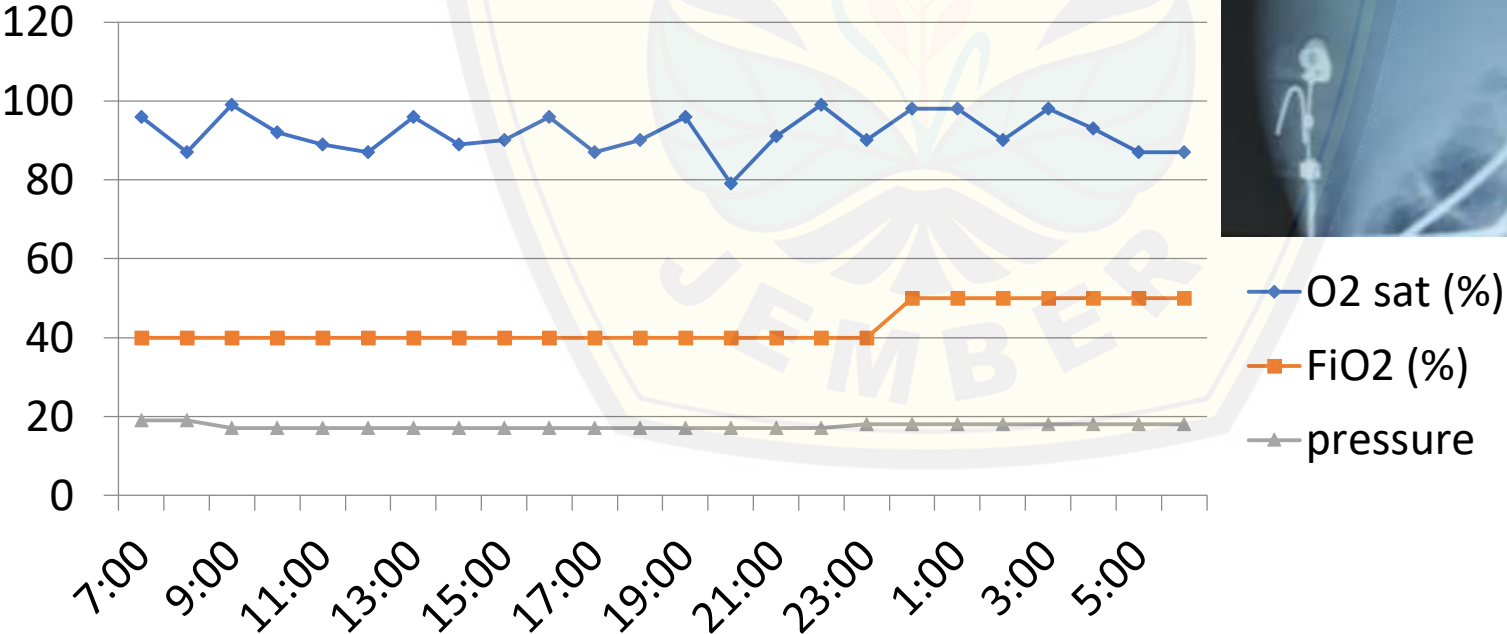
BGA		
Suhu	36.0	37
FiO2	0.51	0.21
Ca	1.25	1.15 - 1.35
pH	7.12	7.35 - 7.45
pCO2	103	35 - 48
PO2	175	80 - 100
BE	2.8	-2 - 3.0
tCO2	37.6	
HCO3	34.3	18.0 - 23.0
tHb	9.6	11.7 - 17.4
SO2	96	95 - 98
AaDO2	- 300	
Na	119	135 - 145
K	6.9	3.5 - 5.0



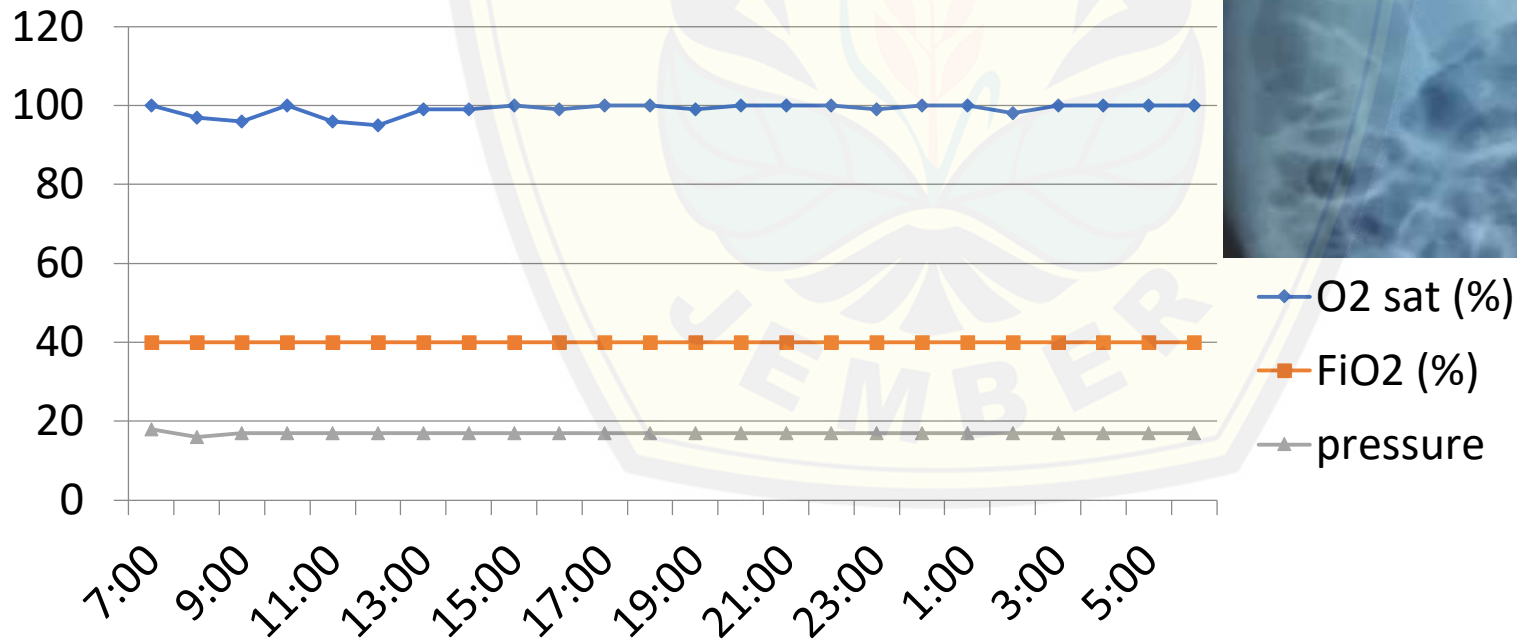
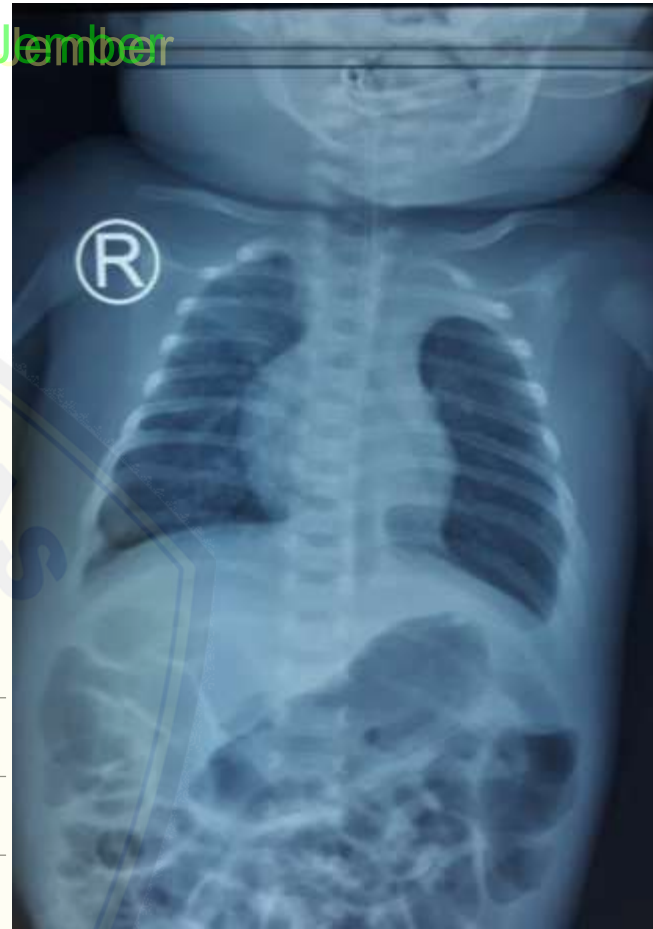
12th day of admission (27th DOL, 7th day post-laparotomy)



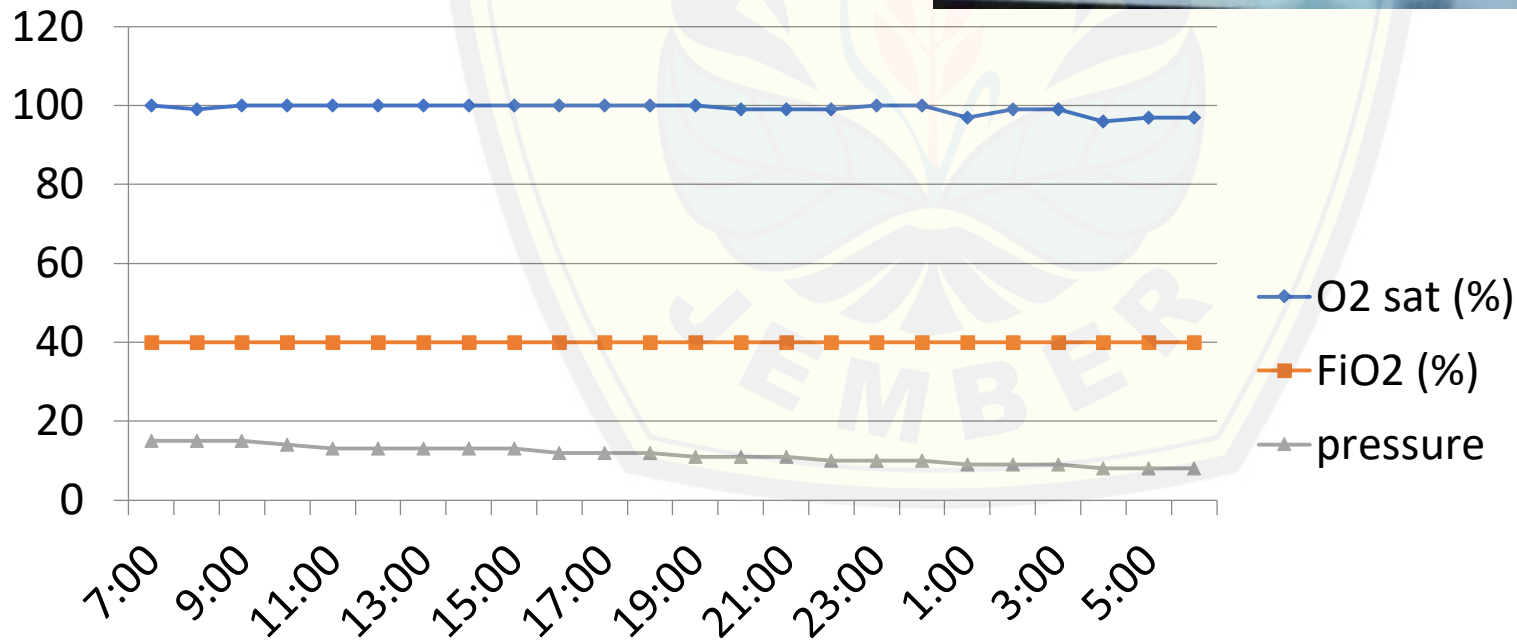
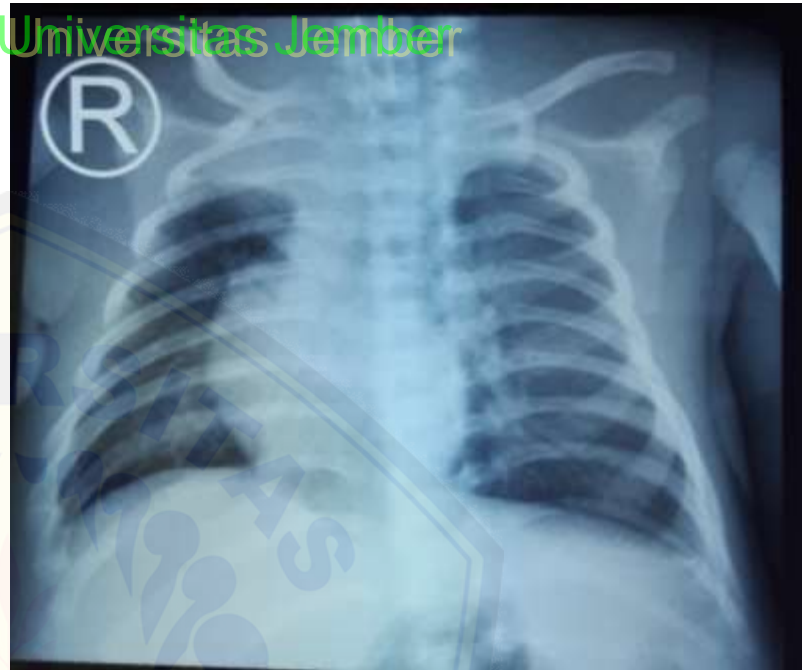
BGA		
Suhu	36.0	37
FiO2	0.40	0.21
Ca	0.97	1.15 - 1.35
pH	7.14	7.35 - 7.45
pCO2	107	35 - 48
PO2	60	80 - 100
BE	5.2	-2 - 3.0
tCO2	40.7	
HCO3	37.3	18.0 - 23.0
tHb	11.2	11.7 - 17.4
SO2	84	95 - 98
AaDO2	91	
Na	121	135 - 145
K	2.6	3.5 - 5.0



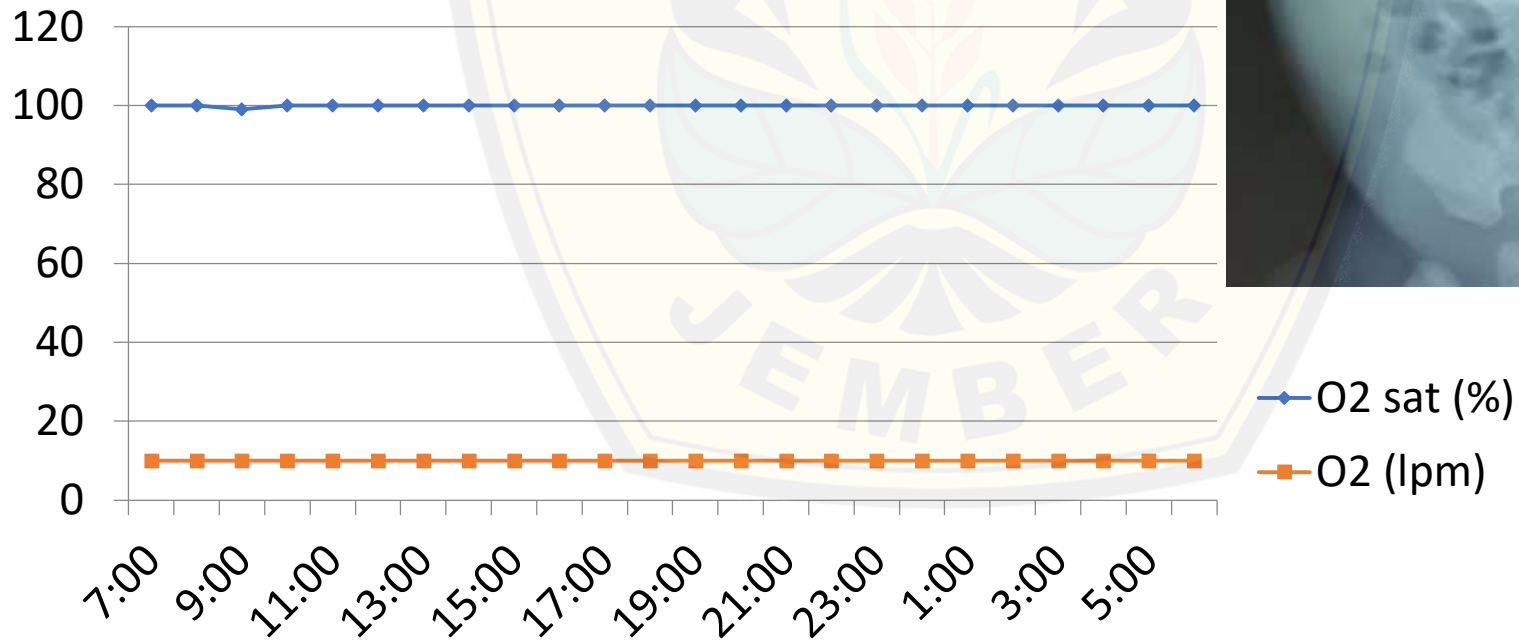
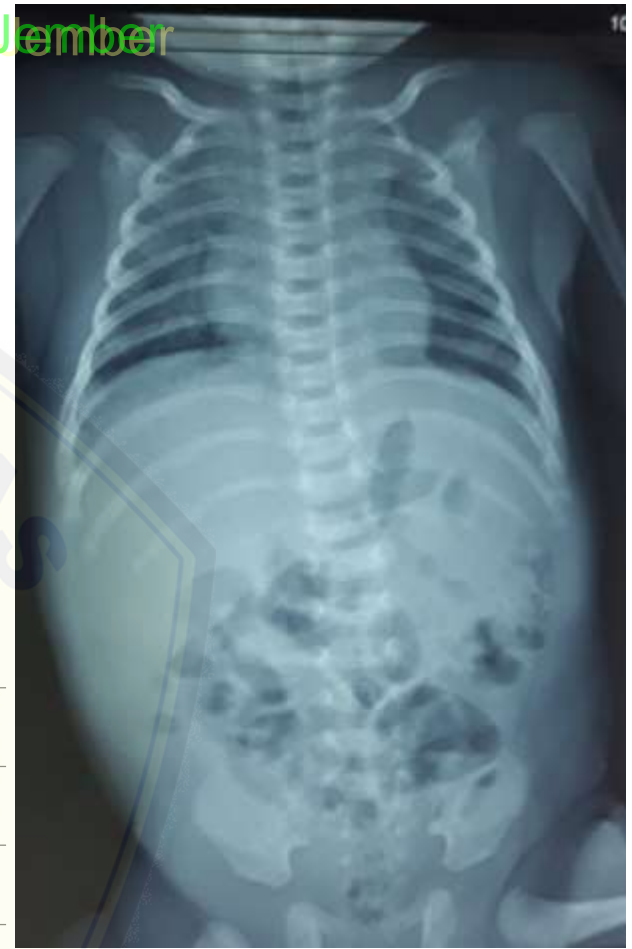16th day of admission (31st day of life, 11th day post-laparotomy)



**20th day of admission
(35th day of life, 15th
day post-laparotomy)**



**25th day of admission
(40th day of life, 20th
day post-laparotomy)**





Thank You



Certificate

This is to certify that

dr. Supangat ,M. Kes,PhD,SpBA

has participated in

27th Annual Scientific Meeting of
Indonesian Association of Pediatric Surgeons

“Comprehensive Management In Pediatric Surgery For A Better Outcome”

HARRIS Hotel & Conventions and Saiful Anwar General Hospital
Malang, October 1-4, 2019

as

SPEAKER

SKP IDI : 12

SK PB IDI NO. : 0790/PB/A.4/09/2019

PRESIDENT OF
INDONESIAN ASSOCIATION OF
PEDIATRIC SURGEONS

Yusirwan Yusuf, MD

HEAD OF
ORGANIZING COMMITTEE

Widanto, MD