

## The effects of topical application of red pomegranate (*Punica granatum Linn*) extract gel on the healing process of traumatic ulcers in Wistar rats

Sri Hernawati,<sup>1</sup> Yonanda Az Zikra,<sup>1</sup> and Dwi Warna Aju Fatmawati<sup>2</sup>

<sup>1</sup>Department of Oral Medicine

<sup>2</sup>Department Conservative Dentistry

Faculty of Dentistry, Universitas Jember  
Jember – Indonesia

### ABSTRACT

**Background:** Trauma-induced ulcers constitute one of the painful abnormalities affecting the oral cavity about which numerous individuals complain. The prevalence of traumatic ulcers (15-30% of cases) is relatively high compared to other oral lesions. Unfortunately, the use of anti-inflammatory drugs classified as steroids can lead to contraindications and serious side effects. Hence, the use of natural ingredients represents an alternative treatment. One such ingredient is red pomegranate containing bioactive elements acting as anti-inflammatory, antibacterial, antimicrobial, and antioxidant agents which accelerate the healing process in traumatic ulcers. **Purpose:** The aim of this study was to determine the effects of the topical application of red pomegranate (*Punica granatum Linn*) extract on the healing process in traumatic ulcers in Wistar rats. **Methods:** 24 male rats, aged 2-3 months, were divided into six groups, namely; two control groups (PC: triamcinolone acetonide and NC: sterile aquades) and four treatment groups (red pomegranate extract gel at respective concentrations of 12.5%, 25%, 50% and 75%). A traumatic ulcer was subsequently created using a flame-shaped burnisher tip 2mm in diameter and heated for  $\pm 15$  seconds. The diameter traumatic ulcer of each research subject was measured and observed until it healed within the remedial parameters determined by means of a UNC-15 periodontal probe which had been placed on it. The data obtained was analyzed using Kruskal-Wallis and Mann-Whitney tests. **Results:** Topically applied red pomegranate extract gel can reduce the width of the ulcerated area, while also accelerating traumatic ulcer healing. There was a significant difference in the healing time between the group using red pomegranate extract gel at a concentration of 75% and the positive control group using 0.1% triamcinolone acetonide with  $p=0.44$  ( $p<0.05$ ). **Conclusion:** Red pomegranate extract gel possesses the ability to accelerate the healing process in traumatic ulcers. The most effective concentration of red pomegranate extract gel at accelerating the healing process in traumatic ulcers is 75%.

**Keywords:** anti-inflammatory; antioxidant; red pomegranate; traumatic ulcer

**Correspondence:** Sri Hernawati, Department of Oral Medicine, Faculty of Dentistry, Universitas Jember, Jl. Kalimantan 37, Jember 68121, Indonesia. E-mail: srihernawati.drg5@yahoo.com

### INTRODUCTION

An ulcer constitutes a pathological condition characterized by loss of the epithelium layer due to surface excavation having penetrated deeper than the epithelial tissue. Traumatic ulcers are caused by thermal, mechanical, chemical and electrical trauma<sup>1</sup> and usually found on non-keratinous surfaces such as buccal/labial mucosa, tongue, lips and hard or soft palate.<sup>2</sup>

Traumatic ulcers in the oral cavity require between 7 and 14 days to heal.<sup>3</sup> In general, their treatment involves eliminating local causes through the topical administration of drugs such as corticosteroids to reduce inflammation and the use of antiseptic mouthwash containing 0.2% chlorhexidine gluconate or benzydamine hydrochloride.<sup>1</sup> The administration of topical corticosteroids in the form of ointments, gels, or elixirs has traditionally been considered the most effective treatment in the management

of pain and to accelerate the recovery time of oral ulcers.<sup>1</sup> One topical corticosteroid for the treatment of oral mucosal inflammation is 0.1% triamcinolone acetonide which according to Skidmore-Roth,<sup>4</sup> demonstrates contraindications with regard to the treatment of fungal, viral or bacterial infections of the mouth and throat. In other words, the use of corticosteroids during active infections can suppress the body's immune system.<sup>4</sup> One side effect of topical corticosteroids on the oral mucosa is to promote the growth of *Candida* spp. in the oral cavity potentially resulting in candidiasis. Moreover, 0.1% triamcinolone acetonide produces other side effects such as a burning sensation, itching, irritation, dryness, peeling, perioral dermatitis, allergies and maceration, secondary infection and atrophy of the oral mucosa.<sup>5</sup>

Due to these contraindications and the serious side effects of steroidal anti-inflammatory drugs, numerous treatments have recently begun to utilize natural ingredients including supplements and herbal medicines as pain and inflammation relievers. The use of natural ingredients as medicines rarely causes negative side effects compared to drugs manufactured from synthetic materials.<sup>6</sup> One such natural ingredient is red pomegranate (*Punica granatum Linn*) containing bioactive ingredients which act as anti-inflammatory, antibacterial, antimicrobial and antioxidant agents.<sup>7</sup>

Pomegranate also contains polyphenol compounds that function as antioxidants in preventing several diseases. The antioxidant and anti-inflammatory properties of pomegranate are assumed to be caused by its high polyphenol content, such as ellagic acid (EA) in free or bound forms, gallotannins and anthocyanins, and other flavonoids. Pomegranate extract is also assumed to be more effective than the administration of only one active ingredient since it constitutes a combination of several active substances that form a synergistic, mutually formulating formula.<sup>7</sup>

Pomegranate has, in fact, been used as a medicinal plant since the time of ancient Egypt.<sup>7</sup> Various studies of red pomegranate extract at concentrations of 12.5%, 25%, 50% and 75% have been carried out in vitro,<sup>8</sup> although further studies need to be conducted in vivo. Consequently, this study aims to determine the potential for pomegranate extract to cure traumatic ulcers.

## MATERIALS AND METHODS

The study constituted experimental laboratory research using pretest and posttest control group design and was conducted at the Experimental Animal Laboratory, Faculty of Dentistry, Universitas Jember and the Laboratory of Liquid and Semisolid Technology, Pharmaceutical Division, Faculty of Pharmacy, Universitas Jember. This research involving the use of animal subjects received ethical approval from the Faculty of Dentistry, Universitas Jember (No.133/UN25.8/KEPK/DL/2018).

Before the procedure for making traumatic ulcers was performed, ketamine hydrochloride was injected into the thigh muscles of the subjects. A 15-40 mg/kg dose of general anesthesia was administered prior to a traumatic ulcer being created using a 2 mm diameter flame-shaped burnisher tip that had been heated in a bunsen burner flame for  $\pm 15$  seconds before being applied to the lower lip mucosa of the subjects for one second. The depth of the application was that of the tip diameter of the burnisher that had been indicated with a marker. Observation of the traumatic ulcers formed was subsequently conducted on days 1, 3, 5 and 7 until they had healed.<sup>9,10</sup> The ulcers were then measured by placing a straight periodontal probe (UNC-15) in the vertical and horizontal sides as well as one of the diagonal sides.<sup>10</sup> The ulcer healing parameters consisted of the following: the absence of a yellowish/grayish ulcer, the similarity between the color of the ulcerated mucosa and that of normal mucous, being flush with the oral mucosal surface and complete healing of the lesion.

The 24 rats with traumatic ulcers were divided into six groups, namely; four treatment groups each of which had been administered with pomegranate extract at respective concentrations of 12.5%, 25%, 50% and 75%, a positive control (PC) and a negative control (NC). Each group contained four subjects which were isolated before the application by means of cotton buds of the designated material, namely; red pomegranate extract gel at varying concentrations for the treatment groups, the application of 0.1% triamcinolone acetonide for the positive control group and the administration of distilled water for the negative control group. Each ingredient was topically applied by means of a micro brush twice a day (at intervals of no more than 12 hours).<sup>10</sup>

The data resulting from the observation focused on the recovery time within the traumatic ulcer healing process based on the percentage of the total number of traumatic ulcers healed and their surface areas. Traumatic area was calculated by measuring the diameter of the ulcer from the day of its formation to the day that it was healed using a periodontal probe UNC-15. For the purposes of this study, the ulcer healing parameters consisted of the following: absence of a yellowish/grayish ulcer, the similarity between the color of the ulcerated mucosa with that of normal mucous, being flush with the oral mucosal surface and complete healing of the lesion.<sup>2</sup> The data produced focused on the number of days required for the healing of traumatic ulcers in each group after analysis by means of a Saphiro Wilk normality test and a homogeneity test. This data was subsequently analyzed using a non-parametric Kruskal-Wallis test and a Mann-Whitney test.

## RESULTS

The results indicated that the 10-day application of red pomegranate gel extract at concentrations of 12.5%, 25%, 50% and 75%, 0.1% triamcinolone acetonide, together

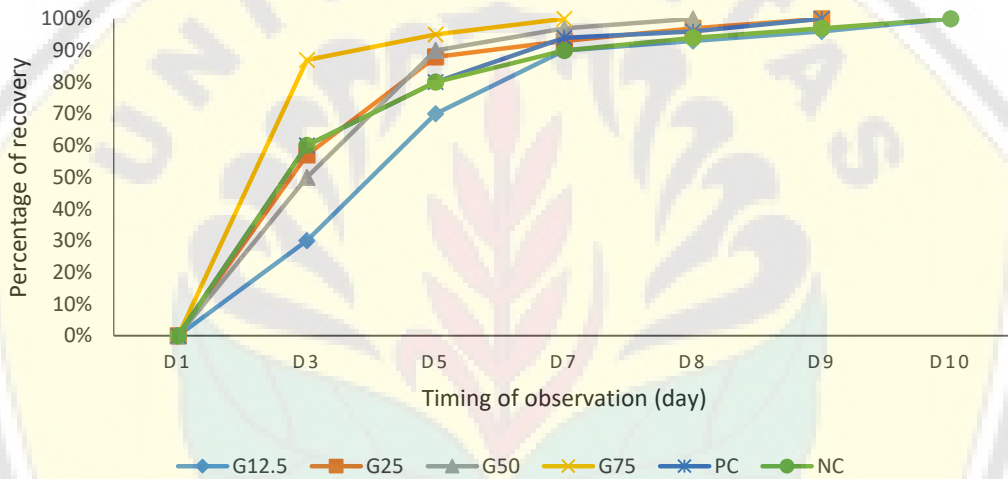
with distilled water decreased the dimensions of the ulcers.

According to the calculation results, the mean width of the ulcer area in each group decreased (Table 1), while the percentage of ulcer recovery increased across all groups. The highest percentage was recorded by the group which had been administered with red pomegranate extract gel at a concentration of 75% (Figure 1). Moreover, the Kruskal-Wallis nonparametric test results indicated differences in recovery time between the 12.5% group, the 25% group, the 50% group, the 75% Group, the PC Group and the NC Group ( $p < 0.05$ ).

There was also a significant difference in recovery time between the group which had been administered with 75% pomegranate extract gel and the positive control group with 0.1% triamcinolone acetonide ( $p < 0.05$ ) (Table 2).

**DISCUSSION**

The study results revealed that the topical application of red pomegranate gel extract affected the healing process in the traumatic ulcers of the Wistar rat subjects. Although the recovery time varied between groups, the healing process stages did not. These comprised the yellowish white surface and the emergence of a peripheral erythema zone, the gradual whitening of the lesion surface, a decrease in lesion size, the lightening of both lesion surface and mucus color and the disappearance of the lesion.<sup>2</sup> The contrasting recovery time between treatment groups using red pomegranate extract gel were due to differences in its concentration. Moreover, the results also showed that the treatment group treated with red pomegranate gel extract at a concentration of 75% demonstrated a shorter



**Figure 1.** The percentage of traumatic ulcer recovery time.

**Table 1.** The mean width and recovery time of traumatic ulcers

Groups	The mean width of ulcers (mm)							The mean of recovery time
	D1	D3	D5	D7	D8	D9	D10	
Group 12.5%	7.413	5.388	1.734	0.556	0.298	0.196	0	9.3
Group 25%	9.412	4.533	1.254	0.708	0.196	0	-	8.5
Group 50%	8.311	4.369	0.843	0.196	0	-	-	6.8
Group 75%	9.604	2.508	0.508	0	-	-	-	6.5
PC Group	13.154	5.617	2.781	0.785	0.349	0	-	8.3
NC Group	12.767	4.352	2.258	0.9	0.6	0.298	0	9.8

**Table 2.** Mann-Whitney test results

Groups	Group 12.5%	Group 25%	Group 50%	Group 75%	PC Group	NC Group
Group 12.5%	-	.096	.017*	.015*	.098	.186
Group 25%		-	.036*	.017*	.752	.032*
Group 50%			-	.617	.099	.017*
Group 75%				-	.044*	.015*
PC Group					-	.034*
NC Group						-

Note: \*significant difference.

recovery time than the positive control group to which 0.1% triamcinolone acetonide had been administered. This contrast was due to red pomegranate possessing anti-inflammatory, antibacterial, antiviral, antifungal and antioxidant characteristics,<sup>7</sup> while 0.1% triamcinolone acetonide demonstrates anti-inflammatory, antipruritic and hypo-allergic qualities.<sup>11</sup>

The treatment group to which 75% red pomegranate extract gel was administered ranked highest in terms of accelerating the healing process in traumatic ulcers present in the oral mucosa. The more rapid healing process of traumatic ulcers in the group with the red pomegranate extract gel was due to the bioactive components contained, one such component being ellagic acid which plays an anti-inflammatory role. Pomegranate is known to be capable of inhibiting the activation of nuclear factor kappa beta (NF- $\kappa$ ), cyclooxygenase (COX) and lipoxygenase (LOX), thereby limiting the number of inflammatory cells migrating to the injured tissue. As a result, the inflammatory reaction will be shorter and the proliferation ability of transforming growth factor beta (TGF- $\beta$ ) uninhibited. This process triggers the immediate activation of the proliferation phase.<sup>7,12</sup>

Ellagic acid is also known to be a polyphenol which demonstrates the ability not only to regulate the fibrosis process by reducing the excessive levels of collagen, the expression of transforming growth factor beta 1 (TGF- $\beta$ 1) and the amount of alpha-smooth muscle actin ( $\alpha$ -SMA) in tissues with chronic lesions, but also to decrease the production of reactive oxygen species (ROS).<sup>7</sup> Another function of ellagic acid is to protect cell damage due to free radicals. This ability synergistically increases when ellagic acid is combined with another element within pomegranate, a natural dye called anthocyanidin, which also functions as a powerful antioxidant.<sup>7</sup> Anthocyanidin is an antioxidant that has been proven to improve blood vessel function, thereby accelerating the healing process.<sup>7</sup> Flavonoids can also stabilize reactive oxygen compounds which potentially reduce damage caused by free radicals. As an antioxidant, flavonoids promote anti-inflammatory activity.<sup>13</sup>

The results of this study revealed that the treatment group administered with 50% pomegranate extract gel was ranked second to the 75% concentration group. However, there was no significant difference in average recovery time between the treatment group given 50% pomegranate extract gel and the group administered with 75% pomegranate extract gel. This is because the consistency of the gel material, semi-solid and slightly viscous, is almost identical. Therefore, there is little difference between 50% pomegranate extract gel and 75% pomegranate extract gel in terms of the absorption of active substances present in the mucosa affected by traumatic ulcers. Of all the treatment groups to which red pomegranate extract gel was administered, the group with 12.5% red pomegranate extract gel had the lowest recovery time. This is because the consistency of pomegranate extract gel at concentrations of 75% and 50% is very thick compared to that at a concentration of

25%. The 25% concentration pomegranate extract gel is light brown in color indicating that the composition of the extract is extremely restricted compared to gel at the higher concentration.

The results of the study showed that the positive control group given 0.1% triamcinolone acetonide ranked third. The results also showed that the recovery time of the positive control group was more rapid than that of the negative control group with distilled water. Similarly, a previous study argued that the average recovery time of traumatic ulcers treated with 0.1% triamcinolone acetonide was shorter, at 5.3 days, than that treated only with distilled water (8.2 days).<sup>14</sup> The administration of distilled water in the study aimed to establish how traumatic ulcers are healed without the aid of active substances. The average recovery time of traumatic ulcers was 9.8 (9 days 22 hours 16 minutes) which is in accordance with the theory that traumatic ulcers can heal themselves within a period of 7-14 days.<sup>3</sup>

Several factors affect the normal wound healing process which are divided into two groups, namely; local factors and systemic factors. One of the systemic factors that can influence healing is the provision of corticosteroid drugs, namely; 0.1% triamcinolone acetonide. Corticosteroid drugs inhibit mediators and cellular immune response during inflammation by stimulating the formation of proteins (lipocortin) that inhibit phospholipase A2. This prevents activation of the arachidonic acid cascade and prostaglandin secretion which, in turn, reduces the number of lymphocytes and monocytes in the periphery and inhibits the ability of plasminogen activators (PAs) to convert plasminogen into the plasmin which plays a role in breaking down kininogen to kinin and functions as a vasodilator.<sup>10</sup>

CMC-Na can be used as a gelling agent in red pomegranate extract gel preparations due to its high degree of stability under both acidic and basic conditions (pH 2-10). In addition, CMC-Na has several advantages, including its ability to produce gels that are neutral, colorless, stable, tasteless, its strong resistance to microbial attack and its consistent viscosity.<sup>15</sup>

The results indicated significant differences between each of the treatment groups, administered with red pomegranate extract gel at concentrations of 25%, 50% and 75%, and the negative control group. They also confirmed the ability of such gel to accelerate the healing process in traumatic ulcers. Moreover, there was a significant difference in recovery time between the group which received red pomegranate extract gel at the concentration of 75% and those groups administered with the gel at concentrations of 12.5% and 25%, as well as the positive and negative control groups. A significant difference in recovery time also existed between the group given red pomegranate extract gel at a concentration of 50% and those groups receiving such gel at concentrations of 12.5% and 25%, in addition to the positive and negative control groups. This means that the more concentrated the extract, the higher the quantity of drugs absorbed and the

greater the acceleration of the healing process in traumatic ulcers.<sup>15</sup> The optimum concentration of red pomegranate extract gel for accelerating the healing process in traumatic ulcers is 75%.

## ACKNOWLEDGEMENTS

We would like to express our sincere gratitude to Universitas Jember for its financial support and particularly to both the Chancellor and its Head of the Research Institute and Community Service.

## REFERENCES

1. Sunarjo L, Hendari R, Rimbyastuti H. Manfaat xanthone terhadap kesembuhan ulkus rongga mulut dilihat dari jumlah sel PMN dan fibroblast. *ODONTO Dent J*. 2015; 2(2): 14–21.
2. Langlais RP, Miller CS, Nield-Gehrig JS. Atlas berwarna: Lesi mulut yang sering ditemukan. 4th ed. Jakarta: EGC; 2014. p. 172–3.
3. Langkir A, Pangemanan DHC, Mintjelungan CN. Gambaran lesi traumatik mukosa mulut pada lansia pengguna gigi tiruan sebagian lepasan di panti werda kabupaten Minahasa. *e-GIGI*. 2015; 3: 1–8.
4. Skidmore-Roth L. *Mosby's 2014 nursing drug reference*. 27th ed. Missouri: Mosby Elsevier; 2014. p. 40–3.
5. Budi DTW. Efek salep ekstrak herba meniran (*Phyllanthus Niruri* L.) dibandingkan dengan Triamcinolone Acetonide 0.1% terhadap proses penyembuhan luka sayat mukosa rongga mulut tikus Wistar jantan secara histopatologi. Thesis. Bandung: Universitas Kristen Maranatha; 2017. p. 1–3.
6. Kshitiz P, Shipra Z, Rani S, Jayanti S. Anti-cariogenic effects of polyphenol plant products-a review. *Int J Res Ayurveda Pharm*. 2011; 2(3): 736–42.
7. Hernawati S. Ekstrak buah delima sebagai alternatif terapi recurrent aphthous stomatitis (RAS). *Stomatognathic - J Kedokt Gigi*. 2015; 12: 20–5.
8. Setiadhi R, Sufiawati I, Zakiawati D, Nur'aeny N, Hidayat W, Firman DR. Evaluation of antibacterial activity and acute toxicity of pomegranate (*Punica granatum* L.) seed ethanolic extracts in swiss webster mice. *J Dentomaxillofacial Sci*. 2017; 2(2): 119–23.
9. Mujayanto R. Pengaruh zinc sulfat 1% topikal terhadap jumlah makrofag ulkus traumatikus mulut tikus Wistar diabetes. Thesis. Surabaya: Universitas Airlangga; 2016. p. 30–40.
10. Mara RM. Pengaruh ekstrak propolis terhadap penyembuhan ulkus traumatik pada mukosa oral. Thesis. Banda Aceh: Universitas Syiah Kuala; 2014. p. 40–54.
11. drugs.com. Kenalog Orabase - FDA prescribing information, side effects and uses. 2018. Available from: <https://www.drugs.com/pro/kenalog-orabase.html>. Accessed 2018 Jul 18.
12. Pramono A, Mayasari LO. Efektifitas pemberian ekstrak gel belimbing manis (*Averrhoa carambola* Linn) terhadap kesembuhan ulkus traumatikus studi in vivo terhadap mukosa tikus (Strain Wistar). In: *Prosiding Seminar Nasional Publikasi Hasil-Hasil Penelitian dan Pengabdian Masyarakat*. Semarang: Universitas Muhammadiyah Semarang; 2017. p. 39–44.
13. Zhang Y, Krueger D, Durst R, Lee R, Wang D, Seeram N, Heber D. International multidimensional authenticity specification (IMAS) algorithm for detection of commercial pomegranate juice adulteration. *J Agric Food Chem*. 2009; 57(6): 2550–7.
14. Rahmina P. Pengaruh ekstrak daun pacar kuku (*Lawsonia Inermis*) 7,5% terhadap penyembuhan ulkus traumatik pada mukosa oral (penelitian ada tikus odel). Thesis. Banda Aceh: Universitas Syiah Kuala; 2013. p. 62.
15. Istiana S. Formulasi sediaan gel basis CMC-Na ekstrak etanol daun cocor bebek (*Kalanchoe pinnata* (Lmk.) Pers.) sebagai penyembuh luka bakar pada kelinci. Thesis. Surakarta: Universitas Muhammadiyah Surakarta; 2016. p. 1–12.