

Thymoquinone of Black Cumins Effect towards Socket Bone Formation Process Post Extraction in Diabetic-Induced Rats

¹Sabrina M. Pratama, ²Mei Syafriadi, ³Pudji Astuti and ²Dwi Merry CH.R

¹Faculty of Dentistry, ²Departement of Pathology Anatomy,

³Departement of Biomedical Science, Faculty of Dentistry, Jember University, Jember, Indonesia

Abstract: The objective was to determine the effect of thymoquinone towards socket bone formation process post extraction in diabetic-induced rats. About 27 male Wistar rats were induced diabetes by using streptozotocin (50 mg/b.w) intravenously. Rats with blood glucose level ≥ 250 mg/dL were considered DM and were divided into Thymoquinone (Tq), Metformin (Met) and Control (C) group. The treatments were given start from the 1st day of DM. On the 7th day after treatment, its mandibular left first molar tooth was extracted. On the 3rd, 7th and 10th day post extraction, 3 rats of each group were euthanized. Blood glucose level was measured before and after diabetes induction, before extraction and euthanized. Paraffin embedding tissue processing method and HE and Mallory's Trichrome staining were used to observing the socket bone healing. Tq treatment significantly decreased the blood glucose level on the 10th day post extraction although, it was still above the normal range (334.3 ± 65.9 mg/dL). Histologically, socket bone healing process in Tq group showed a continuously formation of provisional matrix, woven bone and lamellar bone on the 3rd, 7th and 10th-day post extraction compared to Met and C group. The antidiabetic properties of Tq may well-related to socket bone healing and moreover, Tq also may stimulates the osteoblasts activity which the function was essential in bone formation process. Treatment with Tq is effective to prevent the delay of socket bone healing in socket post extraction in diabetic rats by lowering blood glucose level and by stimulating the osteoblasts activity.

Key words: Bone formation process, diabetes, post extraction socket, thymoquinone, blood, glucose

INTRODUCTION

Diabetes Mellitus (DM) is a chronic disease that disturbs carbohydrate, protein and fat metabolisms (Guyton and Hall, 2016). Its worldwide prevalence is predicted to increase from 6.4% (2010) to 7.7% (2030) and will be higher every year (Shaw *et al.*, 2010). The hallmark of DM, hyperglycemia will increase the interaction between glucose and biologic molecules, i.e., protein and produce the Advanced Glycation End products (AGEs). These products may accumulate in the tissue which could disturb the neutrophils function, prolong the inflammation phase and induce the apoptotic cells (Guyton and Hall, 2016; Goldin *et al.*, 2006; Salvayre *et al.*, 2009). These negative effects of AGEs were suggested to induce the delay of wound healing.

Diabetic condition is a risk factor to perform medical treatment such as tooth extraction because the post extraction complication may arise (Maskari *et al.*, 2011; Lagares *et al.*, 2005; Alikhani *et al.*, 2007). To prevent this, blood glucose control has often been performed by giving therapy with synthetic agents. Unfortunately, this method

has disadvantages such as uncomfortable side-effects and multiple contraindications (Inzucchi *et al.*, 2015). This caused the increased of public interest to the alternative therapy globally (WHO., 2004). Black cumin (*Nigella sativa* L.) has been known for centuries for its wide range therapeutic properties (Mathur *et al.*, 2011). Thymoquinone (Tq), the highest active compound in its volatile oil has been often studied for its role as antidiabetic agent (Mathur *et al.*, 2011; Abdelmeguid *et al.*, 2010; Ali *et al.*, 2008). Recently, in vitro study also showed Tq potential to stimulate the anabolic activity of osteoblast (Wirries *et al.*, 2013). However, there is still no study to determine the effect of Tq towards the post-extraction socket bone formation process in diabetic condition. This study aims to determine the effect of Tq in post extraction socket bone formation process in diabetic-induced rats.

MATERIALS AND METHODS

Materials: Thymoquinone (Sigma-Aldrich, USA) and Strep to Zotocin (STZ) (Bioworld, USA) was purchased in

Gamma Scientific Biolab, Indonesia. Metformin (500 mg) was purchased from Kimia-Farma Pharmacy, Indonesia. All other ingredients used were of analytical grade.

Animals: About 27 healthy male albino rats of Wistar strain, weighing 150-250 g were used in this study. They were maintained in the environment with 12 h light/dark cycle and were fed on pellet diet from Turbo, Indonesia and water ad libitum. All procedures were reviewed and approved by the Ethical Committee of Medicine Faculty, Jember University, Indonesia.

Streptozotocin-induced diabetes: Rats were fasted for 12 h prior to diabetes-induction but still were given water ad libitum. Blood glucose level was measured from its lateral tail vein with Glucometer (EasyTouch, Indonesia). Diabetes-induction was done by giving intravenous (i.v) tail injection of freshly prepared STZ (50 mg/kg b.w) that was dissolved in 0.1 M citrate buffer (pH 4.5). Then, rats were allowed to drink glucose solution overnight to prevent the STZ-induced hypoglycemia. The 24 h after injection, the blood glucose level was measured and those with blood glucose levels ≥ 250 mg/dL were considered DM-positive (Pari and Sankaranarayanan, 2009).

Treatment before and post extraction: Diabetic rats were divided into three groups; Thymoquinone (Tq), Metformin (Met) and Control (C). Each group consisted of three subgroups based on the observational days which are on the 3rd, 7th and 10th day post extraction (Kim *et al.*, 2012). In Tq group, we used the therapeutic dose of thymoquinone in rats 80 mg/kg b.w and dissolved it in olive oil because of its solubility in lipid every once daily (Pari and Sankaranarayanan, 2009). In Met group, we also used the therapeutic dose of metformin in rats 100 mg/kg b.w and dissolved it in distilled water; every thrice a day (Cheng *et al.*, 2006). The C group was given distilled water; every once daily. All treatments were given intragastrically, since, the 1st day of DM-positive until on the 3rd, 7th and 10th day post extraction in each subgroup, respectively.

Extraction procedure: On the 7th day after treatment, the rats mandibular left molar was extracted. Prior to extraction, the blood glucose was measured. The rats were anesthetized with 0.1 mL Ketamine intramuscularly. After the molar was extracted, the socket wound was enlarged using contra angle low speed with No. 1 diamond round bur (5000 rpm/2 sec) to resemble the post extraction socket's condition in the patient. After that, the wound was disinfected with povidone iodine to prevent infection.

Samples collection and histology evaluation: On the 3rd, 7th and 10th day post extraction, 3 rats from each group were euthanized by chloroform over inhalation method. Prior to euthanize, blood glucose level was measured. The left mandibular was collected and fixated in 10% formalin solution for 24 h and decalcified in 10% formic acid for 7-10 days. The samples were processed with Tissue Tek VIP 5 Jr., Japan by paraffin embedding method and were cut by step-serial section technique with apico-coronal vertical plane (thickness: 5 μ m). The tissue was being stained by Hematoxylin-Eosin (HE) and Mallory's Trichromes method. Bone healing was observed on the 1/3 apical part of the socket because the rapid osteogenesis occurred there. Histological observation was done by using Optilab light microscope with 40 and 1000x magnification. We observed the sequence of bone formation tissue which consists of Blood Clot (BC), Provisional Matrix (PM), Woven Bone (WB) and Lamellar Bone (LB).

Statistical analysis: Blood glucose level before and post-extraction was showed as mean \pm SD in each subgroup. These data was analyzed with ANOVA test and followed by a Least Significant Difference (LSD) test to determine the treatment effect on each subgroup. Data analysis was performed with SPSS Software 22th Version and $p < 0.05$ was considered as significant. The histological evaluation results were expressed as percentage and image for each subgroup.

RESULTS AND DISCUSSION

Blood glucose level: The results of blood glucose level before and post-extraction were shown in Table 1. The lowest blood glucose was found in Tq group on the 10th day post extraction 334,33 mg/dL and the highest was found in Met group on the 10th post extraction 575 \pm 43,3 mg/dL. Tq treatment significantly decreased ($p < 0.05$) the blood glucose level compared to Met and C groups on the 10th day post extraction.

This study is a model of DM patient who got treated by tooth extraction treatment. The treatment with thymoquinone and metformin was interpreted as blood glucose control therapy before and post-extraction. The distilled water treatment was interpreted as DM patients who didn't get any blood glucose control therapy.

In Tq group, the blood glucose level was decreased on the 3rd, 7th and 10th day post extraction compared to 7th day after treatment (extraction day). It also reached the lowest value on the 10th day post-extraction, although, it was still above the normal value. This finding suggests

Table 1: Blood glucose level before and post extraction in Tq, Met and C group

Groups	Blood glucose level before extraction ^a (mg/dL)		Blood glucose level post extraction ^b (mg/dL)		
	1st day	7th day	3rd day	7th day	10th day
Tq	416.56±96.9	528.11±59.2	511.67±48.4	521.33±78.7	334.33±65.9*, #
C	496.11±78.9	488.89±107.1	466±118.7	425±34.6	538±55.0*
Met	489.44±96.8	526.89±81.6	559.5±57.3	465.3±116.7	575±43.3#

a) Mean±SD, n = 9; b) Mean±SD, n = 3; *p<0.05 between Tq and C group on 10th day post extraction; # p<0.05 between Tq and Met group on 10th day post extraction

the longer the treatment, the antidiabetic effect of Tq will be more noticeable. This result was supported by the findings by Fararh *et al.* (2005) who showed that antidiabetic effect of Tq was started to show on the 10th day after treatment and more noticeable on the 20th and 30th day after treatment (Fararh *et al.*, 2005).

Tq antidiabetic mechanisms were demonstrated by Pari and Sankaranarayanan (2009) who discovered that Tq treatment decreased the level of gluconeogenic enzymes such as glucose-6-phosphatase and fructose-1,6-bisphosphatase on diabetic rats. Moreover, Abdelmeguid *et al.* (2010) showed that Tq treatment repaired the damaged beta cell of diabetic rats and regenerate it to the extent almost look similar as the beta cell in normal rats. This regeneration may restore its function to secretes insulin, thus, stimulates the blood glucose level decrease in Tq group.

Metformin was an antidiabetic agent that was often consumed by type 2 DM patient (Inzucchi *et al.*, 2015; Cheng *et al.*, 2006). It also was of-ten used in diabetes animal model research (Saleh *et al.*, 2013). Cheng (2006) showed metformin decreased the mRNA or protein levels of gluconeogenic enzymes (PEPCK) which stimulates the decrease of gluconeogenesis that lower the blood glucose level (Cheng *et al.*, 2006). However, our results were in contrary because the blood glucose in Met group was reached the highest level on the 10th day post extractionm, although, we used the same therapeutic dose as Cheng *et al.* (2006). This difference may happen because of the ad libitum food consumption which was done to compensate polyphagia condition in diabetic rats. Based on FDA, food could decrease the bioavailability of metformin by lowering its maximum concentration and Area Under the Curve (AUC) and prolong the time to reach C_{max} (T_{max}) (FDA., 2016).

In C group, on the 3rd and 7th day post extraction, the blood glucose level was decreased. This condition may happen because of different host response and adaptation mechanism to STZ. Although, the diabetes induction in rats with 50 mg/kg b.w STZ dose was already proved in the previous study, there are unknown factors which could decrease the blood glucose level (Abdelmeguid *et al.*, 2010; Kanter *et al.*, 2001).

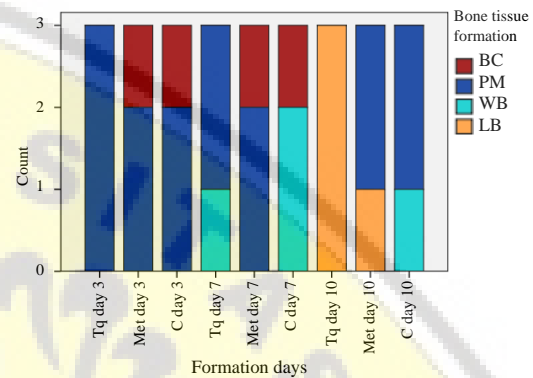


Fig. 1: Graphic bar of bone tissue formation percentage on 3rd, 7th and 10th day post extraction in each subgroup, respectively

Histological evaluation of bone formation process: The result from histology evaluation of socket bone healing was showed in the graphic bar (Fig. 1). Histologically, on the 3rd and 7th day post extraction, there was no blood clot in Tq group (BC = 0%) while it was still found in Met and C group (BC = 33.3%). On the 7th day post extraction, we observed woven bone in Tq group and C group (WB = 33.3%; WB = 66.7%) while there was no WB in Met group (WB = 0%). On the 10th day post extraction, the lamellar bone was already formed in Tq and Met group (LB = 100%; LB = 33.3%) while there was no lamellar bone in C group (LB = 0%). Histologically, the bone tissue formation in Tq, Met and C group were shown in Fig. 2-4, respectively.

Hyperglycemia was known to induced the delayed wound healing (Salvayre *et al.*, 2009; Collison *et al.*, 2002 McCabe, 2012). It could elevates the interaction between glucose and biologic molecules i.e., protein, lipid which was known as glycation or Maillard reaction and the result was the modification product called AGEs (Salvayre *et al.*, 2009). AGEs has been known caused the impairment of immune host response, disturbed cellular function and increase pro-inflammatory molecules (Salvayre *et al.*, 2009; Collison *et al.*, 2002; McCabe, 2012). Those conditions are risks to medical treatment as tooth extraction because post extraction complication such dry socket or alveolar osteitis may occur (Maskari *et al.*, 2011; Lagares *et al.*, 2005; Bowe *et al.*, 2012).

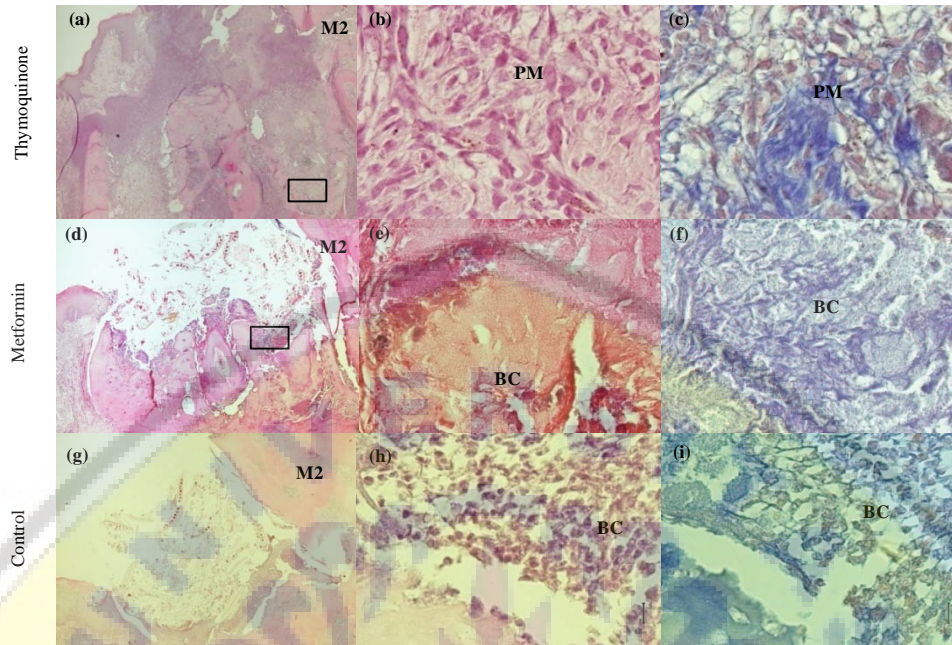


Fig. 2: HE staining (a-h) and Mallory's Trichrome staining (c, f, i) of the socket on 3rd day post extraction. In the 1/3 apical socket, Provisional Matrix (PM) (b-c) consisted of collagen fibers and mesenchymal cells. Blood Clot (BC) (e-f-h-i) consisted of necrotic cell and remnants of periodontal ligaments. b-c, e-f, h-i are higher magnified views of boxed areas in a, d, g, respectively. M2: Mandibular second left molar (a-d-g; 40×magnification and b-c-e-f-h-i; 1000×magnification)

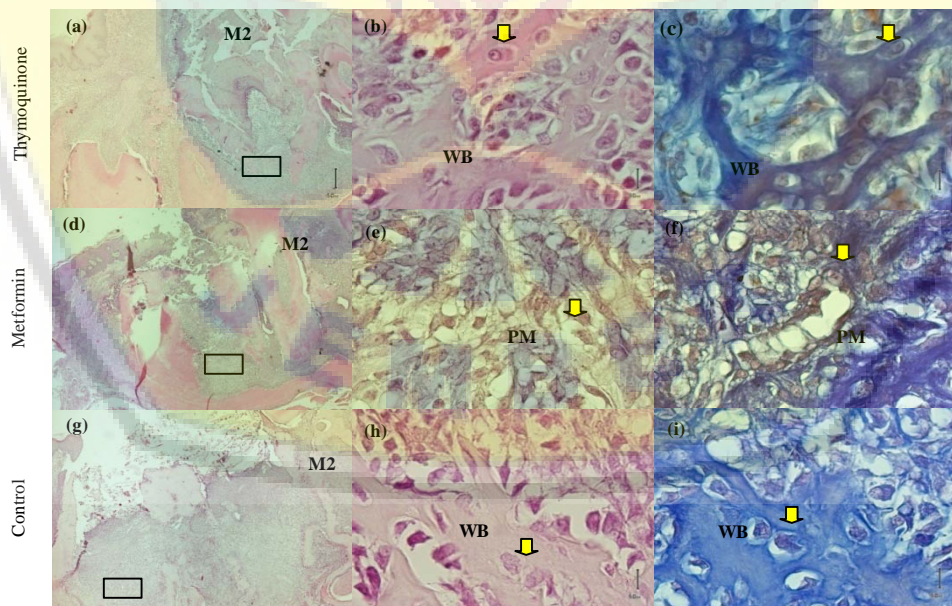


Fig. 3: HE staining (a-h) and Mallory's Trichrome staining (c, f, i) of the socket on 7th day post extraction. In the 1/3 apical socket, Woven Bone (WB) (b-c-h-i) was looked like island form (spicule) that rich of random collagen fibers and Mesenchymal Osteoblasts (MOBL) (yellow arrow); Provisional Matrix (PM) (e-f). b-c, e-f, h-i are higher magnified views of boxed areas in a, d and g, respectively. M2: Mandibular second left molar (a-d-g; 40×magnification and b-c-e-f-h-i; 1000×magnification)

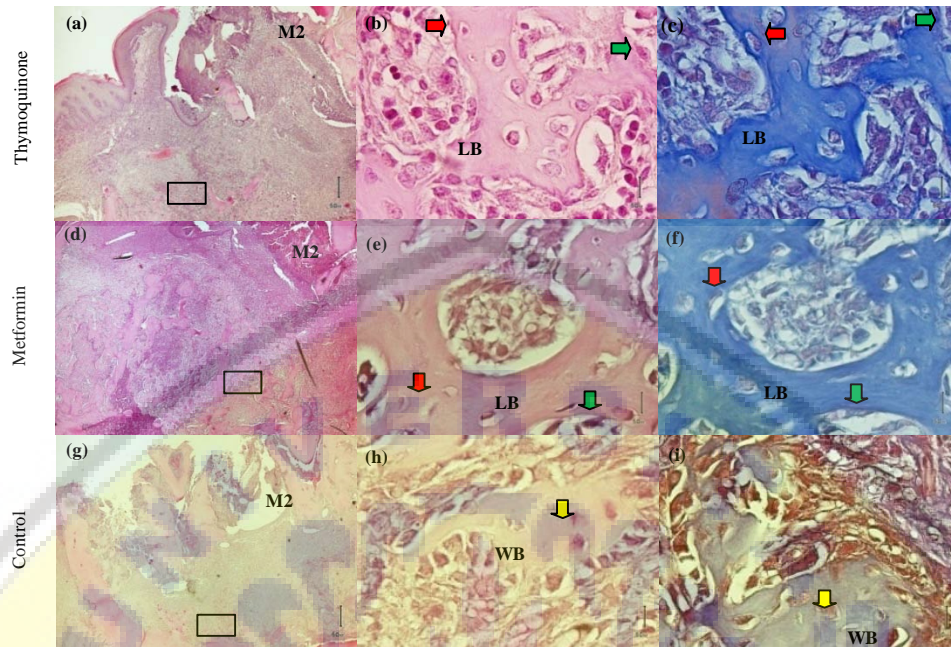


Fig. 4: HE staining (a, b, d, e, g, h) and Mallory's Trichrome staining (c, f, i) of the socket on 10th day post extraction. In the 1/3 apical socket, Lamellar Bone (LB) (b-c-h-i) was rich of SOBL (green arrow) and osteocyte (red arrow); Woven Bone (WB) (h-i) that looked like as spicule (island forms) with Mesenchymal Osteoblasts (MOBL) (yellow arrow). b-c, e-f, h-i are higher magnified views of boxed areas in a, d and g, respectively. M2: Mandibular second left molar (a-d-g; 40×magnification and b-c-e-f-h-i; 1000×magnification)

In normal and healthy rats, on the 3rd day post extraction, the granulation tissue has already filled the post-extraction socket and mesenchymal cells started to proliferate and differentiate into Mesenchymal Osteoblasts (MOBL) (Larjava, 2012; Shapiro, 2008). MOBL will start the intramembranous ossification process in the socket by secreting the Type-1-collagen to form the temporary bone Matrix (PM) (Larjava, 2012; Shapiro, 2008; Vieira *et al.*, 2005). On the 3rd day post extraction, the PM was already formed in all groups. However, in Met and C group, the BC was still observed. This condition shows the delayed socket wound healing which may happen because of the very high blood glucose level (>450 mg/dL) (Chase, 2006). Hyperglycemia may increase the interaction between AGEs and its specific Receptor (RAGEs) on the neutrophils surface membrane which could disrupt its chemotaxis and phagocytosis function (Salvayre *et al.*, 2009; Collison *et al.*, 2002). This interaction also activates the NF- κ B which regulates the activation of cytokines pro-inflammatory such as IL-1 β , TNF- α and MetalloProtease (MMP-1 to MMP-3, MMP-13) (Salvayre *et al.*, 2009). These conditions may prolong the inflammation phase, further damage the tissue and inhibit the next phase of wound healing (Salvayre *et al.*, 2009; Chase, 2006; Orsted *et al.*, 2011).

In normal and healthy rats, on the 7th day post extraction, PM was already organized to immature bone (WB) and MOBL begin to moves to the surface of WB that called Surface Osteoblast (SOBL) (Larjava, 2012; Shapiro, 2008). In Tq and C group, WB was already formed while in Met group there was no WB on the 7th day post extraction. Meanwhile, although the blood glucose in Tq group was higher than Met group, there was no BC that remained in the socket. This suggests that Tq treatment may also help the bone formation by other mechanisms than lowering the blood glucose level. *In vitro* study by Wirries *et al.* (2013) demonstrated the Tq stimulates the anabolic activity of osteoblasts by increasing the expression of alkaline phosphatase, osteocalcin, osteopontin which were essentials in the bone formation process. Tq also increased the expression of Bone Morphogenetic Protein-2 (BMP-2) which able to induce another gene expression that regulates bone formation (Wirries *et al.*, 2013). Our result was in agreement with Wirries *et al.* (2013) that although the blood glucose level was very high, the bone formation process was not delayed which was indicated by no BC remained.

In normal and healthy rats, on 10th day post extraction, the WB was already undergo remodeling to LB

which shows the advanced or mature stage of bone tissue formation process (Larjava, 2012; Shapiro, 2008). In Tq group, all sockets has already filled by LB while in Met group only one socket and there was no LB formation in C group. We suggest that the significantly decrease of blood glucose level in Tq group may relate to this result. The decrease of blood glucose level may inhibit the production of AGEs which prevent the further accumulation and interaction of AGEs-RAGEs. One of most dominant AGEs product found in DM patients was Carboxymethyl-Modified collagen Lysine (CML-collagen) which easily formed because collagen is a long half-life protein. This modification compound can disturb differentiation process, osteoblast functions and even trigger its apoptosis (Alikhani *et al.*, 2007). The decrease in blood glucose level caused by Tq and Metformin treatment was allegedly lower the amount of AGEs products and prevent its interaction from occurring.

CONCLUSION

Antidiabetic properties of thymoquinone may decrease the AGEs-RAGEs interaction and prevent delayed wound healing. Thymoquinone also has ability to stimulates the anabolic activity of osteoblasts which could prevent the delayed bone healing process. These results prove the positive effect of thymoquinone in socket bone healing in diabetic condition.

RECOMMENDATIONS

Further studies are needed to better understand its role in bone formation and wound healing, especially in the diabetic condition.

REFERENCES

- Abdelmeguid, N.E., R. Fakhoury, S.M. Kamal and R.J.A. Wafai, 2010. Original article: Effects of Nigella Sativa and Thymoquinone on biochemical and subcellular changes in pancreatic B-cells of streptozotocin-induced diabetic rats. *J. Diabetes*, 2: 256-266.
- Ali, A.A., A.A. Alkhawajah, M.A. Randhawa and N.A. Shaikh, 2008. Oral and intraperitoneal LD50 of thymoquinone, an active principle of Nigella sativa, in mice and rats. *J. Ayub Med. Coll Abbottabad*, 20: 25-27.
- Alikhani, M., Z. Alikhani, C. Boyd, M. Maclellan and M. Raptis *et al.*, 2007. Advanced glycation end products stimulate osteoblast apoptosis via the MAP kinase and cytosolic apoptotic pathways. *Bone*, 40: 345-353.
- Bowe, D., S. Rogers and L. Stassen, 2012. The management of dry socket/alveolar osteitis. *J. Irish Dent. Assoc.*, 57: 305-310.
- Chase, HP., 2006. *Understanding Diabetes*. 11th Edn., University Press of Colorado, Colorado, USA.,.
- Cheng, J.T., C.C. Huang, I.M. Liu, T.F. Tzeng and C.J. Chang, 2006. Novel mechanism for plasma glucose-lowering action of metformin in streptozotocin-induced diabetic rats. *Diabetes*, 55: 819-825.
- Collison, K.S., R.S. Parhar, S.S. Saleh, B.F. Meyer and A.A. Kwaasi *et al.*, 2002. RAGE-mediated neutrophil dysfunction is evoked by Advanced Glycation End Products (AGEs). *J. Leukocyte Biol.*, 71: 433-444.
- FDA., 2016. Metformin hydrochloride tablets. Food and Drug Administration, Maryland, USA.
- Fararh, K.M., Y. Shimizu, T. Shiina, H. Nikami, M.M. Ghanem and T. Takewaki, 2005. Thymoquinone reduces hepatic glucose production in diabetic hamsters. *Res. Vet. Sci.*, 79: 219-223.
- Goldin, A., J.A. Beckman, M. Schimdt and M.A. Creager, 2006. Advanced glycation end products: Sparking the development of diabetic vascular injury. *Circulation*, 114: 597-605.
- Guyton, A.C. and J.E. Hall, 2016. *Textbook of Medical Physiology*. 13th Edn., Elsevier, Philadelphia, Pennsylvania, .
- Inzucchi, S.E., R.M. Bergenstal, J.B. Buse, M. Diamant and E. Ferrannini *et al.*, 2015. Management of hyperglycemia in type 2 diabetes: A patient-centered approach. *Diabetes Care*, 38: 140-149.
- Kanter, M., I. Meral, Z. Yener, H. Ozbek and H. Demir, 2001. Partial regeneration/ proliferation of the beta cells in the islets of langerhans by Nigella Sativa L., in streptozotocin-induced diabetic rats. *Tohoku J. Exp. Medical.*, 201: 213-319.
- Kim, D.J., J.K. Cha, C. Yang, A. Cho and J.S. Lee *et al.*, 2012. Changes in periodontium post extraction of a periodontally-involved tooth in rats. *J. Periodontal Implant Sci.*, 42: 158-165.
- Lagares, D.T., M.A.S. Figallo, M.M.R. Ruiz, P.I. Cossio and M.G. Calderon *et al.*, 2005. Update on dry socket: A review of the literature. *Oral Med., Oral Pathology Oral Surg.*, 10: 77-85.
- Larjava, H., 2012. *Oral Wound Healing: Cell Biology and Clinical Management*. Wiley-Blackwell, Hoboken, New Jersey, ISBN:978-0-8138-0481-1, Pages: 412.
- Maskari, A.Y.A., M.Y.A. Maskari and S.A. Sudairy, 2011. Oral manifestations and complications of diabetes mellitus: A review. *Sultan Qaboos Univ. Med. J.*, 11: 179-186.

- Mathur, M.L., J. Gaur, R. Sharma and K.R. Haldiya, 2011. Antidiabetic properties of a spice plant *Nigella sativa*. *J. Endocrinol. Metab.*, 1: 1-8.
- McCabe, L.R., 2012. The diabetes-bone relationship. *J. Diabetes Metab.*, 1: 1-2.
- Orsted, H.L., D. Keast, L.F. Lalande and M.F. Megie, 2011. Basic principles of wound healing. *Wound Care Can.*, 9: 4-12.
- Pari, L. and C. Sankaranarayanan, 2009. Beneficial effects of thymoquinone on hepatic key enzymes in streptozotocin-nicotinamide induced diabetic rats. *Life Sci.*, 85: 830-834.
- Saleh, D.O., A.R. Bayoumi, W.I. El-Eraky and A.S. El-Khatib, 2013. Streptozotocin-induced vascular and biochemical changes in rats: Effects of rosiglitazone vs. metformin. *Bull. Fac. Pharm. Cairo Univ.*, 51: 131-138.
- Salvayre, A.N., R. Salvayre, N. Auge, R. Pamplona and M.P. Otin, 2009. Hyperglycemia and glycation in diabetic complications. *Antioxid. Redox. Signaling*, 11: 3071-3109.
- Shapiro, F., 2008. Bone development and its relation to fracture repair. The role of mesenchymal osteoblasts and surface osteoblasts. *Eur. Cell Mater.*, 15: 53-76.
- Shaw, J.E., R.A. Sicree and P.Z. Zimmet, 2010. Global estimates of the prevalence of diabetes for 2010 and 2030. *Diabetes Res. Clin. Pract.*, 87: 4-14.
- Vieira, A.E., C.E. Repeke, S.B. Ferreira Jr., P.M. Colavite and C.C. Bigueti *et al.*, 2015. Intra-membranous bone healing process subsequent to tooth extraction in mice: Micro-computed tomography, histomorphometric and molecular characterization. *PLOS. One*, 10: 1-22.
- WHO., 2004. Guidelines of developing consumer information of proper use traditional, complementary and alternative medicine. World Health Organization, Geneva, Switzerland.
- Wirries, A., A.K. Schubert, R. Zimmerman, S. Jabari, S. Ruchholtz and N. El-Najjar, 2013. Thymoquinone accelerates osteoblast differentiation and activates bone morphogenetic protein-2 and ERK pathway. *Int. Immunopharmacol.*, 15: 381-386.