

open access

# Folia Medica Indonesiana

p-ISSN 2355-8398 | e-ISSN 2599-056X

Published by:  
Universitas Airlangga  
<http://e-journal.unair.ac.id/FMI>

**Vol. 59 No. 2 (2023): June**

**Current Issue**



Vol. 59 No. 2 (2023): June  
Published: 10.06.2023

**Original Research Report**

- Clinical Profiles and II-6 Level Analysis of Critical Covid-19 Patients Receiving Lopinavir-Ritonavir**  
Erwin Astha Triyono, Nancy Margarita Rehatta, Nabillah, Feriawan Tan | 92-98  
Abstract : 621 | PDF : 248  
DOI: 10.20473/fmli.v59i2.44715
- Selected Vegetables and Spices Improve DNA Quality and Histopathological Abnormalities in Roof Rats (Rattus rattus) Exposed to Cement Dust**  
Tajudeen Olanrewaju Yahaya, Titilola Salisu, Mohammed Musa, Abdulrazaq Izuafa, Chidiere Obi, Samuel Ribah, Suleiman Abubakar | 99-107  
Abstract : 294 | PDF : 58  
DOI: 10.20473/fmli.v59i2.42346
- Treatment of Acute Diarrhea in Children Aged 1-5 Years Provided by Doctors in Surabaya**  
Alpha Fardah Athiyah, Insyira Rayhana Irsan, Nurmawati Fatimah | 108-114  
Abstract : 216 | PDF : 57  
DOI: 10.20473/fmli.v59i2.44723
- Stress Levels and Seborrheic Dermatitis in the Class of 2020 Medical Students at a University in Indonesia**  
Eldy, Hari Darmawan | 115-122  
Abstract : 218 | PDF : 37  
DOI: 10.20473/fmli.v59i2.41208
- Detection of Knockdown-Resistance Homozygous Mutant C1534C using Allele-Specific Polymerase Chain Reaction in Aedes Albopictus and Aedes Aegypti**  
Syananda Zahra Fadila, Ahmad Rudi Setiawan, Shifa Fauziyah, Safira Madaniyah, Eryantika Cipta Dewi, Sin War Naw, Sari Edi Cahyaningrum, Tukiran, Teguh Hari Sucipto | 123-129  
Abstract : 248 | PDF : 56  
DOI: 10.20473/fmli.v59i2.39802
- COVID-19 Disease Severity and Blood Test Results in Unvaccinated and Vaccinated Patients at Bhayangkara Hospital, Denpasar, Indonesia**  
Chanif Lutfiyati Muysarah, Ngurah Intan Wiratmini, Anak Agung Sagung Alit, Sukmaningsih | 130-135  
Abstract : 247 | PDF : 74  
DOI: 10.20473/fmli.v59i2.43810
- The Effect of Cabbage (Brassica oleracea var. capitata L.) Extract on Macrophage and Blood Vessel Counts in Clean Wound Tissue of Male Rats (Rattus norvegicus)**  
Nidya Ulfana Tsania, Willy Sandhika, Sawitri | 136-142  
Abstract : 223 | PDF : 47  
DOI: 10.20473/fmli.v59i2.39922
- Bacterial Profile and Antibiotic Use in Catheter-Associated Urinary Tract Infection Patients at a Tertiary Referral Hospital in Surabaya, Indonesia**  
Ahmad Veri Erianto, Tri Pudy Asmarawati, Agung Dwi Wahyu Widodo, Brian Eka Rachman | 143-149  
Abstract : 202 | PDF : 42  
DOI: 10.20473/fmli.v59i2.39919
- Effects of Moringa oleifera Leaf Extract on the Liver of Experimentally-Induced Diabetic Wistar Rats**  
Wahyu Ikhsan, Suryono Suryono, Azham Purwandhono | 150-155  
Abstract : 169 | PDF : 69  
DOI: 10.20473/fmli.v59i2.37526
- Impact on the Kidney of Pancreas Damage due to Streptozotocin-Induced Hyperglycemia**  
Yana Aurora Prathita, Ahmad Aulia Jusuf, Christina Simadibrata, Wahyuningsih, Djaali, Yoshua Viventius | 156-163  
Abstract : 169 | PDF : 46  
DOI: 10.20473/fmli.v59i2.33584
- Workload Indicators of Staffing Need (WISN) for the Required Estimation of Nursing Staff in a Hemodialysis Unit**  
Feli Clarisa Wirni, Sri Lestari Ramadhani Nasution, Chrismis Novalinda Ginting | 164-172  
Abstract : 217 | PDF : 50  
DOI: 10.20473/fmli.v59i2.42309
- Improvement of Cadres' Skills and Knowledge to Provide Comprehensive Health Services for the Elderly**  
Ulrik Djajri, Linda Dewanti, Sulistiawati, Natasya Nurvita Brillianti, Farhan Nurhidayah, Subur Prajittno | 173-179  
Abstract : 168 | PDF : 51  
DOI: 10.20473/fmli.v59i2.39896
- The Effects of Purple Sweet Potato (Ipomoea Batatas L.) Ethanol Extract on Bladder Urothelial Layer and Smooth Muscle Thicknesses in Menopausal Female Wistar Rats**  
Bismantara Aditya Putra, Kadek Budi Santosa, I Wayan Niriyana, Nyoman Golden, Gede Wirya Kusuma Duarsa, Ida Bagus Made Suryawisesa | 180-186  
Abstract : 204 | PDF : 63  
DOI: 10.20473/fmli.v59i2.44621

**Case Series with Scoping Review Discussion**

- Maternal Deaths caused by COVID-19 Infection in the First Year of the Pandemic Wave**  
Muhammad Ilham Aldika Akbar, Pungky Mulawardhana, Manggala Pasca Wardhana, Khanizyah Erza Gumilar, Ecccita Raheestyningtyas, Muhammad Ardian Cahya Laksana, Jimmy Yanuar Anas, Erenwati, Hermanto Tri Joewono, Muhammad Adrians Bachnas, Brahmama Akkandar Tjokropawiro | 187-196  
Abstract : 136 | PDF : 41  
DOI: 10.20473/fmli.v59i2.45226

**Systematic Review**

- Calciferol Status and Clinical Outcomes in Children with Congenital Heart Disease after Heart Surgery**  
Juliam Effendy, Tri Venti Rahayuningsih, Fachrul Razi, Hendra Kurniawan, Azmi, Farhan Marzuki, Herlianta, Rovy Pralama | 204-204  
Abstract : 144 | PDF : 105  
DOI: 10.20473/fmli.v59i2.44534

**Login**  
Username \*  
[ ]  
Password \*  
[ ]  
Forgot your password?  
 Keep me logged in  
[ ] Login [ ] Register

- Focus and Scope
- Section Policies
- Publication Frequency
- Publication Ethics
- Article Processing Charge
- Peer Reviewers
- Peer Review Process
- Open Access Statement
- Archiving
- Reference Manager
- Repository Policy
- External Link
- Plagiarism Check
- Copyright Notice
- ORCID ID Policy
- License Term
- Contact
- Old Website

**Meet Our Editorial Team**

- Scopus**  
Viskasari P. Kalanjati  
Editor-in-Chief  
Universitas Airlangga,  
Indonesia  
Scopus 54388384000
- Scopus**  
Muhammad Miftahussurur  
Editorial Board  
Universitas Airlangga,  
Indonesia  
Scopus 56323903000  
[ ] Read More

**Instruction For Author**

- How to Submit
- Guidelines for Authors
- Online Submission
- Document Template
- Patient Consent for Publication
- Authors' Declaration & CTA

**ISSN**

- Printed ISSN
- Electronic ISSN

**Journal Standing**

**Reference Manager**

**Plagiarism Checker**

**External Links**

**In Collaboration with**

**Accreditation Certificate**

**Visitors**

- Flag Counter
- View My Stats

**Indexed By**






























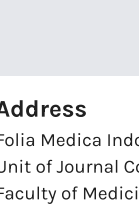

**Information**

- For Readers
- For Authors
- For Librarians

**Keywords**

**Current Issue**

[Home](#) [Editorial Team](#)


- ### Editorial Team
- 
**Viskasari P. Kalanjati**  
**Editor-in-Chief**  
 Department of Anatomy, Histology, and Pharmacology, Faculty of Medicine, Universitas Airlangga, Indonesia  
 International Federation of Associations of Anatomists (IFAA)  
 0000-0002-7005-0025 [Google Scholar](#) [Scopus](#) 54388384000 [5975075](#)
  - 
**Kuntaman Kuntaman**  
**Editorial Board**  
 Faculty of Medicine, Universitas Wijaya Kusuma Surabaya, Indonesia  
 0000-0003-4897-8879 [Google Scholar](#) [Scopus](#) 8700386400 [6086035](#)
  - 
**Muhammad Miftahussurur**  
**Editorial Board**  
 Division of Gastroentero-Hepatology, Department of Internal Medicine, Faculty of Medicine, Universitas Airlangga, Indonesia; Division of Gastroenterology and Hepatology, Baylor College Medicine, US  
 0000-0003-1415-6033 [Google Scholar](#) [Scopus](#) 56323903000 [6031037](#)
  - 
**Aryati Aryati**  
**Editorial Board**  
 Department of Clinical Pathology, Faculty of Medicine, Universitas Airlangga; Indonesian Society of Clinical Pathology and Laboratory Medicine, Indonesia  
 0000-0001-9055-0177 [Google Scholar](#) [Scopus](#) 56054058600 [6043865](#)
  - 
**Irwanto Irwanto**  
**Editorial Board**  
 Department of Child Health, Faculty of Medicine, Universitas Airlangga; Dr. Soetomo General Academic Hospital, Indonesia  
 0000-0002-7573-8793 [Google Scholar](#) [Scopus](#) - [25759](#)
  - 
**Bambang Purwanto**  
**Editorial Board**  
 Department of Physiology and Medical Biochemistry, Faculty of Medicine, Universitas Airlangga, Indonesia  
 0000-0002-3786-7068 [Google Scholar](#) [Scopus](#) 57152859000 [5987193](#)
  - 
**Andrew Paul Smith**  
**Editorial Board**  
 Centre for Occupational and Health Psychology, School of Psychology, Cardiff University, United Kingdom  
 0000-0001-8805-8028 [Google Scholar](#) [Scopus](#) 35429650000 [-](#)
  - 
**Yoshio Yamaoka**  
**Editorial Board**  
 Department of Environmental and Preventive Medicine, Faculty of Medicine, Oita University, Japan  
 0000-0002-1222-5819 [Google Scholar](#) [Scopus](#) 55183784100 [-](#)
  - 
**Franco Servadei**  
**Editorial Board**  
 Department of Neurosurgery, Humanitas University, Italy  
 0000-0002-3595-3464 [Google Scholar](#) [Scopus](#) 7006077203 [-](#)
  - 
**Marten J Postma**  
**Editorial Board**  
 Faculty of Science, Swammerdam Institute for Life Sciences, University of Amsterdam, Netherlands  
 0000-0002-3167-9633 [Google Scholar](#) [Scopus](#) - [-](#)
  - 
**Christianto Lumenta**  
**Editorial Board**  
 Bogenhausen Academic Teaching Hospital, Technical University, Germany  
 0000-0002-4030-0708 [Google Scholar](#) [Scopus](#) 55397690000 [-](#)
  - 
**Dirk Jan Marie de Ridder**  
**Editorial Board**  
 Department of Development and Regeneration, Katholieke Universiteit Leuven, Belgium  
 - [Google Scholar](#) [Scopus](#) - [-](#)
  - 
**Horie Shigeo**  
**Editorial Board**  
 Department of Urology, Faculty of Medicine, Juntendo University, Japan  
 0000-0002-8612-8368 [Google Scholar](#) [Scopus](#) 57222920684 [-](#)
  - 
**Yusuke Suzuki**  
**Editorial Board**  
 Department of Nephrology, Faculty of Medicine, Juntendo University, Japan  
 - [Google Scholar](#) [Scopus](#) 8388474600 [-](#)
  - 
**Arend Frederik Bos**  
**Editorial Board**  
 Division of Neonatology, Faculty of Medical Sciences, University of Groningen, Netherlands  
 - [Google Scholar](#) [Scopus](#) 36839156800 [-](#)
  - 
**Hiroaki Kimura**  
**Editorial Board**  
 Department of Physical Medicine and Rehabilitation, Hiroshima University Hospital, Japan  
 0000-0003-0005-5805 [Google Scholar](#) [Scopus](#) 49763362000 [-](#)
  - 
**Jitti Hanprasertpong**  
**Editorial Board**  
 Division of Gynecologic Oncology, Department of Obstetrics and Gynecology, Faculty of Medicine, Prince of Songkla University, Thailand  
 0000-0002-0640-6824 [Google Scholar](#) [Scopus](#) 21740891300 [-](#)
  - 
**Anucha Thairimontichai**  
**Editorial Board**  
 Department of Pediatrics, Faculty of Medicine, Prince of Songkla University, Thailand  
 0000-0003-2363-6362 [Google Scholar](#) [Scopus](#) 35088990700 [-](#)
  - 
**Surasak Sangkhathat**  
**Editorial Board**  
 Division of Surgery, Faculty of Medicine, Prince of Songkla University, Thailand  
 0000-0003-3622-3233 [Google Scholar](#) [Scopus](#) 6602156542 [-](#)
  - 
**Delvac Oceandy**  
**Editorial Board**  
 Department of Medicine and Health, Faculty of Biology, University of Manchester, United Kingdom  
 0000-0002-6242-6491 [Google Scholar](#) [Scopus](#) 6506557120 [-](#)
  - 
**Brahmaputra Marjadi**  
**Editorial Board**  
 School of Medicine, Western Sydney University, Australia  
 0000-0003-0898-3737 [Google Scholar](#) [Scopus](#) 28267975300 [-](#)
  - 
**Purwo Sri Rejeki**  
**Editorial Board**  
 Department of Physiology and Medical Biochemistry, Faculty of Medicine, Universitas Airlangga, Indonesia  
 0000-0003-2363-6362 [Google Scholar](#) [Scopus](#) 35088990700 [6067303](#)
  - 
**Siti Khaerunnisa**  
**Editorial Board**  
 Department of Physiology and Medical Biochemistry, Faculty of Medicine, Universitas Airlangga, Indonesia; American Association for Biochemistry and Molecular Biology, US  
 0000-0002-6358-8265 [Google Scholar](#) [Scopus](#) 57205438945 [6072589](#)
  - 
**Wihasto Suryaningtyas**  
**Editorial Board**  
 Indonesian Neurosurgical Society; Dr. Soetomo General Academic Hospital, Indonesia  
 0000-0002-1187-3777 [Google Scholar](#) [Scopus](#) 57216140907 [5987008](#)
  - 
**Asra Al Fauzi**  
**Editorial Board**  
 Indonesian Neurosurgical Society; Surabaya Neuroscience Institute (SNet), Indonesia  
 0000-0002-5155-2476 [Google Scholar](#) [Scopus](#) 57215857858 [5984620](#)
  - 
**Azimatul Karimah**  
**Editorial Board**  
 Department of Psychiatry, Faculty of Medicine, Universitas Airlangga; Dr. Soetomo General Academic Hospital, Indonesia  
 0000-0002-0261-7878 [Google Scholar](#) [Scopus](#) 55640202700 [6058132](#)
  - 
**Lucky Prasatiwati**  
**Editorial Board**  
 Department of Anatomy, Histology, and Pharmacology, Faculty of Medicine, Universitas Airlangga; Indonesian Association of Anatomist, Indonesia  
 0000-0002-8929-9816 [Google Scholar](#) [Scopus](#) 57192906307 [5995382](#)
  - 
**Reny Itishom**  
**Editorial Board**  
 Department of Biomedical Sciences, Faculty of Medicine, Universitas Airlangga, Surabaya, Indonesia  
 0000-0002-9971-7786 [Google Scholar](#) [Scopus](#) 57209243810 [5984521](#)
  - 
**Bukola Rukayat Omotoso**  
**Editorial Board**  
 Department of Clinical Anatomy, School of Laboratory Medicine and Medical Sciences, College of Health Sciences, University of KwaZulu-Natal, Westville Campus, Durban 4000, South Africa  
 0000-0002-7989-6959 [Google Scholar](#) [Scopus](#) 57222355742 [-](#)
  - 
**Anggie Kusumawardhani**  
**Assistant Editor**  
 Unit Konsorsium Jurnal dan Folia Medica Indonesiana, Indonesia  
 0000-0002-7908-8589 [Google Scholar](#) [Scopus](#) - [-](#)
  - 
**Athfiyatul Fatati**  
**Assistant Editor**  
 Unit Konsorsium Jurnal dan Folia Medica Indonesiana, Indonesia  
 0000-0002-8065-4922 [Google Scholar](#) [Scopus](#) - [-](#)


### Login

Username \*   
 Password \*   
 Forgot your password? [Link](#)  
 Keep me logged in

---

### Meet Our Editorial Team


**Viskasari P. Kalanjati**  
 Editor-in-Chief  
 Universitas Airlangga, Indonesia  
[Scopus](#) 54388384000




**Muhammad Miftahussurur**  
 Editorial Board  
 Universitas Airlangga, Indonesia  
[Scopus](#) 56323903000

[Read More](#)


### Instruction For Author

### ISSN

### Journal Standing




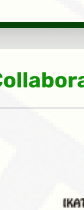

  


### Reference Manager



### Plagiarism Checker

### External Links

### In Collaboration with








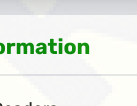




### Accreditation Certificate



### Visitors

### Indexed By


### Information

For Readers  
 For Authors  
 For Librarians

### Keywords



### Current Issue



**Original Research Report****EFFECTS OF *Moringa oleifera* LEAF EXTRACT ON THE LIVER OF EXPERIMENTALLY-INDUCED DIABETIC WISTAR RATS**Wahyu Ikhsan<sup>1</sup> , Suryono Suryono<sup>1,2\*</sup> , Azham Purwandhono<sup>3</sup> <sup>1</sup>Faculty of Medicine, Universitas Jember, Jember, Indonesia<sup>2</sup>Department of Cardiology and Cardiovascular Medicine, Dr. Soebandi Regional Hospital, Jember, Indonesia<sup>3</sup>Department of Anatomical Pathology, Faculty of Medicine, Universitas Jember, Jember, Indonesia**ABSTRACT**

Diabetes mellitus is known as a risk factor for nonalcoholic fatty liver disease (NAFLD) which can progress to nonalcoholic steatohepatitis (NASH) and eventually lead to hepatocellular carcinoma (HCC) through various stages, including necro-inflammatory fibrosis, cirrhosis, and hepatitis. *M. oleifera* leaves contain flavonoid antioxidants, which inhibit reactive oxygen species (ROS) and oxidative stress in diabetes mellitus. This study aimed to investigate the potential of *M. oleifera* leaf extract at a dosage of 1,000 mg/kgbw to inhibit liver tissue fibrosis in diabetic rats. This study used a true experimental method with a post-test-only control group design. This study was conducted at the Faculty of Medicine, Universitas Jember, Jember, Indonesia, from November 2021 to January 2022 on 27 male Wistar rats that were divided into three groups of nine rats. The rats were induced with streptozotocin and *M. oleifera* leaf extract at a dosage of 1,000 mg/kgbw. Masson's trichrome staining and the Meta-analysis of Histological Data in Viral Hepatitis (METAVIR) scoring system were used to measure liver tissue fibrosis. Data were analyzed using the Kruskal-Wallis and Mann-Whitney tests to examine significant differences between groups. The results showed a significant difference in the degree of liver tissue fibrosis between the control and diabetes groups ( $p=0.00$ ) as well as the diabetes and treatment groups ( $p=0.003$ ). However, the results did not show any significant differences between the control and treatment groups ( $p=0.270$ ). These findings suggested that administering *M. oleifera* leaf extract at a dosage of 1,000 mg/kgbw can inhibit liver tissue fibrosis. In conclusion, this study provides evidence that administering *M. oleifera* leaf extract can inhibit liver tissue fibrosis in diabetic rats.

**Keywords:** Diabetes mellitus; *M. oleifera* leaves; liver fibrosis; nonalcoholic fatty liver disease (NAFLD)**\*Correspondence:** Suryono Suryono, Faculty of Medicine, Universitas Jember; Department of Cardiology and Cardiovascular Medicine, Dr. Soebandi Regional Hospital, Jember, Indonesia. Email: suryonofiha@gmail.com**Article history**

● Submitted 13/12/2022 ● Revised 5/4/2023 ● Accepted 22/5/2023 ● Published 10/6/2023

**How to cite:** Ikhsan W, Suryono S, Purwandhono A. (2023). Effects of *Moringa oleifera* Leaf Extract on the Liver of Experimentally-Induced Diabetic Wistar Rats. Folia Medica Indonesiana, 59 (2), 150-155, <https://doi.org/10.20473/fmi.v59i2.37526>

Copyright: © 2023 Folia Medica Indonesiana.

This is an open-access article distributed under the terms of the Creative Commons Attribution License as stated in <https://creativecommons.org/licenses/by-nc-sa/4.0/deed.id>.

pISSN: 2355-8393, eISSN: 2599-056x

**Highlights:**

1. This study examined the antioxidant flavonoid compounds derived from naturally sourced *Moringa oleifera* leaves.
2. *Moringa oleifera* leaf extract was able to prevent tissue fibrosis and liver cirrhosis in diabetic rat models through the nonalcoholic fatty liver disease (NAFLD) pathway.

**INTRODUCTION**

Diabetes Mellitus denotes a hyperglycemic condition due to a lack of insulin, insulin resistance, or both (Hardianto 2021). The World Health Organization (2020) reports that diabetes mellitus is the sixth largest cause of death worldwide. It is reported that approximately 1.3 million people die before reaching age 70 years old due to diabetes mellitus, while its prevalence is around 150 million people worldwide (Nasution et al. 2021). Indonesia is reported to be a country with the sixth-highest

population with diabetes mellitus, with approximately 10.3 million people aged 20 to 79 years old (Minister of Health of the Republic of Indonesia 2018).

Diabetes mellitus is a risk factor for nonalcoholic fatty liver disease (NAFLD), which triggers nonalcoholic steatohepatitis (NASH) through necro-inflammatory fibrosis, and cirrhosis, and eventually results in hepatocellular carcinoma (HCC) (Bellentani 2017). NAFLD prevalence data showed that more than 70% of type 2 diabetes

mellitus patients have NAFLD, and 20% of these NAFLD developed liver fibrosis and ended up becoming HCC (Mitra et al. 2020). This is due to a lack of insulin secretion which can trigger lipolysis in adipose cells and resulting in an increase of the amount of free fatty acids in the blood that go to the liver and muscles (Leite 2014). In diabetes mellitus patients, NAFLD can also activate Kupffer cells in the liver and release hepatic inflammatory mediators (IL-1 $\beta$ , TNF $\alpha$ , IL-6) to indicate the occurrence of inflammation and fibrosis in the liver (Xia et al. 2019).

When diabetes mellitus occurs, the liver will find difficulties to export triglycerides in the form of Very Low-Density Lipoprotein (VLDL). As a result, there will be an accumulation of fat in the liver which encourages fatty liver and inflammation of hepatocytes due to free radicals resulting from the oxidation of fatty acids by mitochondria and lysosomes (Hazlehurst et al. 2016). Diabetes mellitus may cause oxidative stress through the increased production of reactive oxygen species (ROS). The continuous release of ROS might cause an imbalance between prooxidant and antioxidant, stimulating proinflammatory mediators. Increased ROS leads to excessive oxidative stress and eventually results in NAFLD, NASH, fibrosis, and HCC (Safithri 2018). Addressing this condition, external antioxidant compounds like flavonoids, vitamin C, E, and pro-vitamin A are required to balance or inhibit ROS (Tukiran et al. 2020).

Previous study showed that flavonoid content (i.e., quercetin) in *M. oleifera* leaves can potentially serve as hepatoprotectives, hypocholesterolemia, hypolipidemia, and anti atherosclerotics with anti-inflammatory and antioxidant effects (Lin et al. 2018). Flavonoid was also reported to inhibit ROS release, thus reducing the severity of NAFLD in diabetes mellitus (Akhlaghi 2016). The result of this study is expected to provide a reference for further study on the benefits of *M. oleifera* leaves in preventing fibrosis in patients with diabetes mellitus.

## MATERIALS AND METHODS

This study was categorized as a true experimental study with a post-test-only control group design. The experimental unit in this study was male Wistar rats (*Rattus norvegicus*) induced with streptozotocin (STZ) and received a 1,000 mg/kgbw *M. oleifera* leaf extract. The *M. oleifera* leaf extract was obtained from the pharmacology laboratory of Faculty of Medicine, University Jember, Jember, Indonesia, and the leaf extract was made using maceration technique with 96% ethanol solvent. The use of 96% ethanol can produce the highest number

of flavonoids in the leaf extract. The manufacturing process began with 5 kg of leaves washed clean with running water and then dried in an oven at a temperature of 60°C. The leaves, which have been dried, were then smoothed using a blender to obtain 600 grams of fine *M. oleifera* leaves powder. Then, the powder was filtered to obtain the exact smooth level. The subsequently thin powdered leaves were processed in a glass cup with 6,000 mL of 96% ethanol under tightly closed conditions and not exposed to sunlight. A 72-hour maceration was performed, with stirring every 24 hours. The processed leaves were then filtered using Whatman filter paper, and then they were evaporated to obtain thick extract preparation using a water bath at a temperature of 70°C (Nortjie et al. 2022). The extract was then dissolved using sodium carboxymethyl cellulose to obtain extract suspension that would be given to the rats. The liver histopathology preparation was made in the biomedical laboratory of Faculty of Dentistry, University of Jember. The histopathological preparations began with the process of fixation, dehydration, and impregnation, continued with deparaffination, and finally the staining using Masson's trichrome was carried out. The use of Masson's trichrome coloring has become a preferred method for identifying and detecting histopathological morphological changes from fibrosis in patient biopsies and animal models of fibrose (van de Vlekkert et al. 2020). The liver fibrosis reading was performed by a medical specialist in Anatomic Pathology Laboratory of Dr. Soebandi Regional Hospital, Jember, Indonesia. The reading of the preparation was done at one field of view using a light microscope with a 100x magnification. The results of the observations were then viewed and interpreted based on the criteria of the Meta-analysis of Histological Data in Viral Hepatitis (METAVIR) scoring system. This study was conducted for three months, from November 2021 to January 2022.

Wistar rats obtained in this study were divided into three treatment groups, each consisting of nine rats. The rats in the normal control group were given normal saline intraperitoneally followed by per-oral normal saline once per day for four weeks. Meanwhile, those in the diabetic control group were induced by 45 mg/kgbw of STZ, which was dissolved with citrate buffer once via intraperitoneally and followed by per-oral normal saline once per day for four weeks. The treatment group received 45 mg/kgbw intraperitoneal and 1,000 mg/kgbw per-oral once a day for four weeks. After 28 days of treatment, the rats were euthanized using sodium pentobarbital in a dose of 50 mg/kgbw intraperitoneally (American Veterinary Medical Association 2020).

The inclusion criteria for the experimental unit were 2-3 months old male Wistar rats (*Rattus norvegicus*), weighed 200-300 grams and had a fasting blood sugar level of  $\geq 126$ -400 mg/dL three days after being induced by streptozotocin (Gheibi et al. 2017). The drop-out criterion was the dead rats after being induced with STZ during the experiment. Liver fibrosis was assessed using the METAVIR scoring system, as it is believed to be more sensitive to fibrotic activities (Chengxi et al. 2018). The METAVIR scoring system is semi-quantitative in evaluating fibrosis grade (Choo et al. 2022). The fibrosis assessment results were analyzed using IBM SPSS Statistics for Windows, version 25.0 (IBM Corp., Armonk, N.Y., USA). Kruskal-Wallis test with significant results of  $p < 0.05$  was followed up with post-hoc Mann-Whitney test.

**RESULTS**

The blood sugar test of fasting rats was performed on the third day after being induced using STZ and the rats became diabetic (Saputra 2018). The rats were first fasted for six to eight hours before their blood was taken (Furman 2021). The blood of rats in the diabetic control and treatment groups was taken through the lateral veins of the tail using a glucometer. After the STZ-induced developed hyperglycemia with an average fasting blood sugar level of 405 mg/dL, the following normal saline induction produced a normal fasting average blood glucose level of 105 mg/dL as the normal fasting blood glucose is  $< 126$  mg/dL.

Table 1. The METAVIR scoring results.

Groups	No. of samples	Experiments	Liver fibrosis scoring median (IQR)
Normal control	9	Normal	1 (0)
Diabetic control	9	STZ and normal saline	2 (1)
Treatment	9	STZ and 1,000 mg/kgbw of <i>M. oleifera</i> leaf extract	1 (1)

Male Wistar rats in this study were divided into three groups, normal control group, diabetic control group, and treatment group. Liver fibrosis was assessed using the METAVIR scoring system. This system currently serves as the most acceptable system for liver fibrosis and necroinflammation assessment. Staging fibrosis using the METAVIR score to assign a score ranging from F0 (no fibrosis) to F4 (cirrhosis) is the gold standard in liver biopsy

(Chengxi et al. 2018). The METAVIR scoring results of rats' liver fibrosis in normal control group, diabetic control group, and treatment group are presented in Table 1.

Table 1 displays the average result of liver fibrosis using the METAVIR scoring system. The highest liver fibrosis mean score was found in diabetic control group, followed by the treatment group, and the normal control group. The highest average (2.22) was found in the diabetic group, whereas the lowest average (1.11) was found in the normal control group.

Table 2. Kruskal Wallis test result.

	Stages
Kruskal-Wallis H	15.658
Degrees of freedom (df)	2
Asymptotic significance	0.000

Notes:  $p = 0.000$

The Kruskal-Wallis test result, as shown in Table 2, showed a significance value of  $p = 0.000$ , indicating a significant difference among the three groups. The analysis was continued using post-hoc Mann-Whitney test to compare groups showing significant results. The result of post hoc Mann-Whitney test is presented in Figure 1.

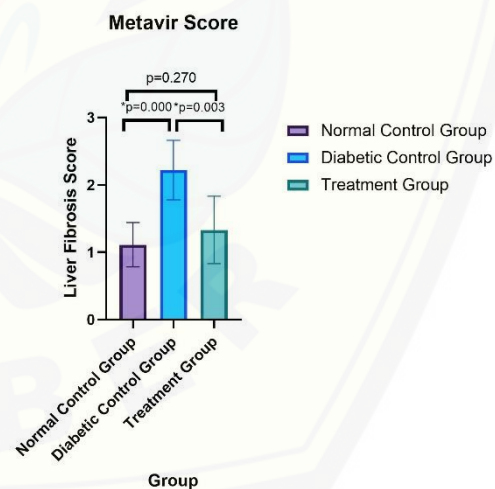


Figure 1. Post-hoc Mann-Whitney test result. \* $p < 0.05$ .

The post-hoc Mann-Whitney test result ( $p < 0.05$ ) indicates a significant difference in rat liver fibrosis assessment among study groups. The normal control group showed a significant fibrosis development compared to the diabetic control group (0.000), but not significant compared to the treatment group

(0.270).

Figure 2 displays the histopathology of rats' liver fibrosis in normal control (A), diabetic control (B), and treatment (C) groups.

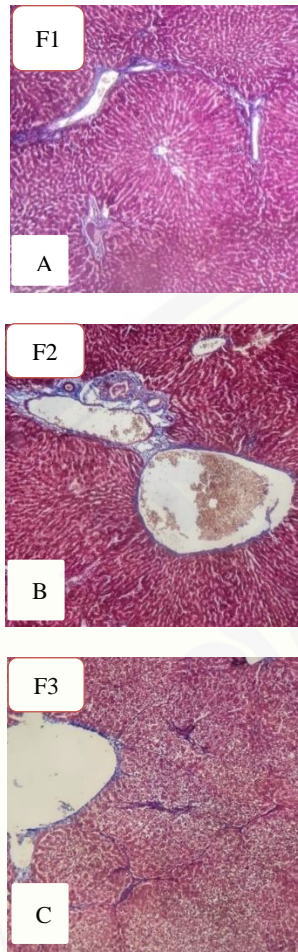


Figure 2. Histopathological liver by Masson's trichrome staining at 100X microscopic magnification of rats' liver fibrosis. (A) Liver fibrosis stage F1 with portal area expansion (normal control); (B) F2 fibrosis with expansion of portal area and marked bridging (treatment group); (C) F3 fibrosis with expansion of portal area and marked bridging, nodules were also noticed (diabetic control).

The result indicates that the administration of 1,000 mg/kgbw *M. oleifera* leaf extract could inhibit liver fibrosis. Figure 2 displays the liver fibrosis observation using the METAVIR scoring system. The normal control group showed a fibrosis expansion in the portal area and collagen deposition, while the diabetic control group showed a fibrosis expansion in the portal area, marked bridging, and a nodule surrounded by collagen deposition. The treatment group exhibited fibrosis with expansion in

the portal area, marked bridging and clearly visible collagen deposition. This group also exhibited better results than the diabetic control group.

## DISCUSSION

The average score of rats in diabetic control group was found to be higher than in normal control group. The observation showed that diabetic rats exhibited stages F2 and F3 of fibrosis. Similar condition was also reported in the study by Aseer et al. (2015), that 14 days after being induced by STZ, the rats showed damaged liver histopathology associated with fibrosis. This fibrosis was caused by the increase in inflammatory mediators such as TNF- $\alpha$ , TGF- $\beta$ 1, and IL-6, which leads to increased ECM and collagen. In another study, liver steatosis and fibrosis began with the increase in free fatty acid due to insulin resistance induced by STZ (Ramadan et al. 2022).

Diabetes mellitus could increase ROS production. The imbalance between production and elimination of ROS can cause oxidative stress that change the structure and functions of protein, nucleic acid, and even damage the DNA (Moreli et al. 2014). Excessive ROS may induce the increased concentration of proinflammatory mediators such as TNF, IL-6, IL-1 $\beta$ , IL-13, TGF- $\beta$ 1, and Galectin-3 (Fulton et al. 2019). Liver fibrosis process is initiated by HSC activation. Various factors like inflammation and cytokine, especially TGF- $\beta$ 1, may prevent HSCs from maintaining balance between ECM production and degradation. An excessive ECM production is known to serve as pathogenesis of organ fibrosis (Heydarpour et al. 2020, Kim et al. 2020).

In this study, rats in normal control group exhibited the lowest liver fibrosis score. In normal group, all rats exhibited stage-1 liver fibrosis, while it should not have occurred. Adeyemi et al. (2014) stated that administering normal saline to rats with normal fasting blood glucose level for four weeks did not result in liver fibrosis, as identified using HE staining method. Another study by Salih et al. (2014) added that rats in control group with normal saline did not exhibit histological or anatomical differences from those induced by STZ for two, four, and six weeks.

Fibrosis in normal control group may be accounted for several reasons. In this study, liver fibrosis histopathology was identified using Masson's trichrome staining, a staining method sensitive to collagen as the fibrosis marker. Thus, when compared to HE staining, fibrosis may be unidentified. Furthermore, seemingly healthy rats possibly have liver disorders. In this regard, Yang et

al. (2019) reported that during rats' embryogenesis process, mesothelial cells (MCs) derived from septum transversum mesenchyme (STM) induce hepatic stellate cells and mesenchymal perivascular cells. Thus, rats in the normal group could potentially experience cell differentiation from hepatic stellate cells and mesenchymal perivascular to myofibroblast that turn into fibrosis over time. Another study from Zhao et al. (2016) added that MCs form hepatic stellate cells and myofibroblasts through epithelial mesenchymal transition (EMT). EMT refers to a process in which epithelial cells lose their polarity and obtain migration capacity during embryogenesis, tissue recovery, organ fibrosis, and tumor metastasis.

### Strength and limitations

This study is the initial and first study that discusses the benefits of *Moringa oleifera* extract against liver fibrosis in model diabetic rats. However, this study cannot be directly implemented in humans, and further studies on the effective dosage in human beings are needed.

### CONCLUSION

The treatment group receiving *M. oleifera* leaf extract did not exhibit significant results compared to the normal control group but showed significant results when compared to the diabetic control group. Thus, it could be concluded that administering *M. oleifera* leaf extract can inhibit liver tissue fibrosis in diabetic rats. Further research can measure malondialdehyde (MDA) as an indicator of oxidative stress, which is the mechanism of hepatic fibrosis occurrence.

### Acknowledgment

The authors would like to thank the staff at Faculty of Medicine and Faculty of Dentistry of Universitas Jember and Dr. Soebandi Regional Hospital, Jember, Indonesia for their kind support.

### Conflict of interest

None.

### Ethical consideration

This experimental study was approved by the Ethics Committee of the Faculty of Medicine of Universitas Jember with a reference number 1559/H25.1.11/KE/2022 on 21/10/2021.

### Funding disclosure

None.

### Author contribution

WI performed the experiments and drafted the manuscript. SS provided idea and expert opinion. AP performed the data analysis.

### REFERENCES

- Adeyemi DO, Ukwenya VO, Obuotor EM, et al (2014). Anti-hepatotoxic activities of *Hibiscus sabdariffa* L. in animal model of streptozotocin diabetes-induced liver damage. *BMC Complementary and Alternative Medicine* 14, 277. doi: 10.1186/1472-6882-14-277.
- Akhlaghi M (2016). Non-alcoholic fatty liver disease: Beneficial effects of flavonoids. *Phytotherapy Research* 30, 1559–1571. doi: 10.1002/ptr.5667
- American Veterinary Medical Association (2020). AVMA guidelines for the euthanasia of animals. AVMA. Available at: <https://www.avma.org/resources-tools/avma-policies/avma-guidelines-euthanasia-animals>
- Aseer KR, Kim SW, Choi M-S, et al (2015). Opposite expression of SPARC between the liver and pancreas in streptozotocin-induced diabetic rats ed. Cheng J-T. *PLoS One* 10, e0131189. doi: 10.1371/journal.pone.0131189
- Bellentani S (2017). The epidemiology of non-alcoholic fatty liver disease. *Liver International* 37, 81–84. doi: 10.1111/liv.13299
- Chengxi L, Rentao L, Wei Z (2018). Progress in non-invasive detection of liver fibrosis. *Cancer Biology Medicine* 15, 124. doi: 10.20892/j.issn.2095-3941.2018.0018
- Choo D, Shin KS, Min JH, et al (2022). Noninvasive assessment of liver fibrosis with ElastPQ in patients with chronic viral hepatitis: Comparison using histopathological findings. *Diagnostics* 12, 706. doi: 10.3390/diagnostics12030706
- Fulton DJR, Li X, Bordan Z, et al (2019). Galectin-3: A harbinger of reactive oxygen species, fibrosis, and inflammation in pulmonary arterial hypertension. *Antioxidant & Redox Signaling* 31, 1053–1069. doi: 10.1089/ars.2019.7753
- Furman BL (2021). Streptozotocin-induced diabetic models in mice and rats. *Current Protocols*. doi: 10.1002/cpz1.78.
- Gheibi S, Kashfi K, Ghasemi A (2017). A practical guide for induction of type-2 diabetes in rat: Incorporating a high-fat diet and streptozotocin. *Biomedicine & Pharmacotherapy* 95, 605–613. doi: 10.1016/j.biopha.2017.08.098
- Hardianto D (2021). Telaah komprehensif diabetes melitus: Klasifikasi, gejala, diagnosis, pencegahan, dan pengobatan. *Jurnal Bioteknologi & Biosains Indonesia* 7, 304–317. doi: 10.29122/jbbi.v7i2.4209
- Hazlehurst JM, Woods C, Marjot T, et al. (2016).



- Non-alcoholic fatty liver disease and diabetes. *Metabolism* 65, 1096–1108. doi: [10.1016/j.metabol.2016.01.001](https://doi.org/10.1016/j.metabol.2016.01.001)
- Heydarpour F, Sajadimajd S, Mirzarazi E, et al (2020). Involvement of TGF- $\beta$  and autophagy pathways in pathogenesis of diabetes: A comprehensive review on biological and pharmacological insights. *Frontiers in Pharmacology*. doi: [10.3389/fphar.2020.498758](https://doi.org/10.3389/fphar.2020.498758).
- Kim J, Kang W, Kang SH, et al (2020). Proline-rich tyrosine kinase 2 mediates transforming growth factor-beta-induced hepatic stellate cell activation and liver fibrosis. *Scientific Reports* 10, 21018. doi: [10.1038/s41598-020-78056-0](https://doi.org/10.1038/s41598-020-78056-0)
- Leite NC (2014). Non-alcoholic fatty liver disease and diabetes: From physiopathological interplay to diagnosis and treatment. *World Journal of Gastroenterology* 20, 8377. doi: [10.3748/wjg.v20.i26.8377](https://doi.org/10.3748/wjg.v20.i26.8377)
- Lin M, Zhang J, Chen X (2018). Bioactive flavonoids in *Moringa oleifera* and their health-promoting properties. *Journal of Function Foods* 47, 469–479. doi: [10.1016/j.jff.2018.06.011](https://doi.org/10.1016/j.jff.2018.06.011)
- Minister of Health of the Republic of Indonesia (2018). Hari Diabetes Sedunia tahun 2018. Minist Heal Repub Indones. Available at: <https://p2ptm.kemkes.go.id/tag/hari-diabetes-sedunia-tahun-2018>.
- Mitra S, De A, Chowdhury A (2020). Epidemiology of non-alcoholic and alcoholic fatty liver diseases. *Translational Gastroenterology Hepatology* 5, 16. doi: [10.21037/tgh.2019.09.08](https://doi.org/10.21037/tgh.2019.09.08)
- Moreli JB, Santos JH, Rocha CR, et al (2014). DNA damage and its cellular response in mother and fetus exposed to hyperglycemic environment. *Biomed Research International* 2014, 1–9. doi: [10.1155/2014/676758](https://doi.org/10.1155/2014/676758)
- Nasution F, Andilala A, Siregar AA (2021). Faktor risiko kejadian diabetes melitus. *Jurnal Ilmu Kesehatan* 9, 94. doi: [10.32831/jik.v9i2.304](https://doi.org/10.32831/jik.v9i2.304)
- Nortjie E, Basitere M, Moyo D, et al (2022). Extraction methods, quantitative and qualitative phytochemical screening of medicinal plants for antimicrobial textiles: A review. *Plants* 11, 2011. doi: [10.3390/plants11152011](https://doi.org/10.3390/plants11152011)
- Ramadan MA, Pramaningtyas MD, Lusiantari R (2022). Derajat fibrosis dan skor nafld pada hepar tikus diabetes mellitus tipe 2 remaja. *Jurnal Kedokteran dan Kesehatan: Publikasi Ilmiah Fakultas Kedokteran Universitas Sriwijaya* 9, 83–90. doi: [10.32539/JKK.V9I1.151315](https://doi.org/10.32539/JKK.V9I1.151315)
- Safithri F (2018). Mekanisme regenerasi hati secara endogen pada fibrosis hati. *MAGNA MEDICA: Berkala Ilmiah Kedokteran dan Kesehatan* 2, 9. doi: [10.26714/magnamed.2.4.2018.9-26](https://doi.org/10.26714/magnamed.2.4.2018.9-26)
- Salih ND, Kumar GH, Noah RM, et al (2014). The effect of streptozotocin induced diabetes mellitus on liver activity in mice. *Global Journal on Advances in Pure & Applied Sciences* 3, 67–75. Available at: [https://www.researchgate.net/publication/324279523\\_The\\_effect\\_of\\_streptozotocin\\_induced\\_diabetes\\_mellitus\\_on\\_liver\\_activity\\_in\\_mice](https://www.researchgate.net/publication/324279523_The_effect_of_streptozotocin_induced_diabetes_mellitus_on_liver_activity_in_mice)
- Saputra AD (2018). Studi tingkat kecelakaan lalu lintas jalan di Indonesia berdasarkan data KNKT (Komite Nasional Keselamatan Transportasi) dari tahun 2007-2016. *Warta Penelitian Perhubungan* 29, 179. doi: [10.25104/warlit.v29i2.557](https://doi.org/10.25104/warlit.v29i2.557)
- Tukiran, Miranti MG, Dianawati I, et al (2020). Aktivitas antioksidan ekstrak daun kelor (*Moringa oleifera* Lam.) dan buah bit (*Beta vulgaris* L.) sebagai bahan tambahan minuman suplemen. *Jurnal Kimia Riset* 5, 113. doi: [10.20473/jkr.v5i2.22518](https://doi.org/10.20473/jkr.v5i2.22518)
- van de Vlekkert D, Machado E, D’Azzo A (2020). Analysis of generalized fibrosis in mouse tissue sections with Masson’s Trichrome staining. *BIO-PROTOCOL*. doi: [10.21769/BioProtoc.3629](https://doi.org/10.21769/BioProtoc.3629)
- World Health Organization (2020). Diabetes. WHO. Available at: <https://www.who.int/news/item/09-12-2020-who-reveals-leading-causes-of-death-and-disability-worldwide-2000-2019>.
- Xia M-F, Bian H, Gao X (2019). NAFLD and diabetes: Two sides of the same coin? rationale for gene-based personalized NAFLD treatment. *Frontiers in Pharmacology*. doi: [10.3389/fphar.2019.00877](https://doi.org/10.3389/fphar.2019.00877)
- Yang L, Li L-C, Lamaoqiezhong, et al (2019). The contributions of mesoderm-derived cells in liver development. *Seminars in Cell & Developmental Biology* 92, 63–76. doi: [10.1016/j.semcdb.2018.09.003](https://doi.org/10.1016/j.semcdb.2018.09.003)
- Zhao Y-L, Zhu R-T, Sun Y-L (2016). Epithelial-mesenchymal transition in liver fibrosis. *Biomedical Reports* 4, 269–274. doi: [10.3892/br.2016.578](https://doi.org/10.3892/br.2016.578)

